





## Assessment of Anatomical Features of Maxillary Sinus Septa in CBCT Images

A. Ahmadian Yazdi (DDS)<sup>1</sup>, S. Mortazavi (DDS, MS)<sup>1</sup>, A. Makhmalbaf (DDS)<sup>2</sup>,  
S. Afshari (DDS)<sup>\*2</sup>

1.Department of Oral and Maxillofacial Radiology, Faculty of Dentistry, Mashhad University of Medical Sciences, Mashhad, I.R.Iran.

2.Student Research Committee, Mashhad University of Medical Sciences, Mashhad, I.R.Iran.

\*Corresponding Author: S. Afshari (DDS)

Address: Student Research Committee, Faculty of Dentistry, Mashhad University of Medical Sciences, Mashhad, I.R.Iran.

Tel: +98 (51) 38829501. E-mail: Sadaf.afshari74@gmail.com

### Article Type

### ABSTRACT

#### Short Communication

**Background and Objective:** Today, implant-based treatments are used as a suitable alternative for toothless areas. Anatomical variations in the maxillary sinus region, including the presence of septa, interfere with implant placement in this area and can increase surgical complications, including perforation of the sinus membrane. This study was aimed at detecting the characteristics of maxillary sinus septa such as prevalence, location and direction in a sample of Mashhad population.

**Methods:** In this cross-sectional study, data were collected from patients of a private oral and maxillofacial radiology center in Mashhad who had referred for CBCT imaging within one year. CBCT images of 150 patients (61 males and 89 females) in the age range of 18 to 77 years were observed in three axial, coronal and sagittal views. Then, the frequency of data was recorded and analyzed based on septa observation, septa location, right and left side, dental status of the area, septa location direction, and maxillary sinus septa status.

**Findings:** In general, 119 (39.76%) septa were observed in 300 sinuses. On the right and left sides, 42.7% and 36.7% of the sinuses had septa, respectively. 42.7% of septa were on the right side and 36.7% were on the left side. There was no statistically significant difference between the two sides in terms of direction. The highest presence of septa was observed in the anterior regions (48.74%), followed by the posterior and middle regions (38.66% and 12.61%, respectively). There was a statistically significant difference in the distribution of septa frequency between regions ( $p < 0.001$ ). The anterior-posterior (sagittal) and mediolateral (transverse) directions were observed in 37 cases (28.46%) and 74 cases (56.92%), respectively. The most common direction of septa was transverse.

**Conclusion:** The findings of the present study showed that maxillary septa may be present in all regions and directions.

**Keywords:** *Septa, Dental Implants, Cone Beam Computed Tomography, Maxillary Sinus.*

Received:

Jan 7<sup>th</sup> 2024

Revised:

Mar 24<sup>th</sup> 2024

Accepted:

May 18<sup>th</sup> 2024

**Cite this article:** Ahmadian Yazdi A, Mortazavi S, Makhmalbaf A, Afshari S. Assessment of Anatomical Features of Maxillary Sinus Septa in CBCT Images. *Journal of Babol University of Medical Sciences*. 2025; 27: e27.

## Introduction

In adults, the maxillary sinus is a cone-shaped cavity in the maxillary bone whose base is at the lateral nasal wall and its apex extends to the maxillary process (1). Variations in its anatomic structure include pneumatization, hypoplasia, antral septa, exostosis, and variations in arterial location (2). Prior to performing any surgical intervention in the posterior maxillary region, it is necessary to have a detailed understanding of the maxillary sinus anatomy and its possible variations (3).

Prior to sinus lift surgery, septa prevalence should be considered since if it is present, the Schneiderian membrane may be perforated or ruptured, or the capability of augmentation steps may be reduced (4). It is preferable to remove the septum before sinus augmentation, as membrane perforation can result in maxillary sinusitis with the septum in place (5). Maxillary sinus septa can be identified using dental panoramic radiography, computed tomography (CT), and cone beam tomography (CBCT) (6). In the last decade, CBCT has been proposed as a technique for maxillofacial imaging. The use of CBCT to observe maxillary septa was first reported in a study by Mozzo et al. (7).

Orthopantomogram (OPG) is a standard diagnostic technique used in oral implantology. However, since it is difficult to distinguish the septa from other anatomical structures, they cannot be definitively excluded or detected in OPG. As a result, 11.8-52.68% of cases may be misdiagnosed compared to computed tomography (CT) (8).

CBCT uses a cone- or pyramidal-shaped beam to acquire multiple projections in one rotation. In contrast, multislice computed tomography (MSCT) uses fan-shaped beams that rotate around the patient to acquire multiple images. CBCT is a suitable technique for 3D imaging of craniofacial structures with a lower dose than CT (8).

Understanding different anatomic and pathologic findings in the sinus is crucial to minimizing the risk of postoperative complications following a maxillary sinus floor lift and other surgeries in this region. It is important to accurately and definitively assess the maxillary sinuses in dentistry as they are significant anatomic structures. Due to the presence of CBCT as a diagnostic imaging modality in dentistry, the recognition of anatomical variations in the maxillary sinuses by CBCT is noteworthy (9).

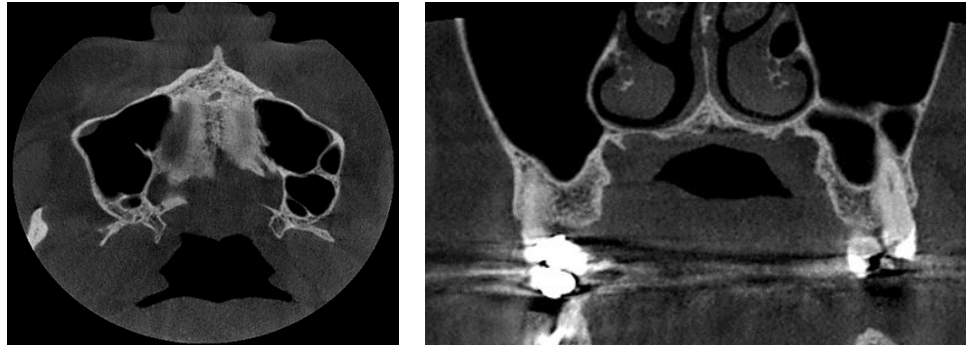There have been studies on the prevalence of maxillary sinus septa, and considering the incompleteness and lack of comparative information on the anatomy of the maxillary sinus in the Iranian population and especially in the population of Khorasan, the present study was conducted to investigate the anatomical features of maxillary sinus septa in a sample of Mashhad population.

## Methods

After approval by the Ethics Committee of Mashhad University of Medical Sciences with the code IR.MUMS.DENTISTRY.REC.1399.108, this cross-sectional study was conducted by examining 150 CBCT images. Patients aged 18 years and older with high-quality images without metal artifacts and with a clear image of the two sinuses were included in the study, and images of patients with maxillofacial syndromes, systemic diseases, facial trauma, and sinus surgery were excluded from the study.

The CBCT scans were taken with MID scanner (Planmeca Promax MID) and were evaluated by a senior dental student under the supervision of an oral and maxillofacial radiologist using Romexis Viewer software R 3.3.0 to analyze the images in three axial, sagittal and coronal views. All bony projections with height that exceeded 2.5 mm above the sinus floor were considered septa and analyzed statistically. Septa were evaluated in three different directions: anterior position: mesial to second premolar, middle position: second premolar to second molar, and posterior position: distal to second molar (5).

Based on the orientation, septa were divided into Anterior Posterior (Sagittal): parallel to the sagittal plane, Mediolateral (Transverse): at a 90-degree angle to the sagittal plane (mediolateral), and Multidirectional: septa with different orientations (10) (Figure 1).



**Figure 1. Multi-directional view in coronal and axial CBCT sections**

The septa were divided into two groups based on their connection to the sinus floor: 1: Floor connection and 2: Not connected to the sinus floor.

All observations were made by a final year dental student under the supervision of a maxillofacial radiologist, and in case of disagreement, a second maxillofacial radiologist was consulted. All statistical analyses were performed using SPSS 12.0.1 and Chi-square and Fisher's exact tests, and  $p < 0.05$  was considered significant.

## Results

Overall, 300 sinuses were examined in this research (178 women and 122 men), and in total 119 septa (39.67%) were recorded. There were 64 septa (42.7%) on the right side and 55 septa (36.7%) on the left side. The distribution of maxillary sinus septa on the right and left sides were not significantly different from each other ( $p = 0.288$ ). 66 septa (37.1%) were observed in the sinus of women and 53 septa (43.4%) were observed in the sinus of men. The distribution of septa in the maxillary sinus of men and women was not significantly different from each other ( $p = 0.268$ ). The most common location of the maxillary sinus was anterior ( $p < 0.001$ ). The most common orientation of the sinus was multidirectional ( $p < 0.001$ ) (Table 1).

**Table 1. Prevalence and distribution of septa position, orientation and connection to sinus floor**

	Number(%)	p-value
<b>Septa Position</b>		
Anterior	58(48.7)	
Middle	15(12.61)	<0.001
Posterior	46(38.6)	
<b>Orientation</b>		
Sagittal	37(28.5)	
Transverse	19(14.6)	<0.001
Multidirection	74(56.9)	
<b>Connection to sinus floor</b>		
Connected	62(52.1)	0.647
Not connected	57(47.9)	

The most common orientation in men and women was multidirectional and transverse with 37.8% and 38.9%, respectively ( $p=0.002$ ) (Table 2).

**Table 2. Prevalence and gender distribution of septa position, orientation and connection to sinus floor septa**

	Women Number(%)	Men Number(%)	p-value
Septa Position			
Anterior	34(51.5)	24(48.5)	0.290
Middle	8(53.4)	7(46.6)	
Posterior	24(52.1)	22(47.9)	
Septa Orientation			
Sagittal	0(0)	12(100)	0.002
Transverse	7(38.9)	11(61.1)	
Multidirection	7(38.9)	11(61.1)	
Connection to sinus floor			
Connected	16(47.1)	18(52.9)	0.053
Not connected	20(71.4)	8(28.6)	

## Discussion

The location of the septa in the present study was 48.74, 12.61 and 38.66% in the anterior, middle and posterior regions, respectively. According to different studies in different populations, septa were most commonly found in the middle region with a prevalence of 49-66% (4, 5, 11, 12). The results of this study were consistent with the findings of Gousau et al (13) and Shahidi et al (9) in Iran, which reported the prevalence of septa in the anterior region at 42.9% and 58.9%, respectively. The difference in the results of the studies in terms of the position and location of the septa can indicate the anatomical variations of the sinus.

The prevalence of sinus septa in present study was 39.67%. Velásquez-Plata et al (14) reported a prevalence of 24% in 357 CBCT images. A study by Malec et al. reported a 49% prevalence of septa in the examined CBCTs (4). Mehdizadeh et al. in 2014 conducted a study on the Iranian population and reported a frequency of 44% septa in the maxillary sinus (15), which is similar to our report (39.67%). The frequency of septa in the present study is in line with the findings of some studies outside of Iran (14-16). In contrast, Van Zyl et al. reported a 69% septa prevalence (12). Other studies indicate a much lower prevalence of septa at the rate of 18.3, 16 and 9% (17-19). Different methods of observation and investigation, different CBCT systems, and racial differences may contribute to this difference in prevalence. However, further research on the effects of race on septa prevalence is needed (15).

Limited studies have examined sinus septa in terms of direction. In the study of Orhan et al. (20), the angle of the septa was measured based on the angle with the midpalatal suture, which was different from the method used in our study. According to the results of this study, 37 maxillary sinus septa (28.46%) were anterior-posterior (Sagittal), 74 septa (56.92%) were mediolateral (Transverse), and 19 septa (14.62%) were multidirectional and a significant difference was obtained in the distribution of septa based on the septal orientation. In the present study, the highest prevalence of septa was in the mediolateral direction (56.92%), which is similar to the results of the study by Malec et al. (4) with a prevalence of (59%), Irinakakis et al. (21) in Canada with a prevalence of (71.1%) and Koymen et al. with a prevalence of (46.4%) (22). Studies by

Talo Yildirim et al (23) and Shahidi et al (9) reported mediolateral septa prevalences of (26.7%) and (35.5%), respectively, which are lower than the present study. Different directions of septa orientation in CBCT images may have an impact on the sinus surgery process and on the success of the surgery (22).

In the present study, (42.7%) of the septa were in right side and (36.7%) of septa were in left side which is consistent with the studies of Velásquez-Plata et al (14), Lee et al (11), Shen et al (24) and the study of Farmarzie et al (5). In general, there is no statistically significant difference in the prevalence of septa between the right and left sinuses in most studies, similar to the present study. But in a few studies, including the study of Orhan et al (20), the prevalence of septa was reported higher on the left side (55%) and in the study of Koymen et al (22), it was reported more on the right side (55.3%).

In the present study, the prevalence of septa in men and women was 43.4% and 37.1%, respectively. Orhan et al (20), Kim et al (25), van Zyl et al (12), Shen et al (24), and Koymen et al (22) found that the prevalence of septa was 50, 32, 44, 34.8, and 55.2% in men, which is relatively consistent with our results. The study by Shibli et al (26) showed a 39% prevalence of septa in women compared to men (35%), indicating a higher presence of septa in women which is in contrast with present study.

Limited study population and the lack of access to the clinical symptoms of the maxillary sinus patients due to the retrospective nature of the study were the limitations of this study.

In this study, 300 maxillary sinuses were examined in terms of anatomical features and frequency of septa, and 119 cases (39.67%) of septa were observed. Sinus septa were observed in toothless as well as atrophic maxillary ridges, but they had different frequencies, locations, orientations, and wall connections, which corresponded with each individual's anatomical variations. The presence of septa in the anterior regions showed a significant difference in the studied population. Based on the data of this study and the possibility of the presence of septa in all areas of the maxilla, with different directions and different wall connections, anatomical evaluation of the sinus before surgery through the CBCT imaging method, which is the most practical imaging technique, is necessary. A detailed examination of the sinus through radiographic images, including CBCT, is recommended before any surgical intervention and especially implant treatments.

**Competing Interests:** All authors confirm that they have no shared interests.

**Ethical considerations:** All parts of this study were conducted in accordance with the ethical standards of Helsinki.

## Acknowledgment

We would like to thank the Vice Chancellor for Research and Technology of Mashhad University of Medical Sciences for supporting the research.

## References

1. Hungerbühler A, Rostetter C, Lübbers HT, Rücker M, Stadlinger B. Anatomical characteristics of maxillary sinus septa visualized by cone beam computed tomography. *Int J Oral Maxillofac Surg.* 2019;48(3):382-7.
2. Leite GM, Lana JP, de Carvalho Machado V, Manzi FR, Souza PE, Horta MC. Anatomic variations and lesions of the mandibular canal detected by cone beam computed tomography. *Surg Radiol Anat.* 2014;36(8):795-804.
3. Toprak ME, Ataç MS. Maxillary sinus septa and anatomical correlation with the dentition type of sinus region: a cone beam computed tomographic study. *Br J Oral Maxillofac Surg.* 2021;59(4):419-24.
4. Malec M, Smektala T, Tutak M, Trybek G, Sporniak-Tutak K. Maxillary Sinus Septa Prevalence and Morphology-Computed Tomography Based Analysis. *Int J Morphol.* 2015;33(1):144-8.
5. Faramarzie M, Babaloo AR, Ghertasi Oskouei S. Prevalence, Height, and Location of Antral Septa in Iranian Patients Undergoing Maxillary Sinus Lift. *J Periodontol Implant Dent.* 2009;1(1):43-7.
6. Henriques I, Caramês J, Francisco H, Caramês G, Hernández-Alfaro F, Marques D. Prevalence of maxillary sinus septa: systematic review and meta-analysis. *Int J Oral Maxillofac Surg.* 2022;51(6):823-31.
7. Mozzo P, Procacci C, Tacconi A, Martini PT, Andreis IA. A new volumetric CT machine for dental imaging based on the cone-beam technique: preliminary results. *Eur Radiol.* 1998;8(9):1558-64.
8. Hegde S, Ajila V, Kamath JS, Babu S, Pillai DS, Nair SM. Importance of cone-beam computed tomography in dentistry: An update. *SRM J Res Dent Sci.* 2018;9:186-90.
9. Shahidi S, Zamiri B, Momeni Danaei S, Salehi S, Hamedani S. Evaluation of Anatomic Variations in Maxillary Sinus with the Aid of Cone Beam Computed Tomography (CBCT) in a Population in South of Iran. *J Dent (Shiraz).* 2016;17(1):7-15.
10. Qian L, Tian XM, Zeng L, Gong Y, Wei B. Analysis of the Morphology of Maxillary Sinus Septa on Reconstructed Cone-Beam Computed Tomography Images. *J Oral Maxillofac Surg.* 2016;74(4):729-37.
11. Lee WJ, Lee SJ, Kim HS. Analysis of location and prevalence of maxillary sinus septa. *J Periodontal Implant Sci.* 2010;40(2):56-60.
12. van Zyl AW, van Heerden WF. A retrospective analysis of maxillary sinus septa on reformatted computerised tomography scans. *Clin Oral Implants Res.* 2009;20(12):1398-401.
13. Gosau M, Rink D, Driemel O, Draenert FG. Maxillary sinus anatomy: a cadaveric study with clinical implications. *Anat Rec (Hoboken).* 2009;292(3):352-4.
14. Velásquez-Plata D, Hovey LR, Peach CC, Alder ME. Maxillary sinus septa: a 3-dimensional computerized tomographic scan analysis. *Int J Oral Maxillofac Implants.* 2002;17(6):854-60.
15. Mehdizadeh M, Torabinia A, Kasaei S, Farhad F. Evaluation of the prevalence of accidental findings in maxillary sinus in the CBCT archives of Isfahan Faculty of Dentistry. *J Isfahan Dent School.* 2015;11(3):223-9. [In Persian]
16. Underwood AS. An Inquiry into the Anatomy and Pathology of the Maxillary Sinus. *J Anat Physiol.* 1910;44(Pt 4):354-69.
17. Sharma D, Sharma N, Sharma V. Sinonasal cancers: diagnosis and management. In: Wang TC, editor. *Challenging Issues on Paranasal Sinuses.* IntechOpen; 2019. p. 45-80.
18. Ulm CW, Solar P, Krennmair G, Matejka M, Watzek G. Incidence and suggested surgical management of septa in sinus-lift procedures. *Int J Oral Maxillofac Implants.* 1995;10(4):462-5.
19. Yang HM, Bae HE, Won SY, Hu KS, Song WC, Paik DJ, et al. The buccofacial wall of maxillary sinus: an anatomical consideration for sinus augmentation. *Clin Implant Dent Relat Res.* 2009;11(Suppl 1):e2-6.



- 20.Orhan K, Kusakci Seker B, Aksoy S, Bayindir H, Berberoğlu A, Seker E. Cone beam CT evaluation of maxillary sinus septa prevalence, height, location and morphology in children and an adult population. *Med Princ Pract.* 2013;22(1):47-53.
- 21.Irinakis T, Dabuleanu V, Aldahlawi S. Complications During Maxillary Sinus Augmentation Associated with Interfering Septa: A New Classification of Septa. *Open Dent J.* 2017;11:140-50.
- 22.Koymen R, Gocmen-Mas N, Karacayli U, Ortakoglu K, Ozen T, Yazici AC. Anatomic evaluation of maxillary sinus septa: surgery and radiology. *Clin Anat.* 2009;22(5):563-70.
- 23.Talo Yildirim T, Güncü GN, Colak M, Nares S, Tözüm TF. Evaluation of maxillary sinus septa: a retrospective clinical study with cone beam computerized tomography (CBCT). *Eur Rev Med Pharmacol Sci.* 2017;21(23):5306-14.
- 24.Shen EC, Fu E, Chiu TJ, Chang V, Chiang CY, Tu HP. Prevalence and location of maxillary sinus septa in the Taiwanese population and relationship to the absence of molars. *Clin Oral Implants Res.* 2012;23(6):741-5.
- 25.Kim MJ, Jung UW, Kim CS, Kim KD, Choi SH, Kim CK, et al. Maxillary sinus septa: prevalence, height, location, and morphology. A reformatted computed tomography scan analysis. *J Periodontol.* 2006;77(5):903-8.
- 26.Shibli JA, Faveri M, Ferrari DS, Melo L, Garcia RV, d'Avila S, et al. Prevalence of maxillary sinus septa in 1024 subjects with edentulous upper jaws: a retrospective study. *J Oral Implantol.* 2007;33(5):293-6.