

A Case Report of Mucopolysaccharidosis Type VI

S.J. Hosseini (MSc)¹, M. Khoshbakht(BSc)², S. Ahmadzadeh (MD)³, M. Firooz (MSc)¹, Z. Sadkharvi (BSc)³,
Z. Mohammadi (MSc)², S. Rahimi (BSc)^{*2}

1.Department of Nursing, Esfarayen Faculty of Medical Sciences, Esfarayen, I.R.Iran

2.Students Research Committee, Esfarayen Faculty of Medical Sciences, Esfarayen, I.R.Iran

3.Imam Khomeini Hospital, Esfarayen Faculty of Medical Sciences, Esfarayen, I.R.Iran

J Babol Univ Med Sci; 20(12); Dec 2018; PP: 76-80

Received: Jul 15th 2018, Revised: Nov 18th 2018, Accepted: Dec 5th 2018.

ABSTRACT

BACKGROUND AND OBJECTIVE: Mucopolysaccharidosis type VI (MPS VI) is a lysosomal storage disorder and autosomal recessive caused by arylsulfatase B deficiency in the body and progressive accumulation of glycosaminoglycan in different organs. Considering that this disease has low prevalence in Iran and worldwide, we report a case of MPS VI diagnosis in this study.

CASE REPORT: A five-year-old boy was referred to Imam Khomeini Clinic in Esfarayen due to impaired growth and dyspnea. In the biography of this boy, there is the history of previous hospitalization due to dyspnea when he was three months, two years and three years old and was treated with antibiotics and salbutamol spray for three days each time. The pediatrician got suspicious of MPS because of the child's peculiar face. Blood tests were performed in terms of the levels of lysosomal enzymes and the urine sample was sent to the Metabolic Laboratory of Hamburg University Medical Center to study the glycosaminoglycan levels. After six months, the results of the tests indicated low levels of serum arylsulfatase B and the increase in chondroitin and urinary levels of dermatan sulfate. To investigate the presence of complications, echocardiography, electromyography, eye and ear examinations as well as radiography for chest, back, hip and hand were performed. Clinical and paraclinical findings confirmed the MPS VI disease and therefore, treatment with naglazyme enzyme was started for the patient.

CONCLUSION: Based on the results of this case report, growth impairment, history of hospitalization due to respiratory problems and the patient's peculiar face are key points for further investigation regarding MPS VI disease.

KEY WORDS: *Mucopolysaccharidosis type VI, Glycosaminoglycan, Arylsulfatase B, Maroteaux-Lamy Syndrome.*

Please cite this article as follows:

Hosseini SJ, Khoshbakht M, Ahmadzadeh S, Firooz M, Sadkharvi Z, Mohammadi Z, Rahimi S. A Case Report of Mucopolysaccharidosis Type VI. J Babol Univ Med Sci. 2018;20(12):76-80.

*Corresponding Author: S. Rahimi (BSc)

Address: Students Research Committee, Esfarayen Faculty of Medical Sciences, Esfarayen, I.R.Iran

Tel: +98 58 37223504

E-mail:rahimi.somayeh.2018@gmail.com

Introduction

Mucopolysaccharidosis (MPS) is a set of rare metabolic diseases that is characterized by defect in lysosomal enzymes involved in the catabolism of glycosaminoglycans (GAGs) (1). Mucopolysaccharidosis has seven types, and its classification is based on the deficiency of the lysosomal enzyme (2). In MPS I (Hurler syndrome), due to abnormalities of the alpha-iduronidase enzyme in the patient's urine, dermatan sulfate and heparan sulfate are excreted. Corneal opacity, upper airway obstruction and cardiomyopathy are among its most important symptoms (3).

In MPS II (Hunter syndrome), there is a deficiency in iduronate 2-sulphate sulphatase enzyme. The disease is associated with chromosome X and is more common among men. The most important symptoms are mental retardation, hearing loss and hepatosplenomegaly (4). In MPS III (Sanfilippo syndrome), which is divided into four types of A to D, there is some degree of mental, behavioral and seizure problems in the affected population (5). In MPS IV (Morquio syndrome), defect in galactosamine-6-sulfatase and β -galactosidase enzymes may affect the development of cartilage and bones, so that looseness and prominence can be observed in the examination of joints (6). MPS VII (Sly syndrome) is associated with some degree of mental retardation due to lack of β -glucuronidase enzyme (7). Moreover, in MPS IX, which is the rarest type of mucopolysaccharidosis, there is a defect in the hyaluronidase enzyme (8).

In MPS VI (Maroteaux–Lamy syndrome), which is a rare autosomal recessive disorder, a malfunction occurs in this lysosomal enzyme due to mutation in arylsulfatase B (ARSB). This enzyme is necessary for the catabolism of GAGs, such as chondroitin sulfate and dermatan sulfate. The incidence of this disease is reported to be 1 per 320000 live births (9). These patients may not reveal a specific problem even during the first year after birth, and growth and development may be normal. Clinical manifestations are typically observed during two to three years of age. However, symptoms may not be observed until adulthood in cases with slow progress. The symptoms of this disease include skeletal dysplasia, lung function impairment, corneal opacity, organomegaly, otitis, hearing impairment, sleep apnea, rugged face, hydrocephalus, hernia and mongolian spots. There is usually no impairment in intelligence function (10). In Iran, several articles described this disease as case reports, and they reported different symptoms. Therefore, there is need

for more information to identify the symptoms of this disease. In addition, several factors such as the rate of disease progression, the beginning of treatment with enzyme or bone marrow transplantation are effective in the prognosis of the disease, and its prerequisite is early diagnosis of the disease. Considering that this disease has low prevalence in Iran and worldwide, we identified and reported a case of MPS VI who was referred to Imam Khomeini Clinic in Esfarayen.

Methods

The patient is a five-year-old boy who was referred to a pediatrician at Imam Khomeini Clinic in Esfarayen by a general practitioner due to suffering from dyspnea and horizontal growth chart over the past year (his weight and height were between the 10th and 25th percentiles at age four, and his weight and height were between the negative 3rd and 3rd percentiles at age five). In the physical examination, the child's appearance was puffy with frontal bump, short neck, large skull, rugged appearance, short nasal bridge, wide nose, gingival hypertrophy, large tongue, swollen eyelids, fingers and toes shorter than normal and there was movement limitation in distal joints due to joint stiffness.

The patient had history of frequent hospitalizations due to dyspnea when he was three months, two years and three years old and was treated with antibiotics and salbutamol spray for three days each time. Salbutamol spray was used during dyspnea at home. Furthermore, the patient is the first child of the family, born via vaginal birth and did not have a particular problem at birth. Birth weight: 3.5 kg, head circumference: 33.5 cm, and height: 51 cm. The maternal age at birth was 24 years old, the parents did not have a history of specific disease and they were not blood relatives. There was no history of behavioral disorders and seizures in the child. The pediatrician got suspicious of MPS because of the child's peculiar face (Fig 1).

For definitive diagnosis of the disease, blood tests in terms of the levels of lysosomal enzymes and the urine samples in terms of glycosaminoglycan levels were sent to the Metabolic Laboratory of Hamburg University Medical Center. After six months, the results of pathology tests via Tandem mass spectrometry (MS/MS) indicated low levels of serum arylsulfatase B (Table 1). In addition, the increase in chondroitin sulfate and dermatan sulfate levels of urine was reported by Berry spot test. In peripheral blood tests, large and

abnormal inclusions were observed in neutrophil cytosol by the pathologist (Fig 2). Paraclinical follow-up was performed to further investigate the complications of the disease. Heart failure, tachycardia, mitral valve prolapse and pulmonary valve failure were observed in patient's echocardiography.



Figure 1. Physical appearance of the child with MPS VI

Table 1. Levels of lysosomal enzymes in the patient's blood

Enzyme	Result	Normal range
β -galactosidase	0.53	0.5–3.2 nmol/spot/h
alpha-L-iduronidase	632	2614–200Pmol/spot/h
iduronate 2-sulphate sulphatase	0.08	0.0–02.25 nmol/spot/h
arylsulfatase B	0.08	0.14–0.7 nmol/spot/h

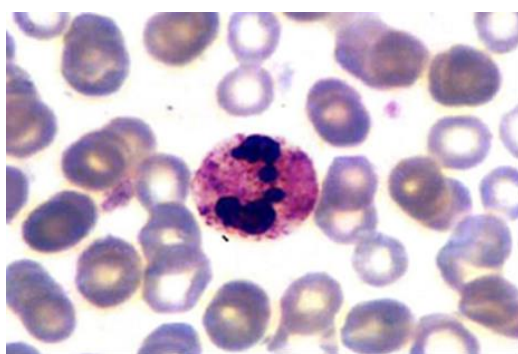


Figure 2. Large and abnormal inclusions in neutrophil cytosol of peripheral blood

According to the radiologist's report, there is hypoplasia of the fifth lumbar vertebra (L5), narrow iliac wings and coxa vara symptoms (in which the femoral neck-shaft angle is increased) in the radiograph of lumbar spine and pelvis. In hand radiographs, the fingers and metacarpus were short and wide. In chest radiograph,

the narrowing of the proximal part of the ribs was evident and the humeral head slipped inferiorly out of the glenoid fossa (Fig 3). In electromyography of upper extremity, abnormal median nerve conduction in both wrists represented carpal tunnel syndrome. The patient was normal in terms of vision, and there was a slight bilateral hearing loss in the examination of the ears.

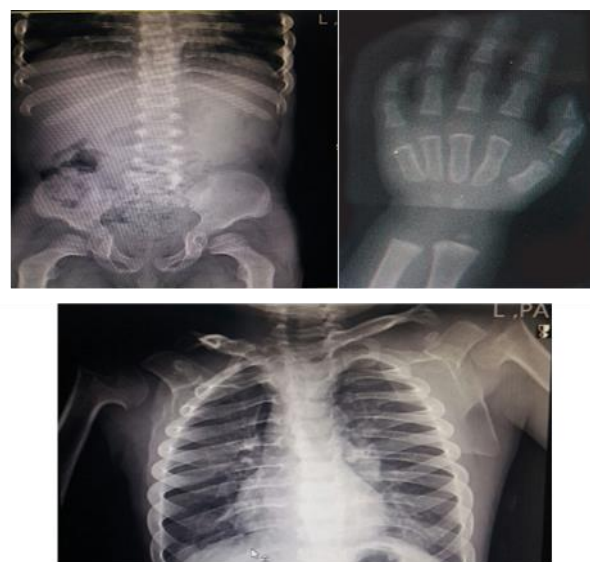

Figure 3. Hand, waist, pelvis and chest radiographs

Discussion

In this case report, considering the rugged appearance, growth failure and respiratory problems, the pediatrician got suspicious of MPS. After performing the tests, definitive diagnosis of MPS VI was confirmed given the low levels of serum arylsulfatase B and the increase in chondroitin sulfate and dermatan sulfate levels in the urine and the patient underwent enzyme therapy with Naglazyme. Another method for identifying these patients is PCR test that analyzes the presence of gene mutations in chromosome 5q13-q14 (11), which was not used in this study.

The age of the onset of MPS VI symptoms may vary in accordance with the severity of the disease (mild to severe). The patient who was examined for MPS in the present study was five years old. Furthermore, in a study on four children with MPS IV in Thailand, the interval between the appearance of the first symptoms and the definitive diagnosis of the disease varied from two to twelve years. This difference in the speed of diagnosis depends on the severity of the disease progression. As with the present study, the first symptom for further examination of the patients in terms of MPS was the face (large tongue, broad nasal bridge, large and rounded cheek, thick lips and rugged appearance) and

the stiffness of the joints in these patients (12). The musculoskeletal system is affected by this disease due to the accumulation of GAGs in the lysosome of the connective tissue cells. The skeletal complications of this disease include short stature, kyphoscoliosis, abnormal joints (stiffness and contraction of elbow, shoulders, hip, knees and fingers), carpal tunnel syndrome, and spinal cord compression. The findings of the present study are consistent with the study of Koohmanaee et al. who reported the presence of kyphosis and brachydactyly (13).

Hyperplasia of L1 vertebra was reported in the study by Hashemi Teir et al., but in the study of Kaissi et al. and in the present study, there is hypoplasia of lumbar vertebra (14, 15), both of which indicate the presence of bone dysplasias among these patients. There is no accurate statistics regarding the prevalence of carpal tunnel syndrome in MPS VI. Carpal tunnel syndrome may be observed in MPS I, IIA, III, and VI, and the differentiation between MPS types is based on the presence of mental retardation and lysosomal enzyme levels (16).

There is no impairment in cognitive function in MPS VI, and the level of ARSB enzyme is low in the blood. The presence of respiratory disorders is an important symptom in patients with MPS VI. Due of frequent respiratory infections, they are prone to otitis media and there are some degrees of hearing loss. There were also mild degrees of bilateral hearing loss in the patient of the present study.

The key point is that most of these patients had history of hospitalization several times due to respiratory problems prior to the definitive diagnosis, which was also reported in several case reports on MPS VI in Iran (13, 15, 17, 18). Regarding the cardiovascular system, the most important finding is valve problems; however, cardiomyopathy, pulmonary hypertension, cardiac conduction system defects and acute cardiac failure may also be observed. In a study by Kampmann et al. among 44 patients with MPS VI, aortic and mitral prolapse were reported in half of the patients. Other findings were tachycardia, pulmonary hypertension and left ventricular hypertrophy, while the presence of mitral prolapse and tachycardia was consistent with the cardiac symptoms in the present study (19). The cause

of the difference in the incidence of other cardiac symptoms may be related to the rapid progression of the disease and the onset of enzyme therapy. The mean age of the diagnosis was 6 and 7 years for the patients of this study, and only 29% of the patients underwent enzyme therapy. In the present study, MPS VI was diagnosed at the age of five and then, enzyme therapy was started for the patient. Corneal opacity is another symptom in these patients. About 94% of MPS VI patients are expected to experience corneal opacity (20).

Eye problems were not observed in the patient of the present study, which is consistent with the results of the study by Koohmanaee et al. However, in the study of Mojtahedzadeh et al., corneal opacity could be observed at the time of diagnosis. The difference may be due to the speed of diagnosis (referral of parents to the physician after the onset of symptoms and the evaluation of the level of lysosomal enzymes), the progression of the disease (slow, moderate or severe), and the onset of the enzyme therapy. In the study of Mojtahedzadeh et al., the age of diagnosis was 11 years and the patient had history of surgical operations due to eye problems and umbilical hernia, both of which can be seen in patients with MPS VI. The age of diagnosis was lower in the present study and the study of Koohmanaee et al. (22 months) (13, 17). Organomegaly is also one of the diagnostic manifestations in MPS VI, which can affect the abdominal viscera, including the liver and the spleen, which was reported to be normal in the present study according to abdominal and pelvic ultrasound, and is consistent with the study of Koohmanaee et al. (13).

Paying attention to the appearance of the patient at the time of referral and the presence of problems such as dyspnea and growth impairment are helpful for clinical suspicion of MPS, and for confirmation of diagnosis, it is necessary to examine the levels of lysosomal enzymes in the blood and the increased levels of GAGs in the urine samples. Examining patients for the presence of complications in various parts of the body, such as musculoskeletal, cardiovascular, and respiratory systems, eyes, ears, and abdominal viscera requires teamwork. Enzyme therapy also contributes significantly to reducing the complications of this disease.

References

1. Javed A, Aslam T, Jones SA, Ashworth J. Objective quantification of changes in corneal clouding over time in patients with mucopolysaccharidosis. *Invest Ophthalmol Vis Sci.* 2017;58(2):954-8.
2. Khan SA, Peracha H, Ballhausen D, Wiesbauer A, Rohrbach M, Gautschi M, et al. Epidemiology of mucopolysaccharidoses. *Mol Genet Metab.* 2017;121(3):227-40.
3. Parini R, Deodato F, Di Rocco M, Lanino E, Locatelli F, Messina C, et al. Open issues in Mucopolysaccharidosis type I-Hurler. *Orphan J Rare Dis.* 2017;12:1-9.
4. Needham M, Packman W, Quinn N, Rappoport M, Aoki C, Bostrom A, et al. Health-related quality of life in patients with MPS II. *J Genet Couns.* 2015;24(4):635-44.
5. Jakobkiewicz-Banecka J, Gabig-Ciminska M, Kloska A, Malinowska M, Piotrowska E, Banecka-Majkutewicz Z, et al. Glycosaminoglycans and mucopolysaccharidosis type III. *Front Biosci(Landmark Ed).* 2016;21:1393-409.
6. Khan S, Almeciga-Diaz CJ, Sawamoto K, Mackenzie WG, Theroux MC, Pizarro C, et al. Mucopolysaccharidosis IVA and glycosaminoglycans. *Mol Genet Metab.* 2017;120(1-2):78-95.
7. Bayo-Puxan N, Terrasso AP, Creysse S, Simao D, Begon-Pescia C, Lavigne M, et al. Lysosomal and network alterations in human mucopolysaccharidosis type VII iPSC-derived neurons. *Sci Rep.* 2018;8(1):16644.
8. Kiykim E, Barut K, Cansever MS, Zybek CA, Zubarioglu T, Aydin A, et al. Screening mucopolysaccharidosis type IX in patients with juvenile idiopathic arthritis. *JIMD Rep.* 2016;25:21-4.
9. Abbasi S, Noruzinia M, Bashti O, Ahmadvand M, Salehi Chaleshtori AR, Mahootipou L. Another novel missense mutation in ARSB gene in Iran. *Acta Med Iran.* 2017;55(9):585-90.
10. Gokdogan C, Altinyay S, Gokdogan O, Tutar H, Gunduz B, Okur I, et al. Audiologic evaluations of children with mucopolysaccharidosis. *Braz J Otorhinolaryngol.* 2016;82(3):281-4.
11. Harmatz P, Shediak R. Mucopolysaccharidosis VI: pathophysiology, diagnosis and treatment. *Front Biosci (Landmark Ed).* 2017;22:385-406.
12. Ittiwut C, Boonbuamas S, Srichomthong C, Ittiwut R, Suphapeetiporn K, Shotelersuk V. Novel mutations, including a large deletion in the ARSB gene, causing mucopolysaccharidosis type VI. *Genet Test Mol Biomarkers.* 2017;21(1):58-62.
13. Koohmanaee S, Taghavi Z. Mucopolysaccharidosis VI, A Case Study. *J Guilan Univ Med Sci.* 2014;23(89):83-9. [In Persian]
14. Kaissi AA, Hofstaetter J, Weigel G, Grill F, Ganger R, Kircher SG. The constellation of skeletal deformities in a family with mixed types of mucopolysaccharidoses: Case report. *Medicine (Baltimore).* 2016;95(32):e4561.
15. Hashemi Teir A, Talebi R. Hashemi-Tayer A, Talebi R. Mucopolysaccharidoses (Maroteaux-Lamy): A case report. *J Arak Uni Med Sci.* 2012;15(2):120-5. [In Persian]
16. Scarpa M, Buffone E, Marca PL, Campello M, Rampazzo A. Difficulties in diagnosing slowly progressive mucopolysaccharidosis VI: A case series. *J Pediatr Rehabil Med.* 2010;3(1):71-5.
17. Mojtahedzadeh F, Rashidi ghader F, Alaee A, Tale A. Mucopoly saccharidosis type maroteaux-lamy, a case report. *J Mazandaran Univ Med Sci.* 2006;16(56):136-42. [In Persian]
18. Bianchi PM, Gaini R, Vitale S. ENT and mucopolysaccharidoses. *Ital J Pediatr.* 2018;44(Suppl 2):127.
19. Kampmann C, Lampe C, Whybra-Trumpler C, Wiethoff CM, Mengel E, Arash L, et al. Mucopolysaccharidosis VI: cardiac involvement and the impact of enzyme replacement therapy. *J Inherit Metab Dis.* 2014;37(2):269-76.
20. Ganesh A, Bruwer Z, Al-Thihli K. An update on ocular involvement in mucopolysaccharidoses. *Curr Opin Ophthalmol.* 2013;24(5):379-88.