

Effect of Visceral Fat on the Amount of Hydroxyproline and Histopathological Changes on Surgical Wound Healing in Male Rat

K. Didevar¹, G. Javdan (PhD)², S.H. Davoodi (PhD)^{*3}

1. Department of Biochemistry, Alborz University of Medical Sciences, Karaj, I.R.Iran

2. Minimally Invasive Surgery Research Center, Iran University of Medical Sciences, Tehran, I.R.Iran

3. Cancer Research Center, National Nutrition and Food Technology Research Institute, Shahid Beheshti University of Medical Sciences, Tehran, I.R.Iran

J Babol Univ Med Sci; 21; 2019; PP: 349-56

Received: May 4th 2019, Revised: Aug 6th 2019, Accepted: Aug 13th 2019.

ABSTRACT

BACKGROUND AND OBJECTIVE: expensive treatments and rehabilitation has increased the tendency to use natural and cheaper compounds. Animal visceral lipids contain a high percentage of different types of effective anti-inflammatory fatty acids, which till now have not been studied together. Therefore, the purpose of this study was to evaluate the anti-inflammatory and regenerative effects of sheep visceral lipids on surgical wound healing in rat rats.

METHODS: In this experimental study 50 Sprague-Dawley adult male rats with the average weight of 250-300 g were selected and randomly divided into 2 groups with 25 rats in each group. After providing visceral fat from the pre renal part of the young sheep and melting and sterilizing them, the treatment group which were wounded under surgical anesthesia by excisional wounds, were treated by 10 ml of it on the wound each day. The evaluation of the wound size was measured by using an accurate caliper and Image J software on days 5, 10, 12, 15. Tissue biopsies from both control and treatment groups were performed to compare the rate of epithelialization, collagen filament formation, inflammatory cells, vascularization, and fibroplasia in situ. Also a biopsy was performed at day 21th to check the amount of hydroxyproline in the tissue.

FINDINGS: Based on morphometric findings, on the 10th day of treatment, the mean ulcer size of the treatment group with visceral fat was 43.6 ± 0.44 mm² while the mean size of the ulcer in control group was 98.5 ± 0.07 mm², which has shown to have the least amount of wound contraction. Also on the 5th day, the wound contraction of the treatment group, was twice as high as the control group ($p < 0.05$). The histological examination shows the mean 2.74 ± 0.17 points of restoration parameters score in treatment group compared to the control group with a score of 1.42 ± 0.16 points. Also, the difference between the Hydroxyproline concentration of the healthy skin and the scarring wounds in treatment group (3.69 ± 0.23 mg/g) was less than the control group (6.08 ± 0.32 mg/g) ($p < 0.05$).

CONCLUSION: According to the findings of this study, the usage of animal visceral lipid, with anti-inflammatory effects and as a stimulator of collagen production, increases the amount of hydroxyproline and affects the healing process of cutaneous ulcers. It also improves the blood perfusion and angiogenesis by increasing RBC membrane flexibility, which will also enhance the migration of cells that are effective in wound healing.

KEY WORDS: Wound, Visceral Fat, Rat, Fatty Acid, Hydroxyprolin.

Please cite this article as follows:

Didevar K, Javdan G, Davoodi SH. Effect of visceral fat on the amount of Hydroxyproline and Histopathological changes on surgical wound healing in male rat. J Babol Univ Med Sci. 2019;21: 349-56.

*Corresponding Author: H. Davoodi (PhD)

Address: National Nutrition and Food Technology Research Institute, Shahid Beheshti University of Medical Sciences, Tehran, I.R.Iran

Tel: +98 21 23871

E-mail: hdavoodi1345@gmail.com

Introduction

The prevalence of chronic ulcers in the community was reported to be 4.5 in 1000 and acute ulcers nearly doubled in 1000 reported 10.5 (1). The treatment of wounds and burns is still one of the major problems in developed countries. Identifying inexpensive and effective drugs (including adipose tissue) that have less side effects on wound healing is now one of the research goals (2,3). In traditional medicine, animal oils have also been used to heal wounds, and various plant extracts have been used to treat skin diseases that have effective compounds in common with animal oils (4). In vitro studies in rat tissue also show that adipose tissue stimulates skin growth (5).

The wound healing process consists of four distinct stages of coagulation, inflammation, proliferation, and regeneration (6-8). In addition to adipocytes, adipose tissue contains fibroblasts and vascular endothelial cells and various types of immune cells such as macrophages (ATMS) (9, 10). Adipose tissue also as an endocrine gland produce hormones such as leptin and estrogen and cytokines, growth factors, prostaglandins, angiotensin II, tumor necrosis factor alpha, interleukin and vascular endothelial growth factor (VEGF) (11) and insulin like growth factor I (12) and Macrophage stimulator factor (MCSF) which are effective in tissue repair process (13). Subcutaneous fat is located between the dermis and fascia layer, and visceral fat is located in the abdominal cavity and around the organs of the body, which are generally semi-solid (14,15).

Linoleic acid participates in the production of metalloproteinase, removes tissue from the wound bed and induces the granulation process as an immunogen and protects the skin against chemical and enzymatic factors. The visceral lipid extract also contains a significant percentage of several omega-3 fatty acids simultaneously (13, 15). The enrichment of erythrocyte membranes with omega-3 fatty acids increases the red blood cell's flexibility and increases the blood supply and availability of nutrients needed for repair (16). To explain the mechanism of these results, one hypothesis is that these fatty acids prevent arachidonic acid from penetrating into the membrane phospholipid and substitute for the acid itself, resulting in a decrease in the substrate required for the production of prostaglandins and leukotrienes (17).

In addition, fatty acids are metabolized by oxygenase enzymes and produce products such as prostaglandin E2 and thromboxane A3 that are less potent than arachidonic acid-derived products and reduce their activity through competition (14). In

addition, it creates a moisture layer on the wound while maintaining adequate moisture, preventing excess moisture and ambient moisture from interfering with the natural process (18, 19).

The presence of vitamins A and D in animal oil is not also ineffective on the production of collagen (20). Researchers have reported that the abundance of essential fatty acids in animal oil is another possible cause of its impact on wound healing (19), most notably linoleic acid and linolenic acid, which are essential fatty acids in mammals (14, 17).

The fatty acids found in sheep visceral lipids are: palmitic acid 26%; stearic acid 14%; myristic acid 3%; oleic acid 47%; palmitic acid 3%; linoleic acid 3% and linolenic acid 1%. Linoleic acid acts as a chemotactic agent for macrophages and regulates collagenase synthesis (2) and is effective in protein synthesis, nucleic acids, cell membranes and cell division (21). Also localized blood flow is one of the most important factors in wound healing due to ischemia-reperfusion processes (22-24). The ischemia-reperfusion process has a direct effect on the process by changing the amount of ROS present at the site of injury. Hydroxyproline is one of the most important indices for measuring collagen synthesis, so it was used to measure the rate of collagen repair in wound healing (17). Structural and functional comparisons of visceral and subcutaneous fat have shown that the visceral adipose tissue (VAT) has more vessel, nerves and immune and inflammatory cells than the subcutaneous adipose tissue (SCAT) (25). VAT also has more capacity to produce free fatty acid (9).

So far no study has been performed on the effect of visceral adipose tissue on surgical wound healing in male rats. In this study, morphological and histological changes as well as hydroxyproline in wound healing by using sheep visceral adipose tissue in animal model were investigated.

Methods

Animal Preparation and maintaining: In this experimental study, after approval by the Ethics Committee of Alborz University of Medical Sciences with code Abzums.Rec. 1396.36, 50 male Sprague rats weighing 200-300 g and mean age of 12 weeks were selected and purchased from Royan Research Institute, Tehran. Rats were fed with pellet and healthy water and housed in separate shelves. The study was conducted in a room with controlled conditions (temperature 24° C

and relative humidity 70%) under natural light. Xylazine (10 mg/kg) and ketamine (60 mg/kg) and hydrochloric acid and hydrated chloramine T 96% and ehrlich reagent (2.5 g of p-dimethylaminobenzaldehyde, 2.7 ml of 12 N HCl, 16 ml of isopropanol) was purchased from Sigma Company (Sigma Aldrich, Steinheim, Germany).

Ointment preparation: Visceral lipid around the young lamb kidneys were obtained from Tehran slaughterhouse and after being thoroughly washed with normal saline and partitioned, sterilized for 40 min with UV lamp and It was gradually melted at 60° C before being applied, and then applied after the relative temperature had decreased.

How to create trauma: After induction of anesthesia in rats with 2% xylazine and 10% ketamine, their dorsal surface of the scapular was prepared and their hair were shortened. Then, a full-thickness circular wound with a diameter of 0.5 cm was made using a sterile biopsy punch. Epidermal, dermis and hypodermic layers and Panniculus Carnosus were completely removed by excisional wounding.

After trauma, they were divided into two groups of treated and control. The first group was treated with melted lipid 10 cc daily for 21 consecutive days and the control group received no drug. Rats of both groups were randomly selected on days 5, 10,12, 15 and 21. Wound measurements and morphological examination as well as wound tissue sampling were performed under ether anesthesia and then the rats were removed.

Morphometric and histopathological data collection and analysis: The wounds were cleaned daily with a sterile tampon impregnated with physiological saline daily prior to drug administration. Then, by placing a

marker adjacent to the edges of the wound without strain or tensile on the skin adjacent to the caliper by measuring the diameter of the wound, digital imaging was used to evaluate the morphometric process of the wound healing process, then according to the mean data, the following percent formula was used to calculate the percentage of wound healing:

Percentage of wound healing: (area of wound on 1st day - area of wound on day x)/area of wound on 1st day × 100

Histopathological studies: Histopathological specimens were prepared from total wound thickness on days 5, 10, 12 and 15 of by puncture biopsy at 2 cm diameter. Slides were examined using trichrome staining and Hematoxylinand Eosin (H&E) for wound healing factors (Table 1).

Tissue Hydroxyproline Measurement: The amount of hydroxyproline in tissue samples was measured by method of Summa et al., as modified by the researchers and measured by digital imaging and histology (1). In this method, tissue samples were first hydrolyzed using 5 M hydrochloric acid and incubated at 105 ° C for 16 hours.

Then, by adding chloramine T solution, hydroxyproline was oxidized. By adding the Ehrlich reagent to the resulting product, the colored compound was created and after extraction of toluene in two steps, its optical absorption rate at 550 nm was read by spectrophotometer.

Statistical analysis of the results: Data were analyzed using SPSS software and one-way ANOVA and Tukey tests were used to compare the results between the groups. P<0.05 was considered as significant.

Table 1. Scoring of histopathological variables

Score	Epithelization	Inflammation	angiogenesis	Amount of collagen deposition	Collagen pattern	Fibroplasia
0	No change	No change	No change	No change	Completely irregular	No change
1	One-thirds lower level	Mild	Mild	Mild	Mild	Mild
2	Two-thirds lower level	Moderate	Moderate	Moderate	Moderate	Moderate
3	Total	Severe	Severe	Severe	Severe	Severe

Results

Morphometric findings: On the fifth day of wound healing in both groups, there was a significant decrease in wound size in visceral fat treated group compared to day zero. According to the average area of wounds on fifth day, the highest wound contraction was observed in the visceral fat treated groups (17.42±0.073 mm²) compared to the control group (23.02±0.34 mm²) (Fig 1).

On the 10th day of the treatment period, the visceral fat treated group had the highest average of wound contraction (43.6±0.44 mm²) and the control group had the lowest mean wound contraction (98±5.08 mm 1.2 mm²) (Fig 2). Finally, morphometric data between groups were statistically significant on all studied days other than days 12 and 15 (p<0.5).

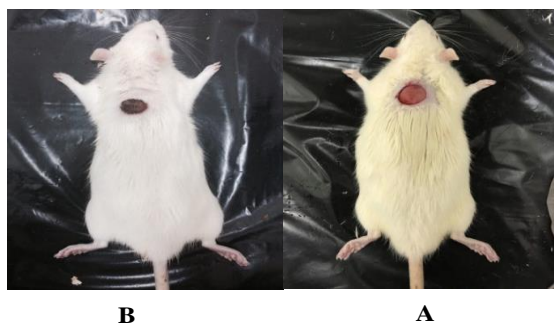


Figure 1. Comparison of wound healing on day 5; A) control group, B) treatment group

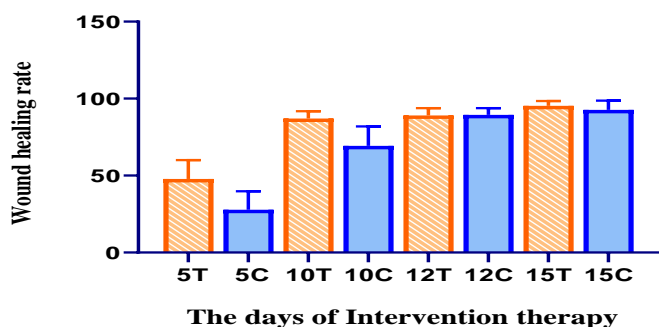


Figure 2. Comparison of wound healing rate in different groups. Day 5, control group: 5C; Day 5, treatment group: 5T ($p < 0.05$). Day 10, control group: 10C; Day 10, treatment group: 10 T ($p < 0.05$).

Histopathologic findings: On the fifth day of treatment, the epithelial growth in treated group started from the edge of the wound and the wound covered with pustule and the number of inflammatory cells has been reduced compared to the control group. In the

connective tissue of the hypoderm, infiltration of fibroblasts and inflammatory cells, especially neutrophils with fibrin deposition was visible within the loose connective tissue. In the control group, more severe inflammatory cell infiltration was present in the fibrin bed at the wound site, edema and hyperemia were observed and epithelial tissue growth began. At day 3 of treatment, basal cell migration from the wound edges continued. In the treatment group, the granular tissue occupied the wound and this section was identified as the best day slide (Fig 3 A).

In the control group, unlike the treatment group, there was no loose connective tissue and the Multi-cellular granular texture and vasculature occupied less part of the wound. The treatment group had better organized healing tissue on day 15 and the thick epithelium covered the entire surface of the wound. The collagen filaments were thicker and more organized, and the overall parameters had a mean score of 2.85 ± 0.33 . However, there were no significant differences in the histopathologic features and tissue maturation at day 12 and 15 between treatment and control groups (Table 2).

Hydroxyproline changes in wound tissue: The difference between the hydroxyproline content of healthy skin and wound scar in the treatment group (3.69 ± 0.23) was significantly lower than in the control group (6.8 ± 0.32) (Table 3). This difference showed that treatment with visceral lipid significantly increased the amount of hydroxyproline in the healing tissue compared to the control wounds. ($p < 0.05$).

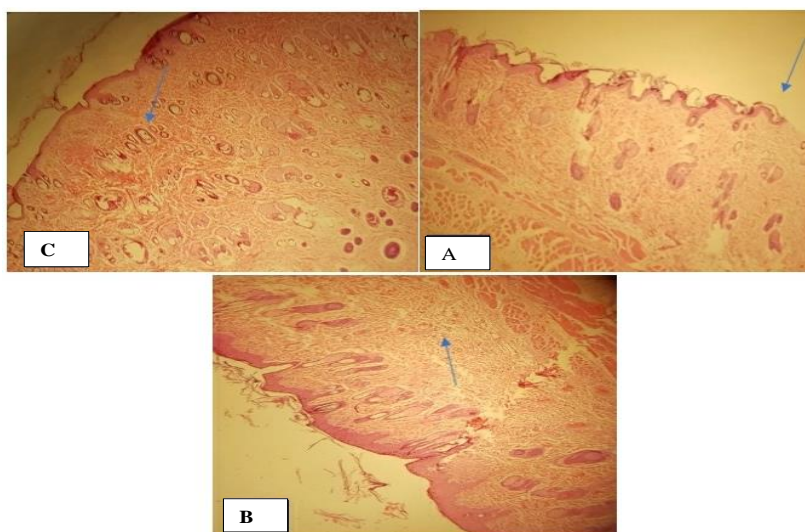


Figure 3. Histological study on slides (H&E staining) of treatment group on days 10, 5, and 15 (a) arrow shows angiogenic sites (b) shows the site of uptake and proliferation of the lining of the wound side (c) a number of cutaneous attachments such as hair follicles and sebaceous glands in granulation tissue center and collagen filament arrangement

Table 2. Mean score of histopathological variables for each group and different doses evaluated

Group	Period	5 th day	10 th day	12 th day	15 th day
		Mean±SD	Mean±SD	Mean±SD	Mean±SD
Treatment		1.89±0.05	2.74±0.17	2.83±0.04	2.85±0.33
Control		1.08±0.1	1.42±0.16	2.21±0.2	2.57±0.02
P-value		0.032	0.019	0.069	0.076

Table 3. Hydroxyproline values in skin tissue samples (mg/g)

Group	Healthy skin(mg/g)	Wound scar(mg/g)	Difference between healthy skin and final scar (mg/g)*
	Mean±SD	Mean±SD	Mean±SD
Treatment	8.37±0.85	5.87±0.62	3.69±0.23
Control	9.45±0.92	4.23±0.67	6.08±0.32

Discussion

According to the results of this study, topical application of animal visceral lipid extract on full thickness wound of rats significantly accelerates wound healing and reduces inflammatory phase interval and enhances angiogenesis and collagenization quality and also increases amount of hydroxyproline proliferated in the wound scar tissue. The most significant morphological changes occurred in the first 10 days of wound healing, so that the wound surface area of the control group was twice that of the treatment group on the tenth day. Histological analysis showed that collagen deposition, epidermal regeneration and proliferation (fibroblasts and endothelial cells) were higher in the treated group than in the control group. The present study also showed that the amount of hydroxyproline in the skin, which is a specific measure of collagen production, was significantly increased in scar treated with lipid extract. Previous studies have shown that inflammatory responses need to be resolved in the process of successful wound healing after tissue injury. But if this stage continues, the wound may enter the chronic stage and may leave the wound scar after healing (3-5). In a study by Mohiuddin et al., It was found that the use of subcutaneous adipose tissue extract increased macrophage and reduced neutrophils in the late phase of inflammatory phase (25).

Based on evidence from biochemical studies by Kim and colleagues comparing the structural and functional visceral and subcutaneous fat and greater capacity of visceral fat to produce free fatty acid (1), seems to be

more effective than previous subcutaneous fat use in this study. The histological results of the present study also showed a decrease in inflammatory cells such as neutrophils in the acute inflammation phase. Confirming these results, a study by Hu et al., found that topical consumption of oil from adipose tissue reduces inflammation due to its omega-3 fatty acid richness (1). One of the studies in this area is the positive effect of fat tissue extract on accelerating migration of wound healing cells by López et al. Topical consumption of short-chain fatty acids can eliminate the deficiency of essential fatty acids and cause normal skin profiling and non-formation of hypertrophic scars (1).

Therefore, the increase in hydroxyproline clearly explains the accelerated wound closure due to the faster accumulation of collagen. In this study, in treatment group, the collagenization with more regular and evolved arrangement was performed in less time. Histopathological evidence in visceral lipid-healing tissue suggests that angiogenesis (angiogenesis) persists. The study by Casano and his colleagues also confirmed the positive effect of subcutaneous adipose tissue extract on wound healing and vascular endothelial cell regeneration (1).

Overall, the results of this study are in line with the results of similar studies in the field. According to the results of this study, animal visceral lipid can accelerate the wound healing process with anti-inflammatory effects on the skin. Animal oils were used as a base for making topical compounds for the treatment of skin wounds. The different effects of visceral lipid on sheep

are due to its various constituents. To introduce the mechanism of action of these compounds, further studies on the evaluation of the effects of each fatty acid separately as a positive control and to compare them with each other seems necessary.

Acknowledgment

Hereby, we would like to thank the financial support of the Student Research Committee of Iran University of Medical Sciences and the Vice-Chancellor of Research of Alborz University of Medical Sciences.

References

1. Tan QW, Tang SL, Zhang Y, Yang JQ, Wang ZL, Xie HQ, Lv Q. Hydrogel from Acellular Porcine Adipose Tissue Accelerates Wound Healing by Inducing Intradermal Adipocyte Regeneration. *J Invest Dermatol*. 2019;139(2):455-63
2. Tejada S, Manayi A, Daglia M, Nabavi SF, Sureda A, Hajheydari Z, et al. Wound Healing Effects of Curcumin: A Short Review. *Curr Pharm Biotechnol*. 2016;17(11):1002-7.
3. Gawronska-Kozak B, Bukowska J, Wu X, Strong AL, Frazier T, Bunnell BA, et al. Contribution of Adipose-Derived Cells to Skin Wound Healing. [Chapter 7], In: *Wound Healing: Stem Cells Repair and Restorations, Basic and Clinical Aspects*. John Wiley & Sons, Inc.; 2018. p.89-101.
4. Boniakowski A, Kimball A, Davis F, Joshi A, Schaller M, denDekker A, Kunkel S, Gallagher K. Fatty acid binding protein 4, fabp4, causes impaired wound healing in diabetes. *Arterioscler Thromb Vasc Bio*. 2018;38(Suppl_1):255.
5. Silva JR, Burger B, Kühl C, Candreva T, dos Anjos MB, Rodrigues HG. Wound Healing and Omega-6 Fatty Acids: From Inflammation to Repair. *Mediators Inflamm*. 2018;2018:2503950.
6. Ehrampoush E, Homayounfar R, Davoodi SH, Zand H, Askari A, Kouhpayeh SA. Ability of dairy fat in inducing metabolic syndrome in rats. *Springerplus* 2016;5(1):2020.
7. Amani H, Ajami M, Nasser Maleki S, Pazoki-Toroudi H, Daglia M, Tsetegho Sokeng AJ, et al. Targeting signal transducers and activators of transcription (STAT) in human cancer by dietary polyphenolic antioxidants. *Biochimie*. 2017;142:63-79.
8. Lawrence WT. Physiology of the acute wound. *Clin Plast Surg*. 1998;25(3):321-40.
9. Mohiuddin OA, Campbell B, Poche JN, Thomas-Porch C, Hayes DA, Bunnell BA, Gimble JM. Decellularized Adipose Tissue: Biochemical Composition, in vivo Analysis and Potential Clinical Applications. *Adv Exp Med Biol*. 2019.
10. Kim S, Moustaid-Moussa N. Secretory, endocrine and autocrine/paracrine function of the adipocyte. *J Nutr* 2000;130(12):3110S-5S.
11. Javedan G, Shidfar F, Davoodi SH, Ajami M, Gorjipour F, Sureda A et al. Conjugated linoleic acid rat pretreatment reduces renal damage in ischemia/reperfusion injury: Unraveling antiapoptotic mechanisms and regulation of phosphorylated mammalian target of rapamycin. *Mol Nutr Food Res*. 2016;60(12):2665-77.
12. Hu L, Wang J, Zhou X, Xiong Z, Zhao J, Yu R, Huang F, Zhang H, Chen L. Exosomes derived from human adipose mesenchymal stem cells accelerates cutaneous wound healing via optimizing the characteristics of fibroblasts. *Scient Rep*. 2016;6:32993.
13. Dehghan G, Tahmasebpour N, Hosseinpour Feizi M, Banan S, Sheikhzadeh F, Monirinasab H. Effects of methanol extract of *teucrium orientale* on the serum levels of glucose and lipids in diabetic rats. *J Babol Univ Med Sci*. 2014; 16(1):44-9. [In Persian]
14. Sheidaei S, Jafarnejad F, Rajabi O, Najafzadeh M. Comparison of vaginal cream of coconut oil and clotrimazole on candidal infection of vagina. *J Babol Univ Med Sci*. 2019; 21 (1) :93-8. [In Persian]
15. Davoodi SH, Shahbazi R, Esmaili S, Sohrabvandi S, Mortazavian A, Jazayeri S, et al. Health-Related Aspects of Milk Proteins. *Iran J Pharm Res*. 2016;15(3):573-91.
16. Shamsaldini s, Zohour a.. Comparison between the effects of animal fat and sulfadiazine on healing of skin lesions in rabbits. *J ZANJAN UNIV MED SCI*. 2002;39(10):21-4.
[Available from: https://www.sid.ir/en/journal/ViewPaper.aspx?ID=31858](https://www.sid.ir/en/journal/ViewPaper.aspx?ID=31858)
17. Habibey R, Pazoki-Toroudi H. Morphine dependence protects rat kidney against ischaemia-reperfusion injury. *Clin Exp Pharmacol Physiol*. 2008;35(10):1209-14.
18. Zarch AV, Toroudi HP, Soleimani M, Bakhtiarian A, Katebi M, Djahanguiri B. Neuroprotective effects of diazoxide and its antagonism by glibenclamide in pyramidal neurons of rat hippocampus subjected to ischemia-reperfusion-induced injury. *Int J Neurosci*. 2009;119(9):1346-61.

19. Amani H, Mostafavi E, Arzaghi H, Davaran S, Akbarzadeh A, Akhavan O, et al. Three-dimensional graphene foams: synthesis, properties, biocompatibility, biodegradability, and applications in tissue engineering. *ACS Biomater Sci Eng*. 2018;5(1):193-214.
20. López JF, Sarkanen JR, Huttala O, Kaartinen IS, Kuokkanen HO, Ylikomi T. Adipose tissue extract shows potential for wound healing: in vitro proliferation and migration of cell types contributing to wound healing in the presence of adipose tissue preparation and platelet rich plasma. *Cytotechnology*. 2018;70(4):1193-204.
21. Summa M, Russo D, Penna I, Margaroli N, Bayer IS, Bandiera T, et al. A biocompatible sodium alginate/povidone iodine film enhances wound healing. *Eur J Pharm Biopharm*. 2018;122:17-24.
22. Casano AM, Sixt M. A Fat Lot of Good for Wound Healing. *Dev Cell*. 2018;44(4):405-6.
23. Toroudi HP, Rahgozar M, Bakhtiarian A, Djahanguiri B. Potassium channel modulators and indomethacin-induced gastric ulceration in rats. *Scand J Gastroenterol*. 1999;34(10):962-6.
24. Mehrjerdi FZ, Aboutaleb N, Pazoki-Toroudi H, Soleimani M, Ajami M, Khaksari M, et al. The protective effect of remote renal preconditioning against hippocampal ischemia reperfusion injury: role of katp channels. *J Mol Neurosci*. 2015;57(4):554-60.
25. Ajami M, Eghtesadi S, Razaz JM, Kalantari N, Habibey R, Nilforoushzadeh MA, et al. Expression of Bcl-2 and Bax after hippocampal ischemia in DHA+EPA treated rats. *Neurol Sci*. 2011;32(5):811-8.