

The Comparison of the Effect of *Origanum Vulgar* Aqueous Extract and Vitamin C on the Control of Cadmium Chloride Damage in Testicular Tissue in Male Rats

M. Raeeszadeh (PhD)^{*1}, M.M. Fallah (DVM)², E. Salimi Naghani (PhD)¹

1. Department of Basic Sciences, Sanandaj Branch, Islamic Azad University, Sanandaj, I.R.Iran

2. Department of Veterinary, Sanandaj Branch, Islamic Azad University, Sanandaj, I.R.Iran

J Babol Univ Med Sci; 20(8); Aug 2018; PP: 44-50

Received: Oct 19th 2017, Revised: Mar 6th 2018, Accepted: Mar 26th 2018.

ABSTRACT

BACKGROUND AND OBJECTIVE: Cadmium is one of the pollutants in ecosystems. This heavy metal as a toxin affects the reproductive system and causes the destruction of the spermatogenesis process. The aim of this study was to compare the effect of *Origanum vulgar* aqueous extract and vitamin C on cadmium chloride damage in testicular tissue.

METHODS: This experimental study was performed on 30 wistar male rat in four groups of six rats. The control received Cadmium 2 mg/kg of single dose intraperitoneal, T1 group received cadmium with vitamin C 250 mg/kg. T2, T3 and T4 groups received cadmium and aqueous extract of Marjoram at 125, 250 and 500 mg/kg, respectively for 10 days intraperitoneal. At the end of the period, the animals were weighed. Serum antioxidant level and malondialdehyde in testis tissue were measured. In addition, after staining were counted calls in testicular tissue.

FINDINGS: The highest concentration of MDA was observed in the control group at 1.4 ± 0.018 and the lowest in the T4 at 93.03 ± 0.30 $\mu\text{mol/ml}$. The lowest antioxidant capacity in control was 796.41 ± 40.76 and the highest in T4 group was 1198.91 ± 51.45 $\mu\text{mol/ml}$. There was no statistically significant difference in the concentration of MDA and TCA between T1 and T3 groups ($p=0.076$). However, the mean of testicular tissue cells (sertoli, spermatogonia, spermatocytes and laydic) in T3 was the highest and lowest mean in control group and the difference was significant ($P=0.048$).

CONCLUSION: According to results of this study, Marjoram aqueous extract in controlling oxidative stress damage in the same dose 250 mg/kg has a better performance than vitamin C.

KEY WORDS: Cadmium, Oxidative stress, Testicular tissue, Vitamin C, *Origanum vulgar*.

Please cite this article as follows:

Raeeszadeh M, Fallah MM, Salimi Naghani E. The Comparison of the Effect of *Origanum Vulgar* Aqueous Extract and Vitamin C on the Control of Cadmium Chloride Damage in Testicular Tissue in Male Rats. J Babol Univ Med Sci. 2018;20(8):44-50.

* Corresponding Author: M. Raeeszadeh (PhD)

Address: Department of Basic Sciences, Sanandaj Branch, Islamic Azad University, Sanandaj, I.R.Iran

Tel: +98 87 33288661

E-mail: vet_mr@yahoo.com

Introduction

Cadmium is one of the pollutants in ecosystems. This heavy metal as a toxin affects the reproductive system and causes the destruction of the spermatogenesis process. The degradation function of cadmium metal is accomplished by increasing the free radicals and inducing oxidative stress (1). previous researches in relation to cadmium reveals severe hemorrhage, edema and testicular necrosis. On the other hand, it causes a decrease in the number of sperm, a decrease in sperm motility and irreversible damage to the germinal epithelium in the testis (3, 2). It has also been shown that cadmium can also lower testosterone production (4).

A review study by Kheradmandi et al. revealed that various toxins have a deleterious effect on reproductive organs. Exposure to contaminants as well as physical stress can increase the rate of infertility. Antioxidant products are highly regarded because they can react to pollutants and remove free oxygen radicals. In new and valid studies, elements such as arsenic, cyclophosphamide, cadmium, diazinon and gossypol have reduced the rate of reproduction and damage to body tissues.

The general conclusion from the review of valid, sources of natural protectors in plants, fruits, and food products has been suggested to prevent reproductive toxicity of different toxins (5). *Origanum vulgare* is an aromatic herb of the family of mint. In previous studies, it has been given special attention to the antioxidant and anti-bacterial properties (7, 6).

Antioxidant properties of *Origanum vulgare* are mainly related to the presence of phenolic compounds such as Rosmarinic acid, Quercetin, Camphorol, Caffeic acid, and tocopherol homologues, which are considered as the strongest compounds for removal of free radicals (8).

Vitamin C is a water-soluble vitamins and glucose-derivative that acts as an electron carrier in the body's chemical reactions and is one of the most important antioxidants and is involved in the neutralization of free radicals and the elimination of oxidative stress [9]. Vijayprasad et al. indicated the protective effects of vitamin C against ROS injuries on mammalian sperm parameters (10).

Regarding the antioxidant potential of *Origanum vulgare* extract and vitamin C in controlling oxidative stress, the aim of this study was to compare the efficacy of *Origanum vulgare* extract and vitamin C on cadmium chloride damage in rat testicular tissue.

Methods

This experimental study, after approval by the Ethics Committee of Babol University of Medical Sciences with code IR.MUK.REC.1397/5002 was performed on 30 Wistar male rats weighing 200 ± 30 g, which were kept at 12 hours of light and 12 hours of darkness in animal house of faculty of veterinary medicine. Healthy water and standard concentrates were available to the animals without restriction. This research was conducted in accordance with the International Standards for Medical Research on Animals, which was established by the Council of International Medical Organizations (CIOMS) and has the ethical code of Kurdistan university of Medical Sciences (2029)(11). Rats were randomly divided into five groups of six and were subjected to the following tests:

Control group: Cadmium chloride produced by Merck Company (Lot number: FN1035040) 2 mg/kg on the second day/ single intraperitoneal injection and then intraperitoneal injection of normal saline with volume of extract for 10 days

First experimental group: pretreatment of vitamin C at a dose of 250 mg/kg and then on the second day single dose injection of cadmium chloride/ vitamin C treatment until 10 th day

Second experimental group: pretreatment of *Origanum vulgare* aqueous extract 125 mg/kg, then on the second day single dose of cadmium chloride and continue until 10th day daily peritoneal

Third experimental group: pretreatment of *Origanum vulgare* aqueous extract 250 mg/kg, then on the second day single dose of cadmium chloride and continue until 10th day with similar dose of extract

The fourth experimental group: pretreatment of *Origanum vulgare* aqueous extract 500 mg/kg, then on the second day single-dose cadmium chloride and continued as intraperitoneally administration of single dose cadmium chloride but extract and vitamin C per day for 10 days intraperitoneally (12). Then on the eleventh day, the mice were weighed with a digital scale (Precisa xb620C) and blood sampling was done from the animal's heart. The serum was isolated by centrifugation at 3000 g for 20 minutes and used to measure serum antioxidant concentrations (TCA). Animal were scarified using overdose of the thiopental. Left testis was used to prepare tissue sections and hematoxin-eosin staining. Spermatogonia cells, spermatocytes (primary and secondary), sertoli cells and leydig cells were counted in 100 microscopic fields. The obtained numbers were considered as the average

number of cells in each group. Also, the right testis tissue extract was used to measure the malondialdehyde (MDA), a final product of lipid peroxidation, using a thiobarbituric acid method (13). 1.5 ml of 10% trichloroacetic acid (Sigma-Aldrich, Germany) was added to 500 μ l of homogeneous tissue and centrifuged for 10 minutes. Then, 2 ml Thiobarbituric acid (Sigma-Aldrich, Germany) 67% was added to 1.5 ml of the supernatant solution and was placed for 30 minutes in a boiling water bath, then 2 ml butanol was added and after a severe vortex, centrifugation was performed at 4000 rpm for 15 minutes, and the absorbance of the pink solution was read at 532 nm. The concentration of malondialdehyde was determined using 1, 1, 3, 3 tetraethoxypropane (Sigma-Aldrich, Germany) as the standard and malondialdehyde concentrations were calculated in micromol per milliliter. A standard solution of malondialdehyde was prepared at 0.2-2% μ M concentration in sulfuric acid 10% (13).

Measuring Antioxidant Capacity: A total antioxidant capacity measurement was performed by Benzie et al., called Ferric-reducing ability of plasma (FRAP). In acidic pH, when the complex FeIII-2,4,6-Tri (2-pyridyl)-s-triazine (TPTZ) is reduced to FeII, producing a blue color. Its light absorption was read at 593 nm. Then, the total antioxidant capacity of serum was measured using a standard concentration diagram of 100-1000 μ mol/ml iron sulfate (14).

Preparation of *Origanum vulgare* aqueous extract: After collecting *Origanum vulgare* leaves from Kermanshah agricultural land and confirming the Herbarium center of the Kurdistan University, the leaves were dried in shade. Then it was powdered with the mill and mixed with 90 °C hot water in a weight ratio of 100/1 and kept in a 45°C warm bath for 20 minutes. Then it was flattened and kept in a hot water bath for condensation and then 37 °C hot air oven. After drying, the moisture content was measured. Different concentrations of extract 125, 250 and 500 mg/kg were

injected intraperitoneally (15). Vitamin C was injected intraperitoneally with a dose of 250 mg/kg.

Data analysis: Data obtained from histomorphometric results of testicles (diameter and weight), cytology, malondialdehyde concentration and total antioxidant capacity of serum were analyzed by one-way ANOVA and Tukey's post hoc test (Tukey). statistical analysis was performed using SPSS21 software and $p < 0.05$ was considered significant.

Results

There was no statistically significant difference between the weight of the rats on the first day. However, in the last day of the study, the lowest weight was observed for the control group (cadmium chloride) and the highest weight of the animals in the third experiment group (receiving 250 mg/kg extract). The difference in weight between control and other experimental groups was significant ($p = 0.044$) (Table 1).

The mean right and left testis weight in the control group was higher, but the right and left testis diameter was the lowest in the control group. Although these changes were not significant with other groups ($p > 0.05$) (Table 2).

Table 1. Average weight of the first and last days of animals in different groups

Weight of rats Groups	In first day (g) Mean \pm sem	In last day (g) Mean \pm sem
Control	214.66 \pm 1.28 ^a	195.66 \pm 0.76 ^a
First	220.66 \pm 3.9 ^a	219.33 \pm 3.9 ^b
Second	232 \pm 5.51 ^a	227.33 \pm 4.75 ^b
Third	224.33 \pm 2.92 ^a	230 \pm 4.02 ^b
Fourth	222 \pm 6.7 ^a	217 \pm 0.96 ^b

Latin non-uniform columnar letters showing a statistically significant difference ($p < 0.05$)

Table 2. The mean of right and left testicles and their diameter in the animals studied in different groups

Testis parameter Groups	Right weight (g) Mean \pm sem	Left weight (g) Mean \pm sem	Right diameter (cm) Mean \pm sem	Left diameter (cm) Mean \pm sem
Control	0.75 \pm 0.062	0.79 \pm 0.066	1.2 \pm 0.036	1.2 \pm 0.036
First	0.64 \pm 0.032	0.65 \pm 0.03	1.2 \pm 0.073	1.33 \pm 0.091
Second	0.64 \pm 0.02	0.67 \pm 0.023	1.33 \pm 0.021	1.43 \pm 0.084
Third	0.75 \pm 0.06	0.72 \pm 0.039	1.30 \pm 0.036	1.3 \pm 0.036
Fourth	0.74 \pm 0.067	0.69 \pm 0.043	1.26 \pm 0.055	1.36 \pm 0.042

In association with malondialdehyde, the highest concentrations were in the control group receiving Cadmium chloride with an average of 1.4 ± 0.018 $\mu\text{mol/ml}$ and the lowest in the fourth group with 0.93 ± 0.03 $\mu\text{mol/L}$, respectively. There was a significant difference between the control group and all the experimental groups ($p=0.042$). In the first and third experimental groups, the concentration of malondialdehyde was 0.990 ± 0.05 and 0.98 ± 0.034 $\mu\text{mol/ml}$, which was not statistically significant (Fig 1). Total antioxidant capacity in the fourth group had the highest concentration of 11998.91 ± 51.45 and in the control group the lowest concentration was 796.41 ± 40.76 $\mu\text{mol/ml}$. In terms of serum total antioxidant capacity, vitamin C and Origanum vulgar extract 250 mg/kg were 900.98 ± 42.54 and $955.41/66.65$ $\mu\text{mol/ml}$, respectively. Although Origanum vulgar extract was higher than vitamin C in the extracts group, this difference was not significant (Fig 2).

According to the results, the most sertoli cells as resistant and supporting cells of testicular tissue were in the third experiment group with an average of 12.02 ± 0.73 , then the first and fourth experimental groups were 7.66 ± 0.42 and 7.01 ± 0.73 . There was a statistically significant difference between the third group and the other groups ($p=0.034$). The spermatogonia cells (the first category of sex cells) were highest to the lowest in the third, fourth, first, second, and control groups with an average of 28 ± 1.31 , 17.66 ± 0.91 , 12.66 ± 1.11 , 11.66 ± 0.42 , 11.33 ± 0.55 . Mean changes in the third experimental group were significant ($p=0.038$), while the difference between the control and the first and second experimental groups was not significant. In spermatocyte cells, which contained primary and secondary spermatocyte, the highest number of spermatocytes in the third experiment group was 36.67 ± 1.72 , the fourth experimental group was 17.33 ± 0.21 , the second experimental group with mean $13.03 \pm 0.73/13$, the first experimental group was 8.33 ± 0.55 and then the control group was 7.33 ± 0.42 . There was a significant difference

between the Origanum vulgar extract (250 mg) and other groups ($p=0.041$). In relation to the leydig cells, the lowest number was in the control group with average of 423.83 ± 7.61 and the highest average in the third experimental group was 585.0 ± 3.92 . The mean of leydig cells in the third group was significantly different with the control and other experimental groups ($p=0.043$)(Table 3, Fig 3).

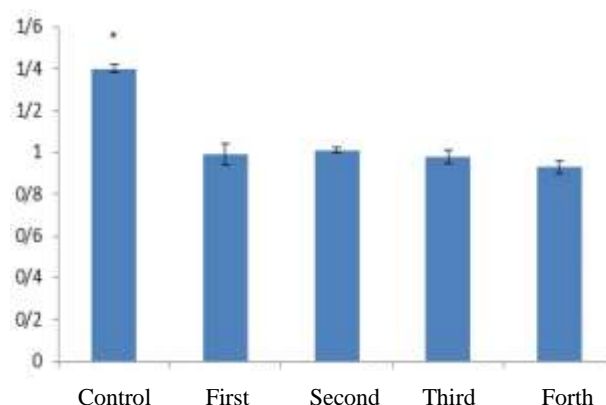


Figure 1. Changes in malondialdehyde concentration in testis tissue of studied rats. *Significant statistical difference with other groups

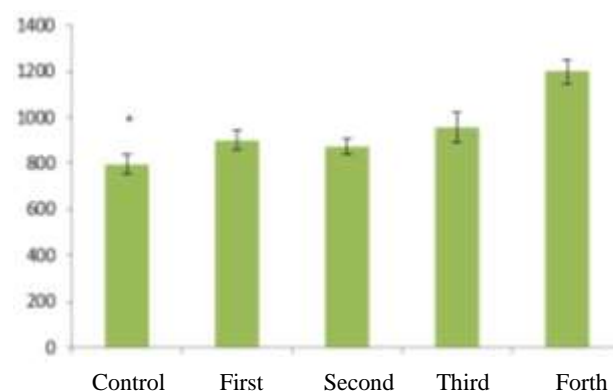


Figure 2. Evaluation of changes in total antioxidant capacity of serum in studied rats. *Significant statistical difference with other groups.

Table 3. Mean \pm SEM of different testicular tissue cells in different groups

Parameters	Sertoli	Spermatogonia	Spermatocyte	Leydig cells
Groups	Mean \pm sd	Mean \pm sd	Mean \pm sd	Mean \pm SD
Control	6 \pm 0.36 ^a	11.33 \pm 0.55 ^a	7.33 \pm 0.42 ^a	423.83 \pm 7.61 ^a
First	7.66 \pm 0.42 ^a	12.66 \pm 1.11 ^a	8.33 \pm 0.55 ^a	457.83 \pm 11.18 ^a
Second	2.33 \pm 0.21 ^c	11.66 \pm 0.42 ^a	13.03 \pm 0.73 ^b	493.33 \pm 6.29 ^a
Third	12.0 \pm 0.73 ^b	28 \pm 1.31 ^b	36.67 \pm 1.72 ^c	585 \pm 3.92 ^b
Forth	7.01 \pm 0.73 ^a	17.66 \pm 0.91 ^c	17.33 \pm 0.21 ^d	498.16 \pm 2.74 ^a

Latin non-uniform columnar letters showing a statistically significant difference ($p < 0.05$)

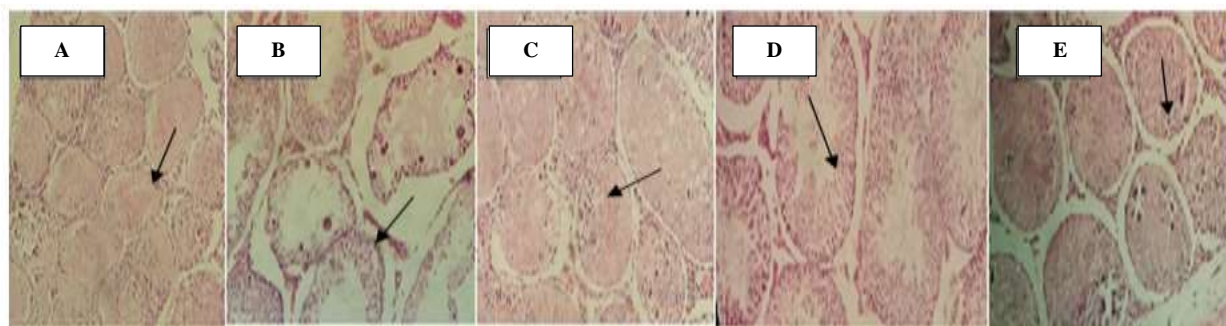


Figure 3. H & E staining, 4x magnification: left to right control group (A) (severe reduction of cell lines), first experimental group (B), second experimental group (C). Third experimental group (D) (increase in cell lines than other groups). The fourth experimental group (E).

Discussion

Based on the results, the lowest weight of the rats was in the cadmium chloride receiving group on the last day. In the histomorphometric data of the testicles, the lowest testicular diameter was allocated to the cadmium group. Given the toxicity and the effects of cadmium on atrophy of testicles and the body this issue is justifiable. Regarding the concentration of malondialdehyde, there was a significant difference between the control group and the other groups. Regarding serum antioxidant capacity, there was no significant difference between the extract group at 250 mg/kg and vitamin C at the same dose. However, with increasing concentration of extract in 500 mg/kg, this difference was statistically significant. The mean of spermatogonia cells in rats based on the results showed that the highest mean number of spermatogonia cells was related to 250 mg/kg extract and this difference was significant with other groups. In the review, Adewoyin M et al., found that dual bands in fatty acids in the membrane of spermatozoa are sensitive to free oxygen radicals, and compounds such as vitamins C, E, carotenoids and carnitine are considered as effective compounds and antioxidants outside the body against single-electron oxygen species and controller of peroxidation of spermatozoa membrane lipids and prevention of male infertility (16). In the study of El-Demerdash et al., entitled "Effect of Vitamin C and E on the process of spermatogenesis in cadmium-encountered mice, it was concluded that mice receiving vitamins C and E had higher sperm concentration, decreased lipid peroxidation, decreased abnormal spermatozoa, and also increased levels of antioxidant in the body than those receiving cadmium (17). In a study by Emadi et al., vitamin C with antioxidant effects was considered to be an effective and protective factor in preventing damages caused by free radicals and temperature in

undescending testis in mice (18). Ognjanović et al. reviewed the effect of vitamin E and coenzyme Q10 on oxidative stress due to cadmium in mice. They considered cadmium toxicity to reduce superoxide dismutase, catalase and glutathione and also decrease intracellular vitamin C concentrations. Vitamin E and coenzyme Q10 showed strong efficacy against oxidative stress in mice (19). The results of the recent study on the oxidative stress control of testicular tissue at the time of administration of vitamin C in comparison with the control group were in line with the above-mentioned research. In a study by Mostafavi et al., it was concluded that *Origanum vulgare* extract would maintain sperm quality against adverse effects of copper poisoning (20). In a study by Ghorbani Ranjbar et al on the effect of wild *Origanum vulgare* extract on the level of gonadotropin and testosterone, a dose of 400 mg/kg for 28 days increased levels of hormones and affect the sperm and fertility (21).

Balubaid regarding the protective effects of *Origanum vulgare* on cadmium toxicity in mice testis concluded that in the group receiving *Origanum vulgare* with a dose of 2 mg/kg for 60 days, the concentration of sperm and testosterone were similar to that of the control group. In the group administering *Origanum vulgare* and Cadmium chloride, the concentration of sperm and testosterone was slightly higher than the group receiving Cadmium chloride and less than the control group. It can be concluded that the industry should remove cadmium metal due to the strong infertility effects and other metal items should be replaced. Although it was possible to preserve the protective effect of *Origanum vulgare* on cadmium (22). In the study of Fallah et al., the effect of *Origanum vulgare* extract at an appropriate dose has been shown to control the oxidative stress and improve the conditions for spermatogenesis and fertility (23). In this study, a dose of 250 mg/kg of *Origanum vulgare* extract was the

most appropriate dose for controlling oxidative effects of cadmium in the process of spermatogenesis. According to a recent study, the same dose of vitamin C showed a lower potential for oxidative stress control and improvement of spermatogenesis in rats than *Origanum vulgare* extract. Study of Kazami et al. mentioned the changes in FSH so that using oral doses of 20 and 40 mg/kg of *Origanum vulgare* ethanolic extract hormone changes were 0.338 ± 0.03 and 0.372 ± 0.026 , respectively. In a dose of 40 mg, the level of hormone decreases and may also have an effect on spermatogenesis. However, the duration of the study and serial doses used is different, and the type of extract is also ethanolic, which was different from the previous study (24). Regarding the oxidative stress factor, the highest concentration of malondialdehyde was observed in the control group and the lowest in the fourth experimental group. While the highest antioxidant capacity was seen in the fourth experimental group. The increase in antioxidant capacity has led to a decrease in malondialdehyde concentration. Of course, this effect

was not entirely positive on the process of spermatogenesis. Because the concentration of antioxidants at the appropriate dose can be desirable and non-toxic. In confirmation of the results, measurement of the concentration of superoxide dismutase enzymes, catalase and glutathione peroxidase, as well as hormonal profiles, can complement the recent study. Regarding the results of testicular histology and oxidative stress factors, it is possible to express the effectiveness of *Origanum vulgare* extract in comparison with vitamin C at a dose of 250 mg/kg. With more comprehensive studies, the potential of this extract can be used in the manufacture of male fertility boosters.

Acknowledgment

Hereby, we would like to thank the Vice-Chancellor for Research at Islamic Azad University, Sanandaj Branch, as well as Ms. Shafiei, the expert of the Faculty Research Laboratory for cooperation in conducting the research.

References

- Skolarczyk J, Budzyński M, Pekar J, Małecka-Massalska T, Skórzyńska-Dziduszko K. The impact of cadmium on male infertility. *J Elem.* 2017; 22(2):35-44.
- Aziz DM. Assessment of bovine sperm viability by MTT reduction assay. *Anim Reprod Sci* 2006; 92(1-2): 1-8.
- Aitken RJ, Baker MA. Oxidative stress, sperm survival and fertility control. *Mol Cell Endocrinol.* 2006; 250(1-2):66-9.
- Bernard A. Cadmium & its adverse effects on human health. *Indian J Med Res.* 2008;128(4): 557-64.
- Kheradmandi R, Jorsaraei S. The Effect of Protective Factors on Induced Toxins in Genital Organs. *J Babol Univ Med Sci.* 2017; 19(10): 48-56.
- Roofchaei A, Irani M, Ebrahimzadeh MA, Akbari MR. Effect of dietary oregano (*Origanum vulgare* L.) essential oil on growth performance, cecal microflora and serum antioxidant activity of broiler chickens. *Afr J Biotechnol.* 2011; 10(32): 6177-83.
- Skoula M, Grayer RJ, Kite GC, and Veitch NC. Exudate flavones and flavanones in *Origanum* species and their interspecific variation. *Biochem Syst Ecol.* 2008; 36(8): 646-54.
- Cervato G, Carabelli M, Gervasio S, Citterra A, Cazzola R, Cestaro B. Antioxidant properties of oregano (*Origanum Vulgare*) leaf extracts. *J Food Biochem.* 2000; 24(6): 453-65
- Aly N, El-Gendy K, Mahmoud F, El-Sebae AK. Protective effect of vitamin C against chlorpyrifos oxidative stress in male mice. *Pestic Biochem Physiol.* 2010; 97(1):7-12.
- Vijayprasad S, Bb G, Bb N. Effect of Vitamin C on Male Fertility in Rats Subjected to Forced Swimming Stress. *J Clin Diagn Res.* 2014; 8(7): HC05-C08.
- Albus U. Guide for the Care and Use of Laboratory Animals. 8th ed. USA: The National Academies Press; 2011: 11-40.
- Sen Gupta R, Sen Gupta E, Dhakal BK, Thakur, Ahnn J. Vitamin C and vitamin E protect the rat testes from cadmium-induced reactive oxygen species. *Mol Cells* 2004; 17(1): 132-39.
- Satoh K. Serum lipid peroxide in cerebrovascular disorders determined by a new colorimetric method. *Clin Chim Acta* 1978; 90: 37-43.
- Benzie IFF, Strain JJ. The ferric reducing ability of plasma (FRAP) as a measure of antioxidant power: The FRAP assay. *Analyt Biochem* 1996 ; 239: 70-76.
- Abbasnejad M, Mirtajadini M, Afarinesh M, Hassibi N. Evaluation of origanum leaves extract on spatial learning in male rats. *J Physio Pharma.* 2006; 10(2): 143-50.
- Adewoyin M, Ibrahim M, Roszaman R, Isa MLM, Alewi NAM, Rafa AAA, et al. Male Infertility. The Effect of Natural Antioxidants and Phytochemicals on Seminal Oxidative Stress. *Diseases.* 2017 Mar 1;5(1). pii: E9.
- El-Demerdash FM, Yousef MI, Kedwany FS, Baghdadi HH. Cadmium-induced changes in lipid peroxidation, blood hematology, biochemical parameters and semen quality of male rats: protective role of vitamin E and beta-carotene. *Food Chem Toxicol.* 2004; 42(10): 1563-71.
- Emadi L, Azar O, Gholipur H, Saeedi M. Effect of Vitamin C on epididymal sperm quality in the rat experimentally induced unilateral cryptorchidism. *Iran J Veterin Surg.* 2012; 7(1-2): 63- 74.
- Ognjanović BI, Marković SD, Ethordević NZ, Trbojević IS, Stajin AS, Saicić ZS. Cadmium-induced lipid peroxidation and changes in antioxidant defense system in the rat testes: protective role of coenzyme Q(10) and vitamin E. *Reprod Toxicol.* 2010, 29(2): 191-7.
- Mostafavi A, Sakhayee E.A, Abshanas J. Effect of Marjoram extract on the concentration of spermatid epidermis following copper poisoning in mice. [PhD Thesis]. Kerman: Shahid Bahonar Univ, 2013. Available from: <https://ganj-old.irandoc.ac.ir/articles/660581>. [In Persian]
- Ghorbani Ranjbary A, Ghorbani Ranjbary N, Ghorbani Ranjbary Z, Jouibar F. Effects of Intraperitoneal Injection of Extracts of *Origanum Vulgare* on Gonadotropin and Testosterone Hormones in Male Wistar Rats. *J Babol Univ Med Sci.* 2014; 16(4):57-63. [In Persian]
- Falah MM, Raeeszadeh M, Salimi Naghani E. The Different Doses of Aqueous Extract of Marjoram Effects on Spermatogenesis and Sperm Concentration in Cadmium-induced Oxidative Damage in Rats. *J Shahid Sadoughi Univ Med Sci* 2017; 25(3): 230-40. [In Persian]
- Balubaid S.O.A. B. Protective Effect of Marjoram Plant against the Toxicity of Cadmium Chloride in Testes of Albino Rat. *Biosci Biotech Res Asia* 2010; 7(2): 667-74.
- Kazemi P, Jowhary H, Sharifi E, Zeraat-Pishe A. Androgenic Effect of *Origanum vulgare* L.spp viride extract on Hormone Level of Pituitary - gonadal Axis in Mature Male Vistar Rats. *Arak Med Univ J.* 2012; 14(59): 89-96.[In Persian]