

The Protective Effect of Royal Jelly on Testicular Tissue and Sperm Parameters in Adult Mice Treated with Nicotine

F. Azad (MSc)^{*1}, V. Nejati (PhD)¹, A. Shalizar Jalali (PhD)², Gh. Najafi (PhD)², F. Rahmani (PhD)¹

1. Department of Biology, Faculty of Science, Urmia University, Urmia, I.R.Iran

2. Department of Basic Sciences, Faculty of Veterinary Medicine, Urmia University, Urmia, I.R.Iran

J Babol Univ Med Sci; 20(3). ; Mar 2018; PP: 50-8

Received: Oct 3rd 2017, Revised: Jan 24th 2018, Accepted: Feb 14th 2018.

ABSTRACT

BACKGROUND AND OBJECTIVE: As a medicinal compound, nicotine has adverse effects on the male reproductive system. Since royal jelly can modify the oxidative stress through its antioxidant properties, this study was conducted to investigate the protective effect of royal jelly on testicular tissue and sperm parameters in adult mice treated with nicotine.

METHODS: In this experimental study, 36 adult male mice were randomly divided into six groups of six. The first group received physiologic serum, the second group received royal jelly at 100 mg/kg/day, and the third and fourth groups received nicotine at 0.5 mg/kg/day and 1 mg/kg/day, respectively. The fifth and sixth groups received 0.5 mg/kg/day and 1 mg/kg/day royal jelly in addition to nicotine, respectively. After weighing and dissection, left testicles were used for histological studies and left epididymal sperm were used for sperm evaluations.

FINDINGS: Nicotine caused a significant decrease in spermatogonial cells (0.5: 36.40 ± 2.92 and 1: 31.80 ± 5.12) and significant increase in non-motile (0.5: 36.40 ± 2.92 and 1: 31.80 ± 5.12), dead (0.5: 19.06 ± 0.71 and 1: 25.38 ± 1.41) and abnormal (0.5: 17.07 ± 0.68 and 1: 32.25 ± 1.27) sperm compared with the control group (8.12 ± 0.27 , 11.08 ± 1.03 and 8.36 ± 0.61 , respectively) ($p < 0.05$). The co-administration of royal jelly significantly reduced the spermatogonial cell count (0.5+royal jelly: 43.25 ± 3.80 and 1+royal jelly: 42.22 ± 5.28) and improved the amount of non-motile (0.5+royal jelly: 11.01 ± 1.49 and 1+royal jelly: 12.36 ± 1.21), dead (0.5+royal jelly: 11.73 ± 0.97 and 1+royal jelly: 12.31 ± 1.07) and abnormal (0.5+royal jelly: 10.62 ± 0.85 and 1+royal jelly: 11.82 ± 0.96) sperm compared with groups treated with nicotine.

CONCLUSION: The results of the study showed that royal jelly reduces reproductive toxicity of nicotine in mice by improving the testicular structure and sperm parameters.

KEYWORDS: Nicotine, Royal Jelly, Testicles, Mice, Sperm.

Please cite this article as follows:

Azad F, Nejati V, Shalizar Jalali A, Najafi Gh, Rahmani F. The Protective Effect of Royal Jelly on Testicular Tissue and Sperm Parameters in Adult Mice Treated with Nicotine. J Babol Univ Med Sci. 2018;20(3):50-8.

*Corresponding Author; F. Azad (MSc)

Address: Department of Biology, Faculty of Science, Urmia University, Urmia, I.R.Iran.

Tel: +98 44 32755295

E-mail: farnam.azad@hotmail.com

Introduction

Smoking as one of the most important public health problems may have adverse effects on the fertility of men and women (1, 2). Nicotine, as a highly volatile alkaloid, is one of the most important components of cigarette smoke, which may have harmful effects on the body (3). There is clear evidence that nicotine increases oxidative stress, and lipid peroxidation, and decreases antioxidant activity in the male reproductive system (4).

On the one hand, spermatozoa is prone to oxidative damage because of high levels of unsaturated fatty acids in the plasma membrane and low levels of cytoplasmic antioxidants. Studies have shown that administration of nicotine in experimental animals reduces testicular weight, and increases the malformation of the attached glands, epididymis, and vas deferens (6). On the other hand, it has been shown that the dose and exposure time of nicotine in mice is directly related to malignant changes in testicular tissue (7).

Nicotine passes easily through the membrane of the body cells and is able to react with some intracellular components, such as the tubulin protein in the cytoplasm of dividing cells, such as the germ cells, and thereby, disrupts cell division (8). Moreover, reports show that nicotine causes degenerative changes in the seminiferous tubules, reduces spermatogenesis, and impairs testicular function (9). Nicotine consumption may damage the membrane and DNA of the sperm and induce apoptosis in testicular cells (10). Studies have also shown that administration of nicotine in mice thickens the tunica propria by increasing the collagen fibers of basal cell layer, destroys intercellular junctions of Sertoli cells, causes chromosomal abnormalities, leads to the formation of Sertoli cells with polymorphic mitochondria, degenerated germ cells, excessive accumulation of lipid droplets in the sperm cytoplasm and morphological abnormalities in the sperm (11).

On the other hand, nicotine toxicity may be due to changes in the ratio of collagen fibers to myoid contractile cells, which may prevent proper release of sperm from germinal epithelium to the middle cavity of seminiferous tubules (11, 12). Previous reports have also shown that, in addition to reducing the sperm count, motility and viability, nicotine administration increases sperm deformity and apoptosis (13). Royal jelly is known as the food of the honey bee queen and is used by young larvae and the queen. This substance

plays an important role in feeding the queen and is secreted from the pharyngeal glands of the young worker bees. Royal jelly is a milky-white substance with a strong smell, fruity flavor and high nutritional value. This gel is the cause of bigger size, high fertility and longer life of the queen (14).

As a superfood, royal jelly consists of 66% water, 15% sugar, 5% lipid and 13% protein, essential amino acids and vitamins (15). Royal jelly also has a variety of biological activities in cells and tissues and have stimulatory effects on different organs of the body and can improve their performance against oxidative stress (16, 17). In addition, royal jelly is considered as a stimulant to maintain the regular and normal activity of hormones, which is valuable in the treatment of chronic sexual dysfunction (18).

So far, there has been no report on the adverse effects of royal jelly on biological systems. Due to its antioxidant properties against oxidative stress, the effects of oral administration of royal jelly on testicular tissue structure and sperm parameters in mice treated with nicotine have not been investigated. Therefore, the present study was conducted to investigate the possible protective effects of royal jelly on body and testicle weight, testicular tissue structure and motility, viability and morphology of epididymal sperm against reproductive toxicity of nicotine in white lab mice (BALB/C).

Methods

Nicotine ($C_{10}H_{14}N_2$) solution was purchased from Sigma Co. (Germany) and two doses of 0.5 mg/kg and 1 mg/kg were prepared by normal saline. The royal gel used in this study was prepared from beehives in the city of Urmia in August 2016 and after being approved by the Department of Health and Food of the Faculty of Veterinary Medicine, it was prepared at a dose of 100 mg/kg.

In this experimental study, 36 adult male Balb/c mice with a mean age of 60 ± 5 were purchased from the animal house of the Urmia University of Medical Sciences. Animals were kept in a room with an ambient temperature of 24 ± 2 °C and a humidity of $75 \pm 5\%$, 12/12 natural light cycle and in 35×55 cm steel cages. The drinking water of animals was city tap water and they were fed with mice food (plate). All stages of this study were performed according to the rules of the principles for working with laboratory animals (European Commission Directive

86/609/EEC). They were kept in laboratory and in the cage for two weeks in order to adapt the animals to the environment. After this period, the animals were randomly divided equally (6 animals per group) into 6 groups and were examined after 35 days. The first group received 0.20 ml normal saline orally as the control group. The second group received only 0.20 ml royal jelly at a dose of 100 mg/kg/day. The third group received 0.2 ml nicotine at a dose of 0.50 mg/kg/day orally. The fourth group received 0.2 ml nicotine at a dose of 1 mg/kg/day orally. The fifth group received 0.2 ml nicotine at a dose of 0.5 mg/kg/day and 0.2 ml royal jelly at a dose of 100 mg/kg/day orally. In the sixth group, 0.2 ml of nicotine at a dose of 1 mg/kg/day and 0.2 ml royal jelly at a dose of 100 mg/kg/day were administered orally. At the end of the treatment period and 24 hours after the last treatment, all the mice in the six groups were anesthetized with ketamine and were subsequently sacrificed after weighing.

In order to evaluate the sperm characteristics, the epididymis was first separated from the testicular tissue under a 20X Magnifying Loupe and the surrounding tissues were cleaned after the autopsy. Immediately, the epididymal tail was placed in a petri dish containing one ml of human tubal fluid (HTF). Then, the epididymal tail was crushed into small pieces in the medium and remained in the incubator for 20 minutes to allow the sperm to leave the epididymis. Finally, the suspension containing sperm was diluted at a ratio of 1 to 20 using the culture medium. All the used equipment and the culture medium were placed in a 37 °C incubator before use to prevent thermal shock and damage to sperm (19).

To determine the sperm motility, one drop of the diluted solution was placed on a microscope slide and ten microscopic fields of view were examined at 400X magnification. Then, the total average of non – motile sperm in these ten fields of vision was recorded as the percentage of motility (19). To evaluate the number of sperm using a hemocytometer, ten microliters of the diluted sperm solution was placed on a hemocytometer and was left there without movement for five minutes to reduce sperm motility. The number of sperm per milliliter was calculated using the formula ($d \times 50000 \times n$) and was calculated at 400X magnification using an optical microscope, where n is the number of sperm counted in five squares of the hemocytometer and d is the dilution of the suspension containing sperm (19). In order to evaluate the percentage of dead sperm and

the morphologically abnormal sperm, the Eosin-nigrosin staining technique was used. In this method, the differentiation of live sperm from dead sperm is based on the fact that sperm become permeated against the mentioned color due to the damage to the plasma membrane. Therefore, those sperm with stained head, neck or tail are considered as dead sperm. Sperm with cytoplasmic remnants and other morphological disorders were considered as abnormal sperm (Fig 1). Two hundred sperm were examined for each sample at 400X magnification and the results were expressed as percent (19). After autopsy, the testis of the animals was measured by a laboratory scale (with 0.001 gr accuracy) and tissue samples of the testicle were removed while following the principles of sterile technique, and the left testicles were transferred to a 10% formalin solution for fixing (20).

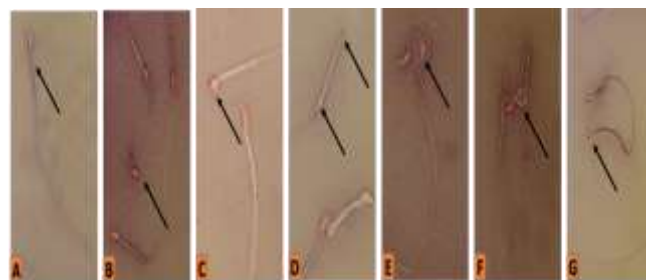


Figure 1. Some morphological abnormalities of sperm in nicotine – treated groups. A: Normal sperm. B: Without tail. C: Circle head. D: Without head and containing proximal cytoplasmic. E: Curved head. F: Spiral tail. G Tied tail. Eosin-nigrosin staining. 400X magnification.

After fixing, tissue samples of the left testicle were placed in special containers with their specifications and were then molded using melted paraffin wax during the steps of tissue passage. Then, five–micrometer sections were cut from paraffin molds using Microtome tool. Finally, Eosin-nigrosin stain and Periodic acid–Schiff stain were used to stain the samples. In the prepared tissue sections, in addition to counting spermatogenic and Sertoli cells based on morphology of cells (21), the diameter of the seminiferous tubules and the thickness of the germinal epithelium were also measured and recorded with the help of eyepiece. For counting the cells in each group, ten sections were randomly selected. In each section, ten seminiferous tubules were randomly measured and the cells were counted. Furthermore, Johnsen's Spermatogenesis Index was used to evaluate spermatogenesis. For this purpose, the cross sections

of 100 seminiferous tubules in each animal were used and each tubule was scored from 1 to 10 according to the Johansen's classification model (Table 1) (22). The histological sections were stained using Periodic acid–Schiff (PAS) to study carbohydrate compounds, in which PAS-positive reaction was visible in red (23). Data were analyzed by SPSS software version 22 using one-way ANOVA and Tukey's Post Hoc Test, while $p < 0.05$ was considered significant.

Table 1. Evaluation of spermatogenesis based on Johnsen's Spermatogenesis Index

Histopathological appearance	Score
Complete spermatogenesis in all tubules	10
A large number late spermatid, irregular tubular epithelium	9
Few late spermatid	8
Without late spermatid, a large number of premature spermatid	7
Without late spermatid, stopping at the early spermatid stage	6
A large number of spermatocytes without spermatid cells	5
Stopping in primary spermatocyte	4
Only spermatogonia cells	3
Only Sertoli cell	2
Tuberos sclerosis	1

Results

Weight of body and testicle: The present study showed that the mean body weight and testicular weight of animals in nicotine – treated groups were significantly lower than the controls and royal jelly group ($p < 0.05$). However, in the groups receiving royal jelly and nicotine, there was a significant increase ($p < 0.05$) in body weight and testicular weight in comparison with groups receiving nicotine alone (Table 2).

Evaluation of the characteristics of the epididymal sperm: The results from evaluation of sperm parameters showed that dose-dependent administration of nicotine significantly decreased ($p < 0.05$) the mean sperm count and significantly increased ($p < 0.05$) dead, immature sperm and sperm with abnormal morphology compared to the control group and royal gel group.

On the other hand, the simultaneous administration of royal jelly and nicotine significantly increased ($p < 0.05$) the sperm count and significantly decreased ($p < 0.05$) dead and non-motile sperm and sperm with

abnormal morphology compared to groups that received nicotine alone (Fig 2, 3).

Counting testicular germ cells and Sertoli cells: The results related to germ cell and Sertoli also indicated that the mean count of spermatogenic cells, primary spermatocyte, spermatid, and Sertoli cells in the nicotine – receiving groups in both doses showed significant difference ($p < 0.05$) with the control group (Table 3). On the other hand, simultaneous administration of royal jelly and nicotine resulted in a significant increase ($p < 0.05$) in the number of spermatogenic and Sertoli cells compared to groups receiving nicotine alone (Table 3).

Evaluation of spermatogenesis: The results of evaluation of spermatogenesis revealed that there was a significant decrease ($p < 0.05$) in Johnsen's Spermatogenesis Index in the nicotine-receiving groups at both doses compared to the control and royal jelly groups. On the other hand, in groups receiving both royal jelly and nicotine, there was a significant improvement ($p < 0.05$) in spermatogenesis progression compared to groups receiving nicotine alone (Fig 4).

Morphometric evaluation of seminiferous tubules: Based on morphometric evaluations, the thickness of germinal epithelium and the diameter of the seminiferous tubules showed significant decrease in groups receiving nicotine dose-dependently compared with control group and royal jelly group ($p < 0.05$). However, in nicotine + royal jelly groups, there was a significant increase ($p < 0.05$) in histological parameters compared to groups treated with nicotine (Table 4).

Morphology of testicular tissue: The evaluation of the testicular tissue morphology showed that the seminiferous tubules and their germinal epithelium have a normal structure in the control and royal jelly groups. The atrophy of the seminiferous tubules, tissue edema, and loss of germinal epithelium height were observed in the testicles of mice treated with nicotine. The germinal epithelium of the seminiferous tubules of these animals has lost its conjunction and vacuoles could be observed in spermatogenic epithelium in some areas.

Tissue damage and changes in the testicles were significantly reduced in groups receiving royal jelly and nicotine. After PAS staining, it became evident that the Leydig cells in the control group and royal jelly group showed the most reaction to PAS staining and the germinal epithelium of the seminiferous tubules also showed PAS-positive reaction (Fig 2). In the groups treated with nicotine, the reaction to PAS

staining in the Leydig cells and the germinal epithelium of the seminiferous tubules decreased significantly. In the groups receiving nicotine+royal

jelly, the reaction to PAS staining in Leydig cells and germinal epithelium of the seminiferous tubules was similar to that of the control group (Fig 5).

Table 2. Comparison of the body weight and testicle weight of mice in different experimental groups

Groups	Weight	Body weight before treatment (g)	Body weight after treatment (g)	Testicle weight (mg)
Control		31.68±1.25 a	32.98±2.48 a	97.64±3.11 a
Royal jelly		31.12±1.16 a	32.00±2.69 a	97.51±4.59 a
Nicotine 0.50		32.01±1.42 a	27.46±2.69 b	79.42±3.48 b
Nicotine 1.00		31.09±1.09 a	25.38±2.51 b	68.12±2.99 c
Nicotine 0.50+Royal Jelly		31.74±1.06 a	31.44±1.69 a	96.69±4.51 a
Nicotine 1.00+Royal Jelly		31.74±1.57 a	32.66±1.30 a	94.58±2.27 a

Non-similar letters in each column indicate a significant difference (p<0.05)

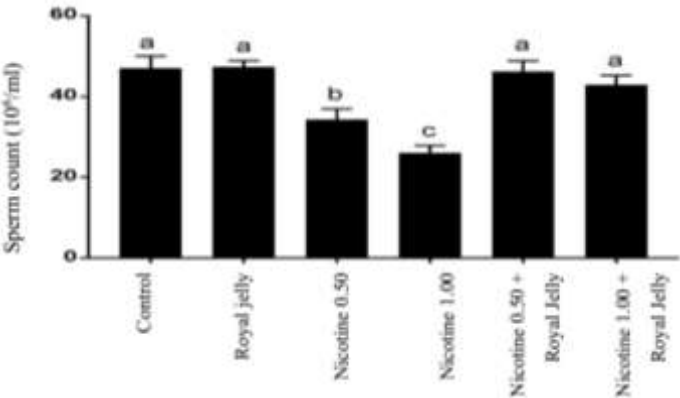


Figure 2. Comparison of the sperm count in different experimental groups.

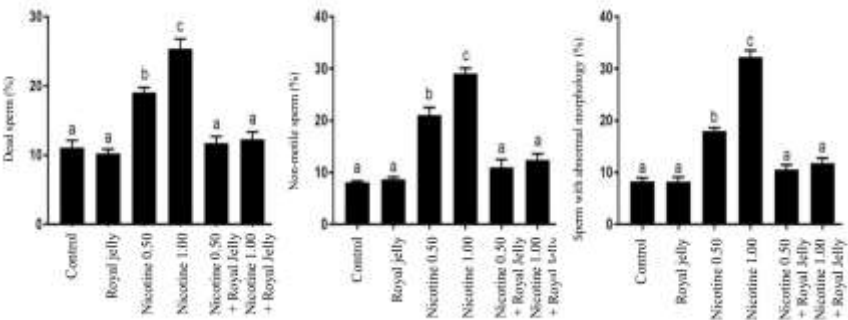


Figure 3. Comparison of dead, non-motile, sperm and sperm with abnormal morphology in different experimental groups. Non-similar letters in each column indicate a significant difference (p<0.05)

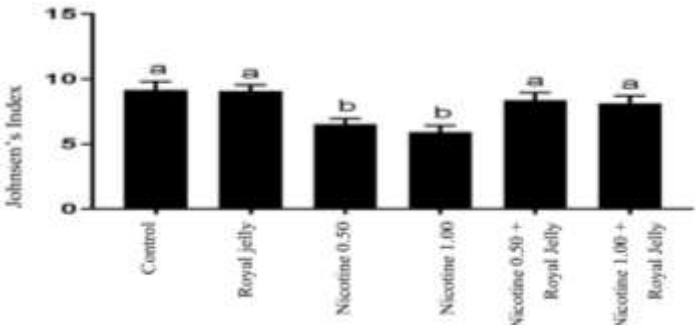


Figure 4. Comparison of the mean Johnsen's Spermatogenesis Index in different experimental groups
Non-similar letters in each column indicate a significant difference (p<0.05)

[DOR: 20.1001.1.15614107.1396.20.3.7.5]
[DOI: 10.18869/acadpub.jbums.20.3.50]

Table 3. Comparison of the number of spermatogonium, spermatocyte, spermatid and Sertoli cells in different experimental groups

Group	Spermatogonium	Spermatocyte	Spermatid	Sertoli
	Mean±SD	Mean±SD	Mean±SD	Mean±SD
Control	48.67±4.21 a	50.19±3.19 a	106.78±14.68 a	16.80±1.27 a
Royal jelly	48.94±4.20 a	48.79±2.41 a	112.84±28.35 a	17.33±1.71 a
Nicotine 0.50	36.40±2.92 b	39.23±2.07 b	70.69±9.04 b	13.48±1.37 b
Nicotine 1.00	31.80±5.12 b	31.11±4.01 c	68.14±4.05 b	13.11±1.53 b
Nicotine 0.50 + Royal Jelly	43.25±3.80 a	49.34±5.88 a	98.38±10.82 a	16.36±0.81 a
Nicotine 1.00 + Royal Jelly	42.22±5.28 a	46.66±4.30 a,b	97.77±5.96 a	16.37±1.44 a

Non-similar letters in each column indicate a significant difference (p < 0.05)

Table 4. Comparison of the mean morphometric parameters of seminiferous tubules in different experimental groups

Groups	Diameter of seminiferous tubules	Thickness of the germinal epithelium
	Micrometer (Mean±SD)	micrometer (Mean±SD)
Royal jelly	150.02±3.87 a	38.93±3.65 a
Nicotine 0.50	153.58±5.06 a	39.03±4.76 a
Nicotine 1.00	126.88±4.91 b	26.29±2.88 b
Nicotine 0.50 + Royal Jelly	60.44±6.44 b	22.44±2.70 b
Nicotine 1.00 + Royal Jelly	144.42±5.48 a	38.31±3.96 a
Royal jelly	137.84±5.16 a	38.18±4.28 a

Non-similar letters in each column indicate a significant difference (p < 0.05)

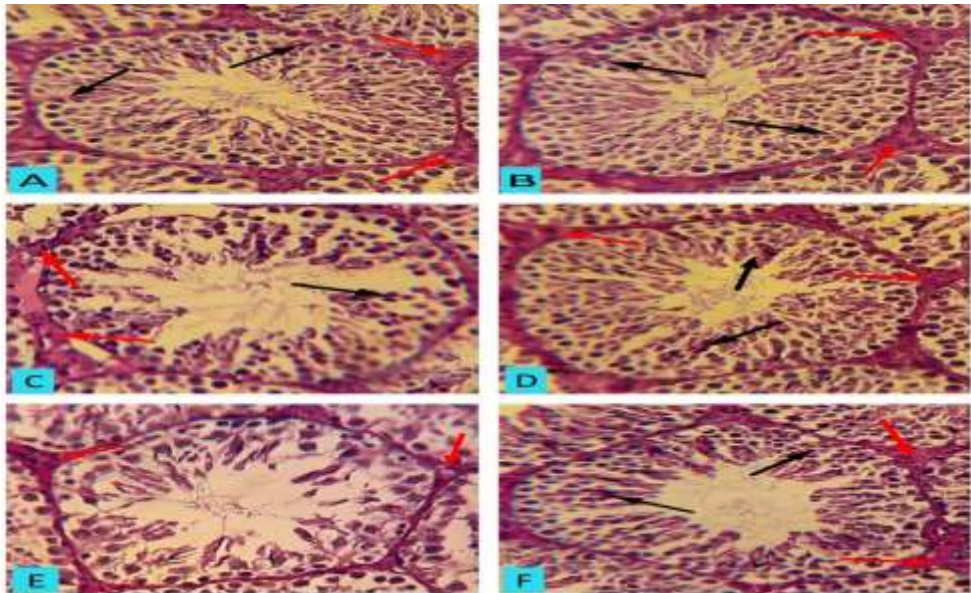


Figure 5. Cross section of testicular tissue in control groups (A), royal jelly (B), nicotine 0.50 (C), nicotine 0.50 + royal jelly (D), nicotine 1 (E), and nicotine 1 + royal jelly (F). In groups A and B, the organization of the seminiferous tubules and the spermatogenesis process are normal, and PAS-positive granules are observed in Leydig cells (red arrows) and germinal epithelium (black arrows). In groups C and E, seminiferous tubules have lost their normal structure and the spermatogenesis process has been impaired. In addition, PAS-positive reaction in germinal epithelium of the seminiferous tubules of group C decreased significantly, and in group E, PAS-positive granules were not observed in germinal epithelium and decreased significantly in Leydig cells. Improvement was observed in the structure of seminiferous tubules and the spermatogenesis process in groups D and F. PAS-positive reactions also increased in Leydig cells in these groups and PAS-positive reactions were observed in the germinal epithelium similar to the control group (PAS staining, 600X magnification).

Discussion

In this study, royal jelly administration in animals treated with both doses of nicotine improved testicular damage and sperm abnormalities compared to mice receiving nicotine alone. The results of this study showed that there was a significant decrease in the weight of nicotine-receiving mice, which was consistent with previous studies on laboratory animals regarding the role of nicotine in reducing body weight (24). It seems that nicotine reduces body weight due to its inhibitory role in food intake, inhibition of protein synthesis, and reduction of protein and lipid mass (25). Furthermore, the results of this study showed that nicotine administration decreases testicular weight, which is an important indicator for evaluation of reproductive toxicity in male animals. Examinations in this study showed that nicotine in both doses reduced the quality and quantity of epididymal sperm.

The present study, consistent with previous studies (26, 27), showed that nicotine significantly reduced the sperm count per milliliter and significantly increased the dead, and non-motile sperm and sperm with abnormal morphology. Nicotine can increase the death of sperm by reducing and damaging Leydig and Sertoli cells, which contribute to secretion of testosterone and the conversion of spermatogonial cells into sperm cells (28). Cigarette smoke also consists of harmful substances such as nicotine, and previous reports have also shown that cigarette increases morphological abnormalities and apoptotic changes in epididymal sperm (29).

In the present study, the number of spermatogenic cells of testicular tissue in nicotine – treated mice showed a significant decrease in the number of germ cells (spermatogonia, spermatocyte and spermatid) as well as the number of Sertoli cells, which was consistent with previous studies in this field (9, 30). Studies in this regard have also shown that administration of nicotine in mice is associated with a reduction in the number of spermatogenesis cells and impairment in the process of germ cell proliferation, which also confirms the findings regarding evaluation of spermatogenesis in this study (7). Consistent with the results of the present study, previous reports have also shown that nicotine decreases the diameter of seminiferous tubules and the thickness of the germinal

epithelium, and increases the space of the internal cavity of the seminiferous tubules by decreasing the population of testicular germ cells (31).

Carbohydrates, particularly glucose, are the main source of energy in the division of mitotic cells, and the blood-testis barrier is the main route of transfer of glucose into testicular seminiferous tubules (32). Testicular germ cells also use lactate as an energy source that is responsible for stimulating protein and RNA synthesis (33). In this study, the germinal epithelium of the seminiferous tubules in groups receiving nicotine showed a poor reaction to PAS staining, which may indicate impairment in glucose transfer (35).

The results of this study also showed that royal jelly can play a significant protective role as an antioxidant against the toxic effects of nicotine in the reproductive system. Previous reports also indicated the significant protective effect of this substance against reproductive disorders caused by bleomycin in male mice and also the oxidative damage caused by oxymetholone in the testicular tissue of mice (35, 36). Consistent with these findings, recent studies have also shown that royal jelly can improve the complications of diabetes in testicles of mice due to its significant antioxidant activity (37).

Based on the results of this study, it was found that nicotine causes testicular tissue damage, decreases the quantity and quality of sperm, and disrupts the metabolic cycle of carbohydrates in the testicular tissue of mice, while royal jelly, as a potential antioxidant, is able to improve testicular damage and sperm abnormalities in nicotine-induced reproductive toxicity in mice.

Conflict of Interest: No conflicts of interest.

Acknowledgment

This article is the result of master's degree in histology and embryology at Urmia University. Hereby, we express our deepest sense of gratitude and indebtedness to the Expert of Laboratory of Histology and Embryology, Faculty of Veterinary Medicine, Dr. Ali Karimi, and all those who helped in this study.

References

1. Mostafa T. Cigarette smoking and male infertility. *J Adv Res.* 2010;1(3):179-86.
2. Camlin NJ, McLaughlin EA, Holt JE. Through the smoke: use of in vivo and in vitro cigarette smoking models to elucidate its effect on female fertility. *Toxicol Appl Pharmacol.* 2014;281(3):266-75.
3. Kavitharaj NK, Vijiyammal PI. Nicotine administration induced changes in the gonadal function in male rats. *Pharmacol.* 1999;58(1):2-7.
4. Erat M, Ciftci M, Gumustekin K, Gul M. Effects of nicotine and vitamin E on glutathione reductase activity in some rat tissues in vivo and in vitro. *Eur J Pharmacol.* 2007;554(2):92-7.
5. Elshaari FA, Fatum AE, Sherif DS. Spermatozoa-a unique representation of oxygen-antioxidant paradox. *Acta Med Median.* 2010;49(1):48-53.
6. Reddy S, Londonkar R, Reddy SO, Patil SB. Testicular changes due to graded doses of nicotine in albino mice. *Indian J Physiol Pharmacol.* 1998;42(2):276-80.
7. Khajeh Jahromi S, Mohammadghasemi F, Hajizadeh Fallah H. Evaluation of proliferative activity of adult mouse male germ cells following administration of different doses of nicotine. *J Iran Anat Sci.* 2011;9(36):229-40.
8. Tutka P, Mosiewicz J, Wielosz M. Pharmacokinetics and metabolism of nicotine. *Pharmacol Rep.* 2005;57(2):143-53.
9. Nesseim WH, Haroun HS, Mostafa E, Youakim MF, Mostafa T. Effect of nicotine on spermatogenesis in adult albino rats. *Andrologia.* 2011;43(6):398-404.
10. Arabi M. Nicotinic infertility: assessing DNA and plasma membrane integrity of human spermatozoa. *Andrologia.* 2004;36(5):305-10.
11. Aydos K, Guven MC, Can B, Ergun A. Nicotine toxicity to the ultrastructure of the testis in rats. *Bob J Univ Int.* 2001;88(6):622-6.
12. Ahmadnia H, Ghanbari M, Moradi MR, Khaje-Dalouee M. Effect of cigarette smoke on spermatogenesis in rats. *Urol J.* 2007;4(3):159-63.
13. Khosh AH, Hasanzadeh S, Jalali AS. Ameliorative effects of *Achillea millefolium* inflorescences alcoholic extract on nicotine-induced reproductive toxicity in male rat: Apoptotic and biochemical evidences. *Vet Res Forum.* 2017;8(2):97-104.
14. Ramadan MF, Al-Ghamdi A. Bioactive compounds and health-promoting properties of royal jelly: A review. *J Funct Foods.* 2012;4(1):39-52.
15. Khazaei M, Ansarian A, Ghanbari E. New findings on biological actions and clinical applications of royal jelly: a review. *J Diet Suppl.* 2017;13:1-19.
16. Arzi A, Houshmand G, Goudarzi M, Khadem Haghighian H, Rashidi Nooshabadi M. Comparison of the analgesic effects of royal jelly with morphine and aspirin in rats using the formalin. *J Babol Univ Med Sci.* 2015;17(2):50-6. [In Persian].
17. Anbara H, Shahrooz R, Malekinejad H, Saadati S. Protective effects of royal jelly and vitamin c against experimental hemolytic anemia on sex hormones and histochemical testicle tissue histochemistry of adult mice. *J Shahid Sadoughi Univ Med Sci.* 2016;23(12):1140-54. [In Persian]
18. Yang A, Zhou M, Zhang L, Xie G, Chen H, Liu Z, et al. Influence of royal jelly on the reproductive function of puberty male rats. *Food Chem Toxicol.* 2012;50(6):1834-40.
19. Babaei M, Najafi G, Shalazar Jalali A, Behfar M. Effects of unilateral iatrogenic vas deferens trauma on fertility: an experimental in vitro fertilization mice model study. *Bull Emerg Trauma.* 2015;3(4):122-7.
20. Ghanbari E, Khazaei M, Yousefzadeh F. The restorative effect of *Prosopis farcta* on fertility parameters and antioxidant status in diabetic rats. *J Babol Univ Med Sci.* 2017;19(5):53-60. [In Persian]
21. Oakberg EF. A description of spermiogenesis in the mouse and its use in analysis of the cycle of the seminiferous epithelium and germ cell renewal. *Am J Anat.* 1956;99(3):391-413.
22. Johnsen SG. Testicular biopsy score count--a method for registration of spermatogenesis in human testes: normal values and results in 335 hypogonadal males. *Hormones.* 1970;1(1):2-25.
23. Humason GL. Animal tissue techniques. San Francisco: WH Freeman. 1962.

- 24.Oyeyipo IP, Raji Y, Emikpe BO, Bolarinwa AF. Effects of oral administration of nicotine on organ weight, serum testosterone level and testicular histology in adult male rats. *Niger J Physiol Sci.* 2010;25(1):81-6.
- 25.Guan G, Kramer SF, Bellinger LL, Wellman PJ, Kramer PR. Intermittent nicotine administration modulates food intake in rats by acting on nicotine receptors localized to the brainstem. *Life Sci.* 2004;74(22):2725-37.
- 26.Oyeyipo IP, Raji Y, Emikpe BO, Bolarinwa AF. Effects of nicotine on sperm characteristics and fertility profile in adult male rats: a possible role of cessation. *J Reprod Infertil.* 2011;12(3):201-7.
- 27.Oyeyipo IP, Maartens PJ, Plessis SS. In vitro effects of nicotine on human spermatozoa. *Andrologia.* 2014;46(8):887-92.
- 28.Kim KH, Joo KJ, Park HJ, Kwon CH, Jang MH, Kim CJ. Nicotine induces apoptosis in TM3 mouse Leydig cells. *Fertil Steril.* 2005;83(1):1093-9.
- 29.La Maestra S, De Flora S, Micale RT. Effect of cigarette smoke on DNA damage, oxidative stress, and morphological alterations in mouse testis and spermatozoa. *Int J Hyg Environ Health.* 2015;218(1):117-22.
- 30.Seema P, Swathy SS, Indira M. Protective effect of selenium on nicotine-induced testicular toxicity in rats. *Biol. Biol Trace Elem Res.* 2007;120(1-3):212-8.
- 31.Audi SS, Abraham ME, Borker AS. Effect of cigarette smoke on body weight, food intake and reproductive organs in adult albino rats. *Indian J Exp Biol.* 2006;44(7):562.
- 32.Farooqi I, O'Rahilly S. Monogenic human obesity syndromes. *Recent Prog Horm Res.* 2004;59:409-24.
- 33.Rato L, Alves MG, Socorro S, Duarte AI, Cavaco JE, Oliveira PF. Metabolic regulation is important for spermatogenesis. *Nat Rev Urol.* 2012;9(6):330-8.
- 34.Binsawad HAS, Hanadi AHM, Kelany, Fatma M, Hanan A, Salah A. The possible protective role of antioxidants (selenium, vitamin E) in reducing smoking effects on testes of albino rats. *Ass Univ Bull Environ Res.* 2011;14(1):61-76.
- 35.Amirshahi T, Najafi G, Nejati V. Protective effect of royal jelly on fertility and biochemical parameters in bleomycin-induced male rats. *Iran J Reprod Med.* 2014;12(3):209-16. [In Persian]
36. Najafi G, Nejati V, Jalali AS, Zahmatkesh E. Protective role of royal jelly in oxymetholone-induced oxidative injury in mouse testis. *Iran J Toxicol.* 2014;8(25):1073-80. [In Persian]
- 37.Ghanbari E, Nejati V, Khazaei M. Antioxidant and protective effects of royal jelly on histopathological changes in testis of diabetic rats. *Int J Reprod Biomed.* 2016;14(8):519-26.