

## Paget'S Disease of Bone; A Case Report

N. Meftah (MD)<sup>1</sup>, S.Yadsar (MD)<sup>2</sup>, M. Bahrami (MD)<sup>3</sup>, M. Saber (MD)<sup>4</sup>, S. Siadati (MD)<sup>\*5</sup>

1.Department of Internal Medicine, Babol University of Medical Sciences, Babol, I.R Iran

2.Department of Cardiology, Babol University of Medical Sciences, Babol, I.R Iran

3.Department of Orthopedic, Babol University of Medical Sciences, Babol, I.R Iran

4.Department of Radiology, Babol University of Medical Sciences, Babol, I.R Iran

5.Department of Pathology, Babol University of Medical Sciences, Babol, I.R Iran

---

J Babol Univ Med Sci; 18(2); Feb 2016; PP:69-72

Received: Aug 19<sup>th</sup> 2015, Revised: Sep 28<sup>th</sup> 2015, Accepted: Dec 28<sup>th</sup> 2015.

### ABSTRACT

**BACKGROUND AND OBJECTIVE:** Paget's disease is a progressive skeletal disorder, which involves the gradual destruction of the bones. Regarding the low prevalence of this disease in Iran, this study aimed to present a case of Paget's disease in an asymptomatic patient.

**CASE REPORT:** A 44-year-old male patient with elevated alkaline phosphatase (ALP) level in yearly examinations was referred to an internal medicine clinic. Considering the normal results of other examinations, high ALP level was found to be of an osseous origin. However, no bone deformity was detected in the patient. Bone scan and simple radiography were indicative of Paget's disease considering the high osteoblastic activity in the right hip and right sides of T<sub>1</sub> and L<sub>3</sub> segments. Diagnosis of Paget's disease was confirmed by bone biopsy. The patient was initiated on oral alendronate (35 mg daily) for six months. Following this period, ALP level reduced, and the treatment is still in progress.

**CONCLUSION:** According to the results of this study, although Paget's disease is a skeletal disorder, it could remain asymptomatic and occur without any deformities.

**KEY WORDS:** *Paget's disease, Deformity, Osteoblastic.*

---

### Please cite this article as follows:

Meftah N, Yadsar S, Bahrami M, Saber M, Siadati S. Paget'S Disease of Bone; A Case Report. J Babol Univ Med Sci. 2016;18(2):69-72.

---

\*Corresponding Author: S. Siadati (MD)

Address: Department of Pathology, Shahid Beheshti Hospital, Babol University of Medical Sciences, Babol, I.R. Iran

Tel: +98 11 32255291

E-mail: siadati\_sepideh@yahoo.com

## Introduction

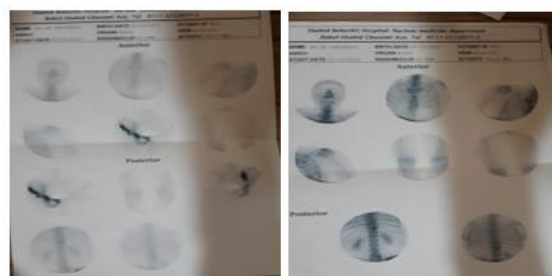
**P**aget's disease is a bone disorder, which affects extensive skeletal regions and is highly prevalent in European countries (1,2). In Paget's disease, osteoclasts cause bone resorption increasing the formation of thick, fragile bones, which are highly susceptible to deformity and fractures (1,3).

Through the course of Paget's disease, various symptoms emerge from the primary, secondary and following compression of the nerve tissues (1,2,4). Multiple bone involvement leads to frequent fractures, increased head circumference, blindness and deafness, foot clubbing, kyphosis, and heart failure (5). Paget's disease may inflict one single bone (25% of the cases) or multiple bones (75% of the cases) (6). Hips, spine, femur and tibia, and lumbosacral region are most commonly affected by this disorder (7). In one study, Karabas et al. described a 57-year-old female patient with maxillary swelling, and X-ray radiography confirmed Paget's disease (8). In another report, Garg et al. presented a 59-year-old male patient with mandibular osteomyelitis, who was diagnosed with Paget's disease after radiographic examination (9). Male-to-female ratio in Paget's disease is 2:1, and 90-95% of the patients are aged over 40 years (5, 10). According to previous studies, the mean age of patients with Paget's disease at diagnosis is 68.7 years (11). Considering the low prevalence of Paget's disease in Iran, we described a 44-year-old male patient diagnosed with Paget's disease due to elevated level of alkaline phosphatase (ALP) in yearly examinations. This study aimed to emphasize the fact that different diseases may manifest through various unspecific forms and symptoms. Therefore, we attempted to investigate all the aspects and symptoms of Paget's disease.

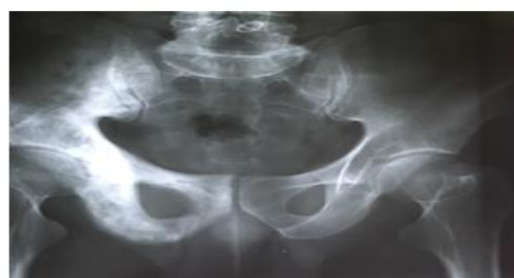## Case Report

A 44-year-old male patient was referred to an internal medicine clinic for routine check-up with high ALP level as detected by yearly examinations (954, normal maximum: 280). After obtaining informed consent, the patient was enrolled in this experiment. The patient had no medical history of abdominal and bone pain, jaundice, itching, cardiac disease and medication use. In addition, the systemic examination was normal, and no bone deformity was observed. Also, blood cell count, liver enzymes, thyroid and kidney function, and blood glucose tests were normal.

To determine the cause of high ALP level, the gamma-glutamyl transferase test was performed, which yielded normal results. Liver and biliary tract ultrasound tests were normal as well. Since liver disease and bile duct are not associated with Paget's disease, and other tests were normal in our patient, elevated ALP level was considered to be of an osseous origin. According to other examinations, concentrations of calcium, phosphorus, parathyroid hormone (PTH) and vitamin D were normal. Consequently, possibilities of hyperparathyroidism and osteomalacia were ruled out. In the next stage, bone scan was performed on the patient, and due to increased osteoblastic activity in the right hip and right sides of T<sub>1</sub> and L<sub>3</sub> segments, the possibility of Paget's disease was speculated (fig 1). As requested by the radiologist, simple radiographs were obtained from these regions, which were also indicative of Paget's disease (fig 2).




**Figure 1. Increased Osteoblastic Activity in the Right Hip (slightly higher than the activity in the right sides of T<sub>1</sub> and L<sub>3</sub> segments)**



**Figure 2. Increased Cortical Bone Thickness and Sharp Trabecular Pattern due to Bone Resorption and Sclerosis**

Moreover, complementary examination revealed a mild auditory acuity, which had been neglected by the patient. In addition, radiometric examination of the patient was indicative of sensorineural hearing loss, which was assumed to be caused by Paget's disease. To obtain a definitive diagnosis and rule out other hypotheses, pelvic bone biopsy was carried out, and

the sample was sent for pathological examination. Paget's disease was confirmed through observing dense bone blades with mosaic patterns in the microscopic examination (fig 3). Treatment of the patient included oral alendronate administration (35 mg daily) for six months. After this period, ALP level reduced, and the treatment is still in progress.



**Figure 3. View of Dense Bone Blade at 40× Magnification (Haematoxylin and Eosin Stain)**

## Discussion

Bone deformity is the main feature of Paget's disease, which was not detected in our patient. With the exception of increased ALP level, the patient had no other symptoms of Paget's disease. Paget's disease affects diverse ethnic groups and is highly prevalent among Caucasians, while it is less prevalent among indigenous Asians (1, 3, 4). In countries with high prevalence of Paget's disease, the majority of patients are aged over 55 years (12). Histopathologically, the first stage of Paget's disease involves the lytic cycle, in which the lysis index is evident (13). Most symptoms of Paget's disease appear in the final stage, also known as the sclerotic stage, in which the sclerosing bone replaces the natural bone (14).

Consequently, patients often manifest facial deformities and increased skeletal volume, such as mandibular and maxillary hypertrophy (15). In one study, Khajavi et al. described a 17-year-old patient initially presented with progressive visual acuity in the left eye within the past two years. Visual acuity

decreased in the right eye, and although the bone density had increased in that region, it was softer than expected. Bone samples were sent for pathological examination, and typical mosaic pattern of the samples confirmed the diagnosis of Paget's disease (16). In another report, Eghbali et al. described a 38-year-old patient who had referred for dental extraction since two years before. Significant facial deformity correspondent to leontiasis ossea was detected in the patient, and laboratory results were indicative of elevated ALP and PTH levels (17). In the aforementioned studies, both patients showed symptoms of Paget's disease, none of which were observed in our patient. The only symptom associated with Paget's disease in our patient was increased ALP level. According to international studies, Paget's disease more commonly affects men compared to women, and this finding has been confirmed in the Asian population (13). Furthermore, Paget's disease has the highest prevalence among elderly patients (18). According to some studies, the age at onset of Paget's disease is above 40 years, while other studies have suggested a median age of 68.7 years for this disorder (15, 19). On the other hand, few studies have reported the onset of Paget's disease at younger ages. This could be due to the fact that in some cases, Paget's disease remains asymptomatic and is identified through the sudden elevation of ALP levels (14). In conclusion, although Paget's disease is a skeletal disorder, it may remain asymptomatic and manifest without any bone deformities. Therefore, it is recommended that individuals aged over 40 years with high ALP levels be monitored for Paget's disease.

## Acknowledgments

This article was extracted from a student's thesis conducted at Babol University of Medical Sciences. Hereby, we extend our gratitude to the personnel of the Pathology Department and medical archives of Shahid Beheshti Hospital for assisting us in this research project.

## References

1. Galson DL, Roodman GD. Pathobiology of Paget's disease of bone. *J Bone Metab.* 2014;21(2):85-98.
2. Bolland M, Cundy T. Republished: Paget's disease of bone: clinical review and update. *Postgrad Med J.* 2014;90(1064):328-31.
3. Baltag D, Galesanu MR, Popescu CD, Iacob C. [The clinical, imaging and electrophysiological correlations in Paget's disease]. *Rev Med Chir Soc Med Nat Iasi.* 1998;102(3-4):188-93.
4. Saura R. [Paget's disease of bone]. *Clin Calcium.* 2007;17(11):1769-72.
5. Jaffe H. Metabolic, degenerative and inflammatory diseases of bones and joints. Philadelphia: Lee & febiger. 1972.p.1016.
6. Imbuldeniya AM, Tai SM, Aboelmagd T, Walter WL, Walter WK, Zicat BA. Cementless hip arthroplasty in paget's disease at long-term follow-up (average of 12.3 years). *J Arthroplasty.* 2014;29(5):1063-6.
7. Parvizi J. Surgical manifestations of pagets disease(review article). *Tehran Univ Med J.* 2006;64(8):1-13.[In Persian]
8. Cakir Karabas H, Kose TE, Hatipoglu E, Dincer O, Erdem TL, Ozcan İ. Paget's disease of maxilla: A case report. *Indian J Dentist.* 2013;4(4):229-32.
9. Garg K, Devi P, Thimmarasa VB, Mehrotra V. Osteomyelitis of the mandible as a complicating factor in paget's disease: A case report. *Indian J Dentist.* 2012;3(2):110-7.
10. Hsu LN, Shen YC, Chen CH, Sung MT, Chiang PH. Extramammary Paget's disease with invasive adenocarcinoma of the penoscrotum: Case report and systematic review. *Urolog Sci.* 2013;24(1):30-3.
11. Walsh JP, Attewell R, Stuckey BGA, Hooper MJ, Wark JD, Fletcher S, et al. Treatment of Paget's disease of bone: A survey of clinical practice in Australia. *Bone.* 2008;42(6):1219-25.
12. Codreanu I, Lim E, Dasanu CA. Monostotic Paget's disease involving the calcaneus encountered incidentally on bone scintigraphy. *Foot.* 2012;22(3):135-7.
13. Li YC, Lu LY, Yang YT, Chang CC, Chen LM. Extramammary Paget's disease of the scrotum associated with hepatocellular carcinoma. *J Chin Med Assoc.* 2009;72(10):542-6.
14. Hammami B, Chakroun A, Achour I, Charfeddine I, Chakroun A, Ben Mahfoudh K, et al. Paget's disease in association with undifferentiated nasopharyngeal carcinoma. *Egypt J Ear, Nose, Throat Alli Sci.* 2011;12(2):125-8.
15. Juang GD, Lin MY, Hwang TIS. Extramammary Paget's disease of the scrotum. *J Chin Med Assoc.* 2011; 74(7):325-8.
16. Khajavi M, Habibi M. Paget's disease of bone with bilateral optic. *Res Med.* 2001;25(4):271-3.
17. Aghbali AA, Dalir Sani Z. Case report: a case of Paget 's disease in a young woman. *Med J of Tabriz Univ of Med Sci.* 2009;30(4):97-100.[In Persian]
18. Zhang N, Gong K, Zhang X, Yang Y, Na Y. Extramammary Paget's disease of scrotum-report of 25 cases and literature review. *Urol Oncol.* 2010;28(1):28-33.
19. Mangham DC, Davie MW, Grimer RJ. Sarcoma arising in Paget's disease of bone: Declining incidence and increasing age at presentation. *Bone.* 2009;44(3):431-6.