

## Evaluation of the Audiological Characteristics of Patients with Otosclerosis Referring to the Ear, Nose, and Throat Clinics of Babol City, Iran

K. Kiakojori (MD)<sup>\*1</sup>, M. Monadi (MSc)<sup>2</sup>, A. Khodadoost (GP)<sup>3</sup>, S. Soltanparast (MSc)<sup>4</sup>,  
M. Sheikhzadeh (PhD)<sup>2</sup>, S. Khafri (PhD)<sup>5</sup>

1.Department of ENT, Babol University of Medical Sciences, Babol, I.R.Iran

2.Department of Audiology, Babol University of Medical Sciences, Babol, I.R.Iran

3.University of Medical Sciences, Babol, I.R.Iran

4.Department of Audiology, Babol University of Medical Sciences, Babol, I.R.Iran

5.Department of Biostatistics, Faculty of Medicine, Babol University of Medical Sciences, Babol, I.R.Iran

J Babol Univ Med Sci; 18(4); Apr 2016; PP: 67-72

Received: Jun 25<sup>th</sup> 2015, Revised: Sep 28<sup>th</sup> 2015, Accepted: Jan 6<sup>th</sup> 2016.

### ABSTRACT

**BACKGROUND AND OBJECTIVE:** Otosclerosis is the most common disorder of the bony labyrinth and stapes only affecting humans. Otosclerosis is considered a major cause of acquired hearing loss. This study aimed to evaluate the audiological characteristics of patients with otosclerosis referring to the Ear, Nose, and Throat (ENT) clinics of Babol city, Iran.

**METHODS:** This cross-sectional study was conducted on all the patients with otosclerosis within the age range of 20-67 years referring to ENT clinics of Babol city in Iran. Demographic characteristics and clinical symptoms, including tinnitus, hearing loss, and hearing at different frequencies, were recorded and evaluated for each patient.

**FINDINGS:** In total, 60 patients with otosclerosis were enrolled in this study, including 17 males and 43 females. Mean age of the participants was 42.78±1.4 years. According to our findings, 54.2% of the studied patients had mixed hearing loss, and 70% had tinnitus. Moreover, the Schwartz sign was observed to be negative in all the patients.

**CONCLUSION:** According to the results of this study, gender and some audiological characteristics of patients were associated with the risk of otosclerosis.

**KEY WORDS:** *Otosclerosis, Audiometry, Hearing loss, Schwartz sign, Air-bone gap.*

### Please cite this article as follows:

Kiakojori K, Monadi M, Khodadoost A, Soltanparast S, Sheikhzadeh M, Khafri S. Evaluation of the Audiological Characteristics of Patients with Otosclerosis Referring to the Ear, Nose, and Throat Clinics of Babol City, Iran. J Babol Univ Med Sci. 2016;18(4):67-72.

\*Corresponding author: M. Monadi (MSc)

Address: Department of Audiology, Rehabilitation Faculty of Medical, Babol University of Medical Sciences & Health Services, Babol, I.R.Iran

Tel: +98 11 32194641

Email: monadi.mohsen@yahoo.com

## Introduction

Otosclerosis is the most common disorder of the bony labyrinth and stapes, which only affects humans (1) and is considered a major cause of acquired hearing loss (2). Although Asia has been shown to be the origin of 5-9% of the cases with hearing loss, the prevalence rate of otosclerosis is estimated at less than 1% in this continent (3). This disorder normally manifests in individuals aged 20-40 years, and approximately 90% of the patients are aged less than 50 years at the time of diagnosis (4). The exact mechanism of otosclerosis remains unknown; however, the pathophysiology of this disorder has been associated with the autoimmune system and viral infections (5). According to some researchers, otosclerosis is unlikely to occur outside the temporal bone (1). This disorder involves the entire otic capsule; meanwhile, the most common locations affected by otosclerosis have been reported to be the anterior oval window, round window niche, and the apical and medial parts of the cochlear wall (1).

Otosclerosis could lead to endolymphatic hydrops, chemical imbalance of the liquid-ion recovery cycle, obstruction of the endolymphatic duct and sac, and biochemical changes. In addition, otosclerosis lesions might engage the facial nerve regions, as well as the articular or spiral areas, giving rise to neurotic degeneration (1). Diagnosis of otosclerosis is based on the evaluation of medical history, medical examinations, and performing related tests, such as pure-tone audiometry and immittance analysis (6). Audiological findings are not sufficient for the accurate diagnosis of otosclerosis (7). Nevertheless, evaluation of the audiological and clinical characteristics of patients with otosclerosis is considered imperative for several reasons. First, despite the fact that otosclerosis is a relatively rare disorder, it has been shown to be the main cause of hearing impairment in patients with normal tympanic membrane (8).

Furthermore, if otosclerosis remains untreated, it could lead to the total hearing loss of the patient (9). Hearing impairment is one of the main clinical symptoms regarded as a diagnostic indicator of otosclerosis (10). While this disorder mainly leads to conductive hearing loss (10), previous studies have reported that conductive hearing loss could be accompanied by impaired sensorineural hearing or sensorineural hearing loss alone (11). Based on the aforementioned findings, further investigation of the

audiological characteristics seems essential in designating new approaches for the early and accurate diagnosis of otosclerosis. This study aimed to evaluate the audiological characteristics of patients with otosclerosis.

## Methods

This cross-sectional study was conducted on all the patients referring to the Ear, Nose, and Throat (ENT) clinics affiliated to Babol University of Medical Sciences during 2012-2013 in Babol city, Iran. Initially, demographic characteristics of the patients were recorded, including the age, gender, family history of hearing loss, and gestational history (in females). Moreover, clinical symptoms of the patients were collected, such as the onset of symptoms, tinnitus, and hearing impairment.

Afterwards, otoscopic examination was carried out in order to evaluate the ear canal in terms of earwax, status of the eardrum, and Schwartz sign. Following that, hearing of the patients was assessed using pure-tone audiometry at the frequencies of 250, 1000, 500, 4000, 2000, and 8000 Hz. All the stages of patient evaluation were performed by a trained audiologist. Patients with confirmed diagnosis of otosclerosis by a fellowship trained otolaryngologist based on clinical signs and symptoms and audiometric findings were enrolled in this study. Data analysis was performed in SPSS V.18 using Pearson's correlation-coefficient, and P value of less than 0.05 was considered significant.

## Results

In total, 60 patients with otosclerosis, including 17 males and 43 females, with mean age of  $42.78 \pm 1.4$  years were enrolled and evaluated in this study (table 1). According to our findings, mixed hearing loss was the most prevalent type of hearing loss in both ears of the studied patients (fig 1).

Moreover, audiological findings indicated that six patients (10%) were diagnosed with unilateral otosclerosis, while other patients were reported to have bilateral otosclerosis. Among the studied subjects, the Carhart notch was detected in one of the ears of 23 patients (38.3%).

In addition, the highest degree of hearing loss in the Eustachian tube and bony channel of both ears was observed at the frequencies of 8000 and 2000 Hz, respectively, while the lowest level of hearing loss in

these two areas were detected at the frequencies of 2000 and 250 Hz, respectively (fig 2). In this study, an ascending gap was observed in the Eustachian tube of the right ear of 44% (n=26) and left ear of 37% patients (n=22) at the frequency of 2000 Hz. Mean of

air-bone gap (ABG) was highest in both ears at the frequency of 250 Hz. On the other hand, ABG reduced on higher frequencies, with the exception of 2000 Hz, in which an ascending notch was observed in the Eustachian tube of the ear (fig 3).

Table 1. Demographic characteristics and otoscopic examination of patients with otosclerosis

Variable	Total n=60	Male n=17	Female n=43
Age (year)	42.8±10.5	45.7±11.6	41.6±1
Gestational History N(%)	38(88.3)	-	38(88.3)
Hearing Loss during Pregnancy N(%)	12(32.4)	-	12(32.4)
Onset of Symptoms (Mean±SD)	88.3±3.89	100.9±4.109	82.8±4.81
Tinnitus N(%)	42(70)	11(67.7)	31(72.1)
Schwartz Sign N(%)	0(0)	0(0)	0(0)

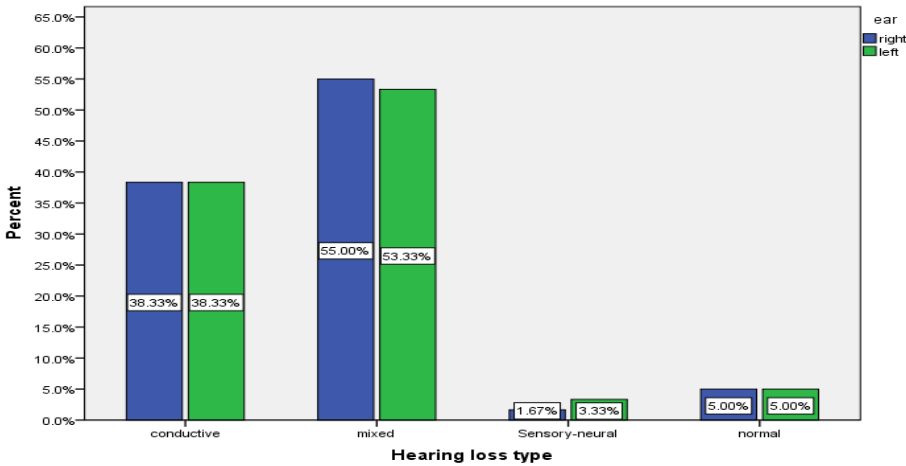


Figure 1. Frequency of different types of hearing loss in patients with otosclerosis (n=60)

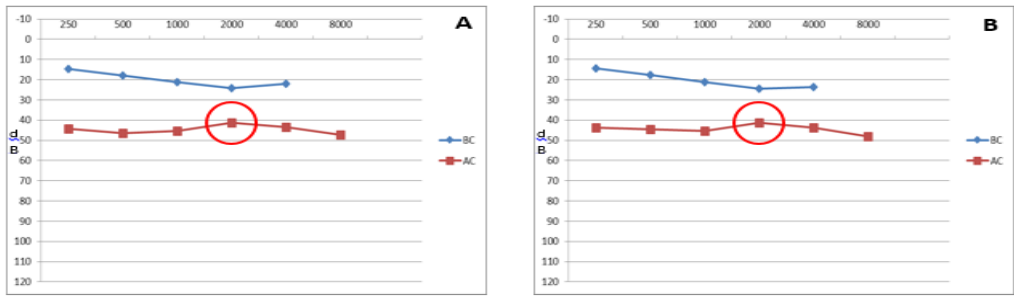


Figure 2. Results of pure-tone audiometry in patients with otosclerosis (n=60)

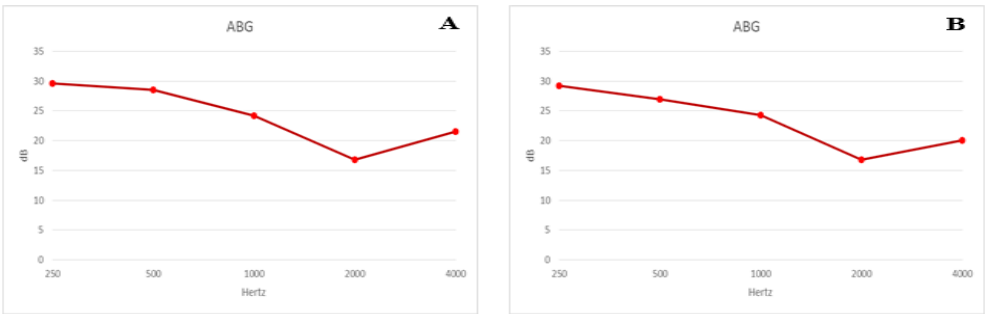


Figure 3. Mean of air-bone gap in two ears of patients with otosclerosis (n=60)

## Discussion

In the present study, the main cause of referrals to the ENT clinics (n=58, 96.7%) was hearing loss, and mixed hearing loss had the highest prevalence. These findings are inconsistent with the results obtained by Zhao et al. and Mohammadi et al. (12, 13). In the study by Zhao et al., all the evaluated patients (n=25) were diagnosed with progressive conductive hearing loss (12). In the research by Mohammadi et al., 25 out of 30 patients were diagnosed with conductive hearing loss, and only five cases were reported to have mixed hearing loss (13). Differences in the results of the aforementioned studies could be due to variations in the age, as well as the long duration of the disorder in patients evaluated in the current study. Furthermore, otoscopic examination revealed the Schwartz sign (a reddish color) in some of the patients at the primary stages of otosclerosis (14). The Schwartz sign is indicative of the hyperemia of promontory, which is caused by the agglomeration of blood vessels underneath the bone (15) and is visible through the transparent tympanic membrane. In the present study, the Schwartz sign was observed in none of the patients. In part of their research, Gristwood et al. evaluated the relationship between the Schwartz sign and tinnitus in patients with otosclerosis reporting positive results in 36 patients (16).

Differences in the aforementioned findings could be due to the number of samples and referral of the studied patients at the progressive stages of the disorder. According to the results of the current study, the prevalence of otosclerosis was twice higher in women compared to men, which is in line with the findings of Topsakal et al., Sakahira et al., Gorden and Fraser et al., and Pearson et al. (17-21).

It is highly possible that this finding is associated with endocrine factors, as well as the levels of steroid hormones (22). With regard to the prevalence of otosclerosis in terms of gender, our findings were inconsistent with the results obtained by Ohtani et al. and Hueb et al. (23, 24). This difference could be due to the variations in the age of the patients, number of samples, gender, and type of otosclerosis (clinical or histological). The results of previous studies are indicative of the fact that the audio transferred to the skull is not conducted to the cochlea by the bony channel only (25), and the middle ear is involved in this process as well (26). Therefore, since in patients with otosclerosis, the middle ear is blocked to a certain extent due to the stabilization of the stapes, threshold

of the bony channel is likely to increase at some frequencies, with the maximum increase at the frequency of 2 kHz (26). In other words, reduction of bone conduction sensitivity, especially at the frequency of 2 kHz, is considered an audiological indicator of otosclerosis. This phenomenon is also referred to as the "Carhart notch", which in fact is an audiological artifact. This artifact is not representative of the damage of the sensory hair cells of the inner ear or cochlea sensitivity (4, 26).

Therefore, modification of the Carhart notch is possible through surgical interventions (26). In the present study, the Carhart notch was observed in a limited number of the evaluated otosclerotic ears. Inconsistent with our results, the findings of Yasan were indicative of the presence of this notch in a greater number of otosclerotic ears. Differences in these findings with the results of the current study could be due to the fact that all the patients in the study by Yasan were diagnosed with conductive hearing loss (25). Tinnitus is one of the most common symptoms of otosclerosis (4).

Patients with otosclerosis frequently have tinnitus at variable intensities in one or both ears and their head. In otosclerosis, tinnitus is normally associated with impaired hearing, and without treatment, it is likely that the patient suffer from these two disorders throughout life. The exact origin of tinnitus remains unknown, and its occurrence is not associated with the level of neuro-sensory sensitivity or conductive defects (16). In the present study, tinnitus was reported in 70% of the patients (n=42), which is in line with the findings of Griswood et al. (16). However, it was inconsistent with the results obtained by Mohammadi et al. (13). In the research by Griswood et al., the prevalence of tinnitus was estimated at 65%. In the current study, 90% of the patient (n=54) were diagnosed with bilateral otosclerosis, and only 10% (n=6) were diagnosed with unilateral otosclerosis. This finding is consistent with the results of the studies conducted by Hueb et al., Naderpour et al., and Mohammadi et al. (11, 13, 23).

In the current research, evaluation of the audiograms of the studied patients revealed an upward gap in the threshold of the Eustachian tube at the frequency of 2000 Hz. This upward gap, which was located next to the descending gap at the threshold of the bony channel at the frequency of 2000 Hz (i.e., Carhart notch), led to the appearance of a reversed configuration in the audiograms of the patients. Since

this shape was observed in a significant number of the studied patients, it is recommended that the scientific definition of this phenomenon be further speculated. In conclusion, the results of the present study indicated that it is of paramount importance to define a conclusive audiological framework for the early diagnosis of otosclerosis, close monitoring of the patients, and adopting the most effective therapeutic approaches (e.g., surgery or use of hearing aid). It is also noteworthy that the assessment of audiological and clinical characteristics may not necessarily result

in the accurate diagnosis of this disorder, and a definitive diagnosis could be obtained through comprehensive evaluations and imaging techniques, such as magnetic resonance imaging and CT-scan.

### Acknowledgments

Hereby, we extend our gratitude to the Deputy of Research and Technology at Babol University of Medical Sciences for the financial support of this research project.

## References

- 1.Cureoglu S, Schachern PA, Ferlito A, Rinaldo A, Tsuprun V, Paparella MM. Otosclerosis: etiopathogenesis and histopathology. *Am J Otolaryngol*. 2006; 27(5):334-40.
- 2.Stankovic KM, McKenna MJ. Current research in otosclerosis. *Curr Opin Otolaryngol Head Neck Surg*. 2006; 14(5): 347-51.
- 3.Declau F, Van Spaendonck M, Timmermans JP, Michaels L, Liang J, Qiu JP, et al. Prevalence of otosclerosis in an unselected series of temporal bones. *Otol Neurotol*. 2001; 22(5):596-602.
- 4.Thys M, Van Camp G. Genetics of otosclerosis. *Otol Neurotol*. 2009; 30(8):1021-32.
- 5.Karosi T, Sziklai I. Etiopathogenesis of otosclerosis. *Eur Arch Otorhinolaryngol*. 2010; 267(9):1337-49.
- 6.Salomone R, Riskalla PE, Vicente Ade O, Boccalini MC, Chaves AG, Lopes R, et al. Pediatric otosclerosis: case report and literature review. *Braz J Otorhinolaryngol*. 2008;74(2):303-6.
- 7.Wegner I, Bittermann AJ, Hentschel MA, van der Heijden GJ, Grolman W. Pure-tone audiometry in otosclerosis: insufficient evidence for the diagnostic value of the Carhart notch. *Otolaryngol Head Neck Surg*. 2013; 149(4):528-32.
- 8.Kolo ES, Ramalingam R. Hearing results in adults after stapedotomy. *Niger Med J*. 2013; 54(4):236-9.
- 9.Husban HA. Outcome of management of otosclerosis by stapedotomy compared to stapedectomy in a jordanian population. *Oman Med J*. 2013; 28(1):36-8.
- 10.Menger DJ, Tange RA. The etiology of otosclerosis: a review of the literature. *Clin Otolaryngol Allied Sci*. 2003; 28(2): 112-20.
- 11.Naderpour M; Doust Mohamadian N; Hatami B; Survey of the Results of Surgical Treatment of Otosclerosis. *Med J Tabriz Univ*. 2007; 29(1): 111-16. [In Persian]
- 12.Zhao F, Wada H, Koike T, Ohyama K, Kawase T, Stephens D. Middle ear dynamic characteristics in patients with otosclerosis. *Ear Hear*. 2002; 23(2):150-8.
- 13.Mohammadi G; Abedini A; Sayah Melli MR. The survey of the results of the exploratory tympanotomy in the patients suspected to otosclerosis. *Med J Tabriz Univ*. 2007;29(1):89-91.
- 14.Snow JB, Jr, and John Jacob Ballenger, BC Decker. *Ballengers, Otorhinolaryngology Head and Neck Surgery*. 16<sup>th</sup> ed. Canada: Hamilton Ontario; 2003.p.1616.
- 15.Brookler KH, Tanyeri H. Etidronate for the the neurotologic symptoms of otosclerosis: preliminary study. *Ear Nose Throat J*. 1997; 76(6):371-6.
- 16.Gristwood RE, Venables WN. Otosclerosis and chronic tinnitus. *Ann Otol Rhinol Laryngol*. 2003; 112(5):398-403.
- 17.Topsakal V, Fransen E, Schmerber S, Declau F, Yung M, Gordts F, et al. Audiometric analyses confirm a cochlear component, disproportional to age, in stapedia otosclerosis. *Otol Neurotol*. 2006; 27(6):781-7.
- 18.Sakihara Y, Parving A. Clinical otosclerosis, prevalence estimates and spontaneous progress. *Acta Otolaryngol*. 1999; 119(4):468-72.
- 19.Gordon MA. The genetics of otosclerosis: a review. *Am J Otol*. 1989; 10(6):426-38.
- 20.Fraser JS. President's Address: A National Investigation of Otosclerosis. *Proc R Soc Med*. 1928; 21(3):387-91.
- 21.Pearson RD, Kurland LT, Cody DT. Incidence of diagnosed clinical otosclerosis. *Arch Otolaryngol*. 1974; 99(4): 288-91.
- 22.Vartiainen E. Sex differences in patients with hearing impairments caused by otosclerosis. *Eur Arch Otorhinolaryngol*. 1999; 256(9): 431-3.
- 23.Hueb MM, Goycoolea MV, Paparella MM, Oliveira JA. Otosclerosis: the university of minnesota temporal bone collection. *Otolaryngol Head Neck Surg*. 1991;105(3):396-405.
- 24.Ohtani I, Baba Y, Suzuki T, Suzuki C, Kano M, Dekka RC. Why is otosclerosis of low prevalence in Japanese? *Otol Neurotol*. 2003;24(3):377-81.
- 25.Yasan H. Predictive role of Carhart's notch in pre-operative assessment for middle-ear surgery. *J Laryngol Otol*. 2007; 121(3):219-21.
- 26.Cureoglu S, Baylan MY, Paparella MM. Cochlear otosclerosis. *Curr Opin Otolaryngol Head Neck Surg*. 2010; 18(5): 357-62.