



Comparing the Effectiveness of Swing Door Uncinectomy versus Partial Uncinectomy in Middle Meatal Antrostomy

F. Mowaffak Hassan (MD)^{*1} , A. Abbas Shlaka (MD)² 

1.Department of Surgery, Faculty of Medicine, University of Kufa, Najaf, Iraq.

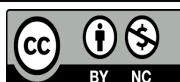
2.Al-Najaf Al-Ashraf Teaching Hospital, Al-Najaf Health Directorate, Najaf, Iraq.

*Corresponding Author: F. Mowaffak Hassan (MD)

Address: Department of Surgery, Faculty of Medicine, University of Kufa, Najaf, Iraq.

Tel: +964 (780) 1264732. E-mail: Firasm.hasan@uokufa.edu.iq

Article Type	ABSTRACT
Research Paper	<p>Background and Objective: A partial uncinectomy entails resection of the uncinate process's lower portion. Compared to swing door uncinectomy, partial uncinectomy has a reduced duration of operation, minimal mucosal hemorrhage, and less tissue damage. The aim of this study is to compare the effectiveness of swing-round uncinectomy technique versus partial uncinectomy in middle meatal antrostomy.</p> <p>Methods: This clinical trial was conducted on 28 patients who complained of local diseases of the maxillary sinus and bony obstruction unresponsive to conventional medical treatments and referred for endoscopic functional sinus surgery. 15 patients underwent swing door uncinectomy with MMA. This was performed by taking down the lower tow third of the vertical portion of the uncinate with backbiter while the horizontal portion was removed by submucosal dissection. In the remaining 13 patients, partial uncinectomy was performed by removing just the inferior vertical part of the uncinate using the backbiter and the horizontal portion was removed by submucosal dissection, and the treatment results were compared in two groups.</p> <p>Findings: A total of 28 patients were enrolled in this study. 11 were males and 17 were females, their age ranged from 11 to 50 years with a mean age of 25.58 ± 7.14. In postoperative follow up, it had been shown that partial uncinectomy technique results in shorter operation time, fast recovery, and less complications possibility compared to the swing door uncinectomy. The difference was statistically significant ($p < 0.05$).</p> <p>Conclusion: The results showed that the technique of partial uncinectomy can be of benefit in cases of isolated maxillary sinus disease. It provides short operation time, fast recovery, and a less complications possibility when compared with the swing door uncinectomy.</p> <p>Keywords: <i>Uncinectomy, Partial, Swing Door, Middle Meatal Antrostomy.</i></p>
Received: Jul 15 th 2023	
Revised: Nov 18 th 2023	
Accepted: Feb 27 th 2024	
<p>Cite this article: Mowaffak Hassan F, Abbas Shlaka A. Comparing the Effectiveness of Swing Door Uncinectomy versus Partial Uncinectomy in Middle Meatal Antrostomy. <i>Journal of Babol University of Medical Sciences</i>. 2024; 26: e42.</p>	



Introduction

The initial phase in middle meatal surgery is uncinectomy, which is considered indispensable for future surgical process (1). Excessive mucosal injury, intraoperative haemorrhage, or incomplete resection can cause the impaired endoscopic vision and difficulty continuing on to the next stage, resulting in a protracted surgical procedure with a poor clinical outcome. Several uncinectomy complications have been reported. Incomplete removal, mucosal injury and haemorrhage, damage to the lamina papyracea or the contents of the orbit, iatrogenic narrowing of the frontoethmoidal recess, nasolacrimal duct injury, and intranasal adhesion (2) are some of the complications that can occur. In a partial resection, the uncinate process's lower portion is excised. It is possible to attain a shorter procedure time, less mucosal haemorrhage, and less tissue injury compared to conventional methods. The partial uncinectomy is less likely to harm the lamina papyracea compared to the swing door technique (SDT) because it only removes a small part of the uncinate procedure. Moreover, partial resection can decrease the incidence of adhesions among the lateral nasal wall and middle turbinate (3). Blockage or constriction of the frontal recess is an uncommon complication of partial uncinate resection (4). When diseases are confined to the maxillary sinus, uncinectomy is recommended. Other sinus pathologies and disseminated polyposis are not indications for this process. Partial resection of the uncinate process guarantees ample access to the maxillary sinus and permits pathology to be removed through an enlarged natural aperture (5). This study was conducted to compare total uncinectomy (swing door) technique and partial uncinectomy on the patency of middle meatus after endoscopic sinus surgery.

Methods

This clinical and descriptive investigation was conducted between December 2017 and December 2018 in the Department of Otolaryngology-Head and Neck Surgery at Al-Sader medical in Najaf, Iraq under UK-MH-2020214. In this investigation, a total of 28 patients (15 men & 13 women) with localized maxillary sinus diseases and osteomeatal obstruction who did not respond to medical treatment were allotted functional endoscopic sinus surgery.

Inclusion criteria: Unilateral maxillary fungal ball, antrochoanal polyp, maxillary sinusitis, OMC obstruction.

Exclusion criteria: Sinonasal tumors, extensive polyposis, previous surgery, craniofacial anomalies, age<18.

All patient included in this study were subjected to detailed history and complete ENT examination including nasal endoscopic examination. Nose and paranasal sinuses CT-scan was done before surgery. Endoscopic sinus surgery (ESS) was done under general anesthesia. The nasal cavity mucosa was prepared using nasal pledges with 1:80000 adrenaline and 2% xylocaine 10-15 minutes before surgery. Patient supine in reverse trendelenburg position with throat pack in patient's mouth. After draping, endoscopic examination was done with 0° rigid scope in the standard three passes to assess extent of the disease. Classical steps of ESS included: uncinectomy, middle meatal antrostomy (MMA) and anterior and posterior ethmoidectomy if indicated. 15 patients underwent swing door uncinectomy with MMA. This was performed by taking down the lower tow third of the vertical portion of the uncinate with backbiter while the horizontal portion was removed by submucosal dissection. In the remaining 13 patients, partial uncinectomy was performed by removing just the inferior vertical portion of the uncinate using the backbiter and the horizontal portion was removed by submucosal dissection. Merocel meatal pack was placed and left in situ for 24-48 hours. Patients were kept on injectable antibiotics for 3 days and then changed into oral antibiotics with hypertonic

nasal douching. Postoperative follow up by nasal endoscopic examination was conducted within 2 weeks, 4 weeks, 12 weeks, and 24 weeks. In each visit, we looked for, intranasal or intrameatal adhesion, epithelization of ostium and any osteal stenosis.

Statistical analysis: Data of cases were investigated employing the SPSS version 25. Descriptive statistics reported as frequencies, proportions (%), mean, standard deviation, 95% confidence interval of the mean is equal to [Mean \pm 1.96 x standard error of mean (SEM)]. For comparing the frequencies, the Chi square and Fisher's exact tests were used based on data availability. Mann-Whitney U non-parametric approach was employed to determine variables statistics range and P-value less than 0.05 was determined as significant.

Results

28 cases were investigated in this research, and were assigned into two groups; 15 cases underwent swing door operation and 13 cases underwent partial. The age and sex of the cases in both studied groups is shown in (Table 1), where the age of the cases in both groups ranged (11-50) years and a mean age of 25.58 \pm 7.14 years in Swing door group and 25.92 \pm 8.10 years in Partial group. Regarding the gender, females were the dominant in both Swing door and Partial groups accounting for 60% and 61.5%, respectively. However, both groups were almost matched for age and gender with non-significant statistical differences (Table 1). As it shown in (Figure 1), regarding indications of surgery, maxillary sinusitis was the main indication for surgery among the total 28 operated patients; it was the indication in 20 patients (71.4%), followed by OMC obstruction in 6 (21.4%) patients and the least frequent indications were antrochoanal polyp and fungal ball in one patient (3.6%) for each.

Regarding the operation time, it had been significantly found that Swing door operation needed longer duration than partial type; the mean operation time was 5.44 \pm 0.82 min and 3.42 \pm 0.36 min, respectively, (Figure 2) ($p < 0.001$). On the other hand, none of the patients in swing door group, complete the operation within 2-3 minutes, while in 10 patients (66.7%) of this group, the operation time was 4-5 minutes, and in 3 patients (20%) it was 6-7 minutes and in two patients it was 8-9 minutes. In the Partial group, the operation time was 2-3 minutes in 9 patients (69.2%), 4-5 minutes in 3 patients (23.1%), and only in one patient it was 8-9 minutes; by comparing the operation time intervals the difference was statistically significant, and longer operation time was associated with swing door rather than partial procedure ($p = 0.001$) (Table 2).

Table 1. Age and sex of patients

Variable	Swing door (n=15) Number(%) or Mean±SD	Partial (n=13) Number(%)or Mean±SD	p-value
Age (year)			
11-20	6(40.0)	5(38.3)	0.74
21-30	8(53.3)	6(46.2)	
31-40	0(0.0)	1(7.7)	
41-50	1(6.7)	1(7.7)	
Gender			
Male	40.0±6	38.5±5	0.76
Female	60.0±9	61.5±8	

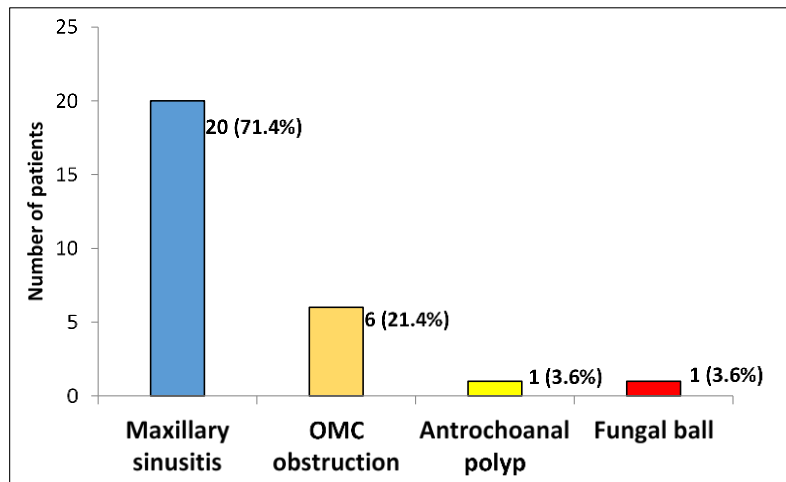


Figure 1. Indication of surgery of total 28 operated patients

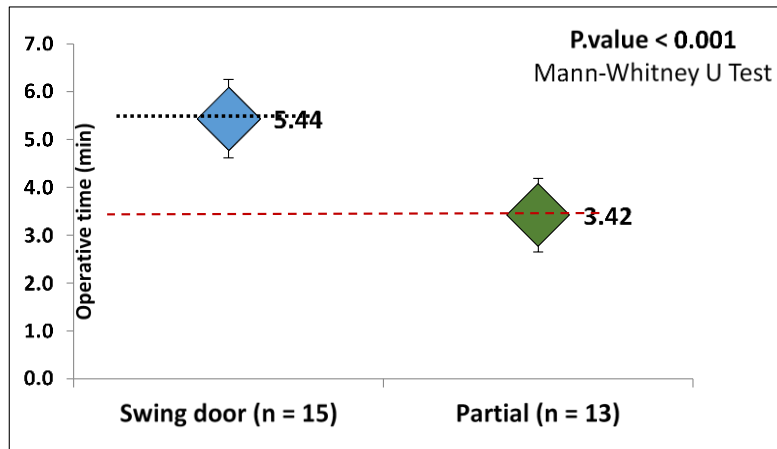


Figure 2. Graphical comparison of mean operation time and confidence intervals

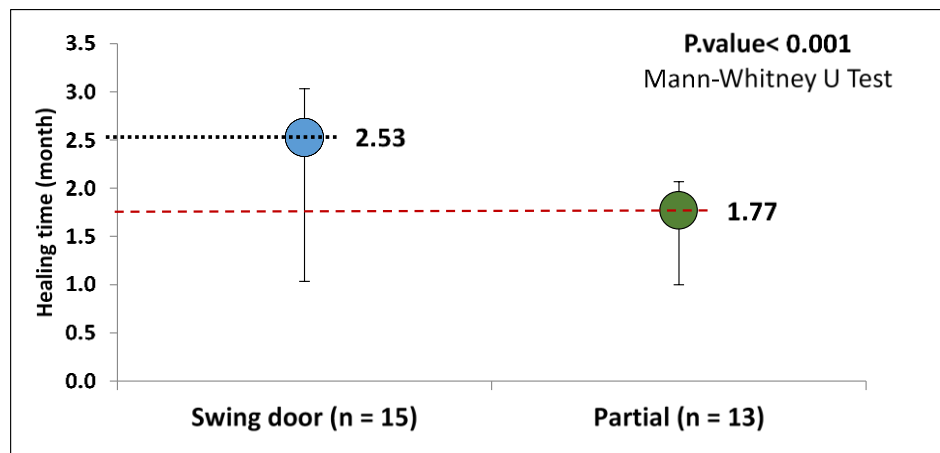
Table 2. Operation time of both procedures

Operation time (minutes)	Swing door (n=15) Number(%)	Partial (n=13) Number(%)	p-value
2-3	0(0.0)	9(69.2)	0.001
4-5	10(66.7)	3(23.1)	0.001
6-7	3(20.0)	0(0.0)	0.001
8-9	2(13.3)	1(7.7)	0.001

The healing time ranged 1-3 months in swing door group, where only one patient (6.7%) healed one month postoperatively, 5 patients (33.3%) after two months and 9 patients (60%) healed after three months. In Partial group, the healing time was one to two months and majority of the patients in this group 10/13 (76.9%) healed after two months while none needed further time to heal ($p=0.003$) (Table 3). The comparison of both groups in Healing time indicated that patients in swing door group needed longer healing time compared to Partial group. Furthermore, the mean healing time was significantly longer in swing group compared to partial group (2.53 ± 0.56) and (1.77 ± 0.20), respectively ($p<0.001$) (Figure 3).

Table 3. Healing time of both procedures

Healing time (month)	Swing door (n=15) Number(%)	Partial (n=13) Number(%)	p-value
One	1(6.7)	3(23.1)	0.003
Two	5(33.3)	10(76.9)	0.003
Three	9(60.0)	0(0.0)	0.003

**Figure 3. Graphical comparison of mean healing time and confidence intervals**

Intraoperatively, in the Swing door group, one patient suffered from a complication with LP injury. However, none of the patients in Partial group had such injury, and the incidence of this complication was insignificantly different between both groups ($p=0.94$). Moreover, none of the patients in both groups had developed NL duct injury; on the other hand, some intraoperative complications had been developed in Swing door group (Table 4).

Postoperatively, however, some patients had developed complication in both studied groups. However, the differences in the incidence of these complications were statistically insignificant. Synechia was reported in only two patients (13.3%) of the swing door group and none in partial group ($p=0.52$, insignificant). Intrameatal adhesion was developed in one patient of each group, ($p=0.49$, insignificant) and also ostium stenosis was found in one patient of each group ($p=0.49$, insignificant) (Table 5).

Table 4. Intraoperative complications

Parameter	Swing door (n=15) Number(%)	Partial (n=13) Number(%)	p-value
LP injury			
Positive	1(6.7)	0(0.0)	0.94
Negative	14(93.3)	13(100.0)	
NL duct injury			
Positive	0(0.0)	0(0.0)	NA
Negative	15(100.0)	13(100.0)	

NA: not available, couldn't be calculated

Table 5. Postoperative complications

Parameter	Swing door (n=15) Number(%)	Partial (n=13) Number(%)	p-value
Synechia			
Positive	2(13.3)	0(0.0)	0.52
Negative	13(86.7)	13(100.0)	
Intrameatal adhesion			
Positive	1(6.7)	1(7.7)	0.49
Negative	14(93.3)	12(92.3)	
Ostium stenosis			
Positive	1(6.7)	1(7.7)	0.49
Negative	14(93.3)	12(92.3)	

Discussion

ESS is the standard surgical procedure for chronic sinusitis (CRS) that is resistant to medical treatment. A recent US study revealed an additional incremental cost-effectiveness ratio of approximately \$14,000 per quality-adjusted life year for ESS versus medical treatment alone in cases with CRS, indicating that ESS is a cost-effective intervention (6). ESS comprises various categories of procedures, making it difficult to evaluate and compare the clinical and economic value of each surgical procedure. The Japanese Society of Rhinology presented a straightforward type of ESS in 2013. These types include 5 processes (class I, fenestration of the ostiomeatal complex with uncinectomy and widening of the natural ostium; class II, single-sinus procedure with manipulation of the sinus interior; class III, polysinus procedure; class IV, pansinus procedure; class V, extended procedure beyond the sinus wall) (7). Uncinectomy is the first step performed in functional ESS (8). Uncinectomy together with the middle meatal antrostomy are usually performed to clear the diseased maxillary sinus. Total uncinectomy is usually performed. In some situations, it may not necessary to perform total uncinectomy, as its late recovery leads to injury to the lamina papyracea or nasolacrimal duct. It may also increase the risk of iatrogenic fibrosis of the frontoethmoidal recess (3). The traditional method of uncinectomy also has more possibilities of disease recurrence and missed maxillary ostium syndrome (9).

Wormald and McDonogh in 1998 demonstrated a new method of uncinectomy named "SDT". It allows the uncinete to be respected and the maxillary sinus ostium to be identified. They concluded that SDT gives better postoperative outcomes with less complications in comparison to the standard sickle knife approach (10). Partial resection of the uncinete may be useful in patients whose disease is limited to the maxillary sinuses. Shorter surgery time, faster recovery, and fewer complications are advantages over traditional total uncinectomy. Surgical indications of partial uncinectomy include chronic maxillary sinusitis, fungal sinusitis, antrochoanal polyps, and odontogenic sinusitis (11). In our study, we evaluate the effect of partial uncinete resection versus total one (SDT) in patients with chronic localized maxillary sinus disease and osteomeatal obstruction refractory to medical treatment. We studied the age and gender predilection, indications of surgery, duration of the procedures, healing time, intraoperative complications and post-operative complications. Patients in both techniques were almost matched for age and gender with insignificant statistical differences. The study revealed that, both partial and swing door uncinectomy were comparable in both the safety and the effectiveness. However, partial uncinectomy had significantly shorter operation time than the SDT. The difference was statistically significant. Regarding the postoperative healing time, the patients with partial uncinectomy needed a short period to achieve a satisfactory healing

in follow up period in comparison to those with total technique. The result was statistically significant. These findings are consistent with those of two previous studies. In 2014, Byun et al., (5) reported that operation and recovery time are clearly less than for partial than for a total uncinectomy. In 2016, a study by Scangas et al., (6) compared partial and total uncinectomy for control of isolated maxillary sinus disease. They concluded that both operation and healing time for total uncinectomy is significantly longer than that for the partial one (12). Regarding the intraoperative complications, none of the patients in both groups suffered from NLD injury and only one patient in the Swing door group sustained minor LP injury and none of the patients in the Partial group had such injury. The incidence of such complication was statistically insignificant. Postoperatively some patients had developed complications in both studied groups, 1 synechia in swing door group, 1 intrameatal adhesion in each group and 1 ostium stenosis in each group. However, the differences in the incidence of these complications were statistically non-significant. This is consistent with the results of Mekhiemer et al. (2020) (12) and with the findings of a more recent study done by Chan et al. and Agrawal et al. (13, 14).

The technique of partial uncinectomy can be beneficial and applicable in cases with pathological issues localized to the maxillary sinus with less operation and recovery time, and lower complications possibility in comparison to the conventional total uncinectomy.

Acknowledgment

The authors highly appreciate the great help of all surgical teams at Al-Najaf Al-Ashraf Teaching Hospital.

References

- 1.Yadav SPS, Singh K, Gulia JS, Hooda A. Swing door technique for uncinectomy versus standard technique: a comparative study. *Singapore Med J*. 2021;62(2):92-5.
- 2.Awad Z, Bhattacharyya M, Jayaraj SM. Anatomical margins of uncinectomy in endoscopic sinus surgery. *Int J Surg*. 2013;11(2):188-90.
- 3.Cohen NA, Antunes MB, Morgenstern KE. Prevention and management of lacrimal duct injury. *Otolaryngol Clin North Am*. 2010;43(4):781-8.
- 4.Kilinc MC, Basak H, Çoruh AG, Mutlu M, Guler TM, Beton S, et al. Endoscopic Anatomy and a Safe Surgical Corridor to the Anterior Skull Base. *World Neurosurg*. 2021;145:e83-9.
- 5.Byun JY, Lee JY. Usefulness of partial uncinectomy in patients with localized maxillary sinus pathology. *Am J Otolaryngol*. 2014;35(5):594-7.
- 6.Scangas GA, Su BM, Remenschneider AK, Shrimme MG, Metson R. Cost utility analysis of endoscopic sinus surgery for chronic rhinosinusitis. *Int Forum Allergy Rhinol*. 2016;6(6):582-9.
- 7.Kanai K, Okano M, Haruna T, Higaki T, Omichi R, Makihara SI, et al. Evaluation of a new and simple classification for endoscopic sinus surgery. *Allergy Rhinol (Providence)*. 2017;8(3):118-25.
- 8.Rahman T, Alam MM, Ahmed S, Karim MA, Rahman M, Wahiduzzaman M. Outcome of Endoscopic Sinus Surgery in the Treatment of Chronic Rhinosinusitis. *Mymensingh Med J*. 2016;25(2):261-70.
- 9.Singhania AA, Bansal C, Chauhan N, Soni S. A comparative study of two different uncinectomy techniques: swing-door and classical. *Iran J Otorhinolaryngol*. 2012;24(67):63-7.
- 10.Mahoori A, Gholamveisi B, Golmohammadi M, Pashaei Khoei Sh, Sane Sh. The Effect of Oral Tizanidine on Bleeding and Quality of Surgical Field during Endoscopic Sinus Surgery. *J Babol Univ Med Sci*. 2020;22(1):181-7. [In Persian]
- 11.Govindaraju R, Cherian L, Macias-Valle L, Murphy J, Gouzos M, Vreugde S, et al. Extent of maxillary sinus surgery and its effect on instrument access, irrigation penetration, and disease clearance. *Int Forum Allergy Rhinol*. 2019;9(10):1097-104.
- 12.Mekhiemer S, Kadah S, Abd-Elgaber FM, Abd-Elghaffar A. Total versus partial uncinectomy in functional endoscopic sinus surgery. *J Rec Adv Med (JRAM)*. 2020;1(2):75-9.
- 13.Chan KKW, Lam CCY, & Chong KKL. Endoscopic Endonasal Approach to Optic Canal and Orbital Apex. In: Poon TL, Mak C, Yuen HKL, editors. *Orbital Apex and Periorbital Skull Base Diseases*. Singapore: Springer Nature Singapore; 2023. p. 187-93.
- 14.Agrawal N, Hansrajani V, Samadhiya M, Khandelwal P, Raghuwanshi V. A Comparative Study of Swing-Door and Classical Uncinectomy Technique. *J Med Sci Clin Res*. 2017;5(5):22344-8.