



Assessment of the Effectiveness and Security of Emergency Abdominal Wall Hernia Prosthetic Mesh Repair

N. K. Khиро (MD)^{*1} , M. A. Hamdawi (MD)¹ , B. A. Abdulhassan (MD)¹

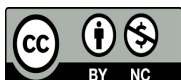
1. Department of Surgery, College of Medicine, Alnahrain University, Kadhimiya, Baghdad, Iraq.

*Corresponding Author: N. K. Khиро (MD)

Address: Department of Surgery, College of Medicine, Alnahrain University, Kadhimiya, Baghdad, Iraq.

Tel: +964 (780) 1604775. E-mail: mohammedhamdawi@gmail.com

| Article Type | ABSTRACT |
|--|--|
| Research Paper | <p>Background and Objective: The method of repair in complicated ventral hernia at emergency setting imposes a great challenge to the surgeon worldwide. Using polypropylene mesh is very challenging because of the great concern about risks of complications. This study was conducted to determine the safety and efficiency of polyproline mesh in complicated emergency ventral hernia.</p> <p>Methods: This prospective study was conducted on 60 patients with complicated abdominal hernia who required emergency surgery (obstructed and or strangulated). The cases were divided based on the type of repair into two groups: prosthetic mesh repair and suture repair. Patients were followed up for a median of 14.2 months after operation during which surgical infection, seroma formation and recurrence rate were evaluated in both groups.</p> <p>Findings: The common type of hernia encountered in this research was paraumbilical hernia compromising 80% (48 patients) of the total patients followed by recurrent paraumbilical hernia (11.66%). Superficial surgical infection and seroma developed in 15.38% (4 patients) in the mesh group and in 8.82% (3 patients) in the suture repair group with no significant differences. The recurrence rate was 8 people (23.52%) in the suture group and 2 people (7.69%) in the mesh group; however, this difference was not significant.</p> <p>Conclusion: The results showed that the use of prosthetic mesh in the repair of emergent complicated ventral abdominal wall hernia is feasible choice with low risk of complications.</p> <p>Keywords: <i>Hernia, Abdominal; Emergencies; Complications.</i></p> |
| Received: Jul 15 th 2023 | |
| Revised: Nov 4 th 2023 | |
| Accepted: Nov 21 st 2023 | |
| Cite this article: Khиро NK, Hamdawi MA, Abdulhassan BA. Assessment of the Effectiveness and Security of Emergency Abdominal Wall Hernia Prosthetic Mesh Repair. <i>Journal of Babol University of Medical Sciences</i> . 2024; 26: e41. | |



Introduction

Hernias of the anterior abdominal wall, known as ventral hernias, occur when there are defects in the fascia and muscle of the abdominal wall, allowing intra-abdominal or preperitoneal contents to protrude (1). Emergency surgery is often necessary for many abdominal hernias, but these processes can be linked by a poor prognosis and a high ratio of postoperative complications (2). Multiple studies have demonstrated the significant benefits of using mesh in elective hernia repairs, where infection is unusual (3). Mesh application is user-friendly, needs less complication ratios, and clearly decreases the risk of recurrence. However, there is limited research on the outcomes of mesh use in emergency settings, as the surgical field is usually contaminated due to bowel involvement (4, 5).

The choice of repair technique depends on the degree of surgical field contamination, the hernia size, and the surgeon's performance. The microbial flora typically consists of a mix of aerobic and anaerobic bacteria that resemble the normal microflora of the gastrointestinal (GI) tract and were the common pathogens (6). Macroporous mesh with large pores (>1 mm) have been shown to facilitate the infiltration of macrophages, fibroblasts, and collagen fibers, which contribute to the formation of new connective tissue. This integration of the prosthesis with the body helps prevent bacterial colonization and provides protection against infection. Large pores also allow easy infiltration of immune cells, further enhancing the body's defense mechanisms (7).

While there is abundant literature supporting the use of prosthetic mesh in clean surgical fields, the utilization of these materials in clean-contaminated or contaminated settings was rarely defined (8). Many experts say that permanent prosthetic materials are not suitable for cases with gross contamination in hernia repair, such as emergency presentations, due to the risk of infection (9).

The current study aims to assess the safety and efficiency of using prosthetic mesh in the repair of complicated ventral hernias in emergency situations.

Methods

The Study Population: This prospective investigation was performed at Al-Imamain Al-Kadhumain Medical City in Baghdad, from October 2016 to October 2020 under ethical code of AI-IMC-2022-345. The research involved 60 cases presented to the emergency department with complicated ventral hernia and required immediate surgery within 4-6 hours of presentation. These patients experienced various symptoms related to their ventral hernias, ranging from acute abdominal pain to vomiting and absolute constipation, with the hernia being irreducible manually. The cases of the study had an ASA score of I–II. Exclusion criteria for the study were cases with poorly controlled type 1 or type 2 diabetes, cases with a BMI more than 36 kg/m², patients on steroids, patients with ascites, asthma, or chronic obstructive pulmonary disease (COPD), cases requiring colonic resection, and patients with hernia defects less than 2 cm or greater than 6 cm. All cases signed and confirm before investigation, and the research was confirmed by the Iraqi Council of Medical Specializations.

Preoperative preparation: Prior to the operation, all enrolled patients underwent a clinical examination. The study recorded demographic data such as sex, age, co-morbidities, BMI, and the specific complications associated with the hernias. Routine laboratory investigations, electrocardiograms (ECGs), and in some cases, abdominal radiographs in both the erect and supine positions, as well as abdominal ultrasonography, were performed to assess the viability of the hernia contents.

The preoperative management protocol included the following: patients were instructed to refrain from eating or drinking (nil by mouth), a nasogastric tube was used if necessary, fluid therapy was administered, and prophylactic intravenous antibiotics were given one hour prior to surgery.

Operative technique: The surgeries were performed with the patients in the supine position under general anaesthesia. A surgical incision was made in the area where the hernia bulge was located, and in cases of recurrent or incisional hernias, any previous scars were removed. The hernial sac was carefully dissected, with the suctioning of any fluids present in it. For strangulated hernias, the hernia defect was widened to release adhesions and relieve any constriction among the inner and the surrounding area. The viability of the hernia sac contents was assessed, and if any bowel was suspected to be compromised, it was covered with warm wet towels for 5-10 minutes. If gangrenous contents were found, the affected portion of the bowel was resected. Flaps were raised via separating the subcutaneous tissue from the anterior rectus sheath. The surgical sites were irrigated with a 10% povidone iodine solution for one minute to disinfect the tissue, followed by a generous amount of warm normal saline solution (0.9%) to thoroughly wash out any remaining infection. The specific technique for hernia repair was determined through discussions with the surgeon on call.

The Study Groups: The patient population was divided into two groups according to the closure method of the hernia defect and the surgeon's performance:

Group A consisted of 26 patients who underwent mesh repair using wide pore polypropylene. The lightweight polypropylene mesh was secured to the anterior rectus sheath using interrupted non-absorbable polypropylene sutures that passed over the muscle of rectus. Prior to this, the layers on the right side of rectus sheath were sutured from both sides by sewing thread (Figure 1). The mesh extended 4-5 cm on each side, and the Onlay technique was employed for mesh repair in all patients. The skin was closed through a subcutaneous 18 Fr suction drain.

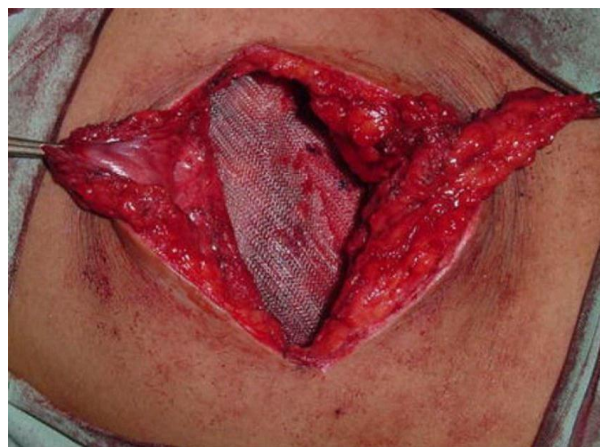

Figure 1. Illustrating the attachment of the wide pore lightweight polypropylene mesh to the anterior rectus sheath

Group B consisted of 34 patients who underwent Darn suture repair. Following irrigation of the subcutaneous tissue at the surgical places, the two rectus muscles were sutured together using a continuous non-absorbable suture (Darn repair), which was further reinforced with additional continuous non-absorbable sutures. The skin was closed through a subcutaneous 18 Fr suction drain.

We asked patients to start ambulation with the support of a well-designed abdominal binder. Drains were removed when the drainage became minimal, typically within 3-7 days, and when the discharge was serous and less than 50 ml within a 24-hour period. In the final stage of hospital discharge, patients were recommended not to bear heavy things and advised to seek immediate medical attention for the prompt treatment of constipation and cough. Follow-up appointments were scheduled at the outpatient clinic on a weekly basis during the 30 days after discharge and then every 3 months during the first year.

The duration of follow-up ranged from 6 months to 2 years, with a median follow-up period of 14.2 months. During each visit, potential complications were assessed, including:

1. Surgical site infection (SSI): This included superficial and/or deep infections characterized by purulent discharge, collection, redness at the operation site, cellulitis, wound dehiscence, and fever with increased white blood cell count. Patients who developed SSI after mesh repair were readmitted, and appropriate antibiotics were administered based on culture results. Local dressings were also applied. In cases where conservative management failed, deep collections were drained, wounds were irrigated, and frequent dressings were performed. Secondary suturing (delayed primary closure) was done after two weeks.

2. Seroma: This referred to the collection of sterile serous fluid in the surgical field after drain removal. Abdominal wall ultrasonography was performed if there was any swelling in the operative area. Seromas were aspirated in the outpatient clinic under aseptic conditions, guided by ultrasonography, using a 50 ml sterile syringe.

3. Hernia recurrence: Expressed as the reappearance of a ventral hernia at previous repair, this was confirmed by abdominal ultrasonography and/or CT scan, taking into account the cases report and clinical data during the follow-up determined time.

SPSS software version 20 was used to Statistical investigation. Variables were written as mean and standard deviation and independent t-tests. Dependent factors were written and tested employing the Chi-square method. A p-value of 0.05 or less was regarded as significant.

Results

Profile of patients: The mean age of the cases in mesh group was 49.72 ± 6.18 years which did not differ significantly from that of suture group (51.92 ± 7.31). Males represented about two third of cases in both groups with no significant difference. The mean BMI in mesh and suture group was $27.9 \pm 6.1 \text{ kg/m}^2$ and $26.4 \pm 5.8 \text{ kg/m}^2$, respectively with no significant difference. Although suture group had higher frequency of ASA II than mesh group (52.63% vs. 38.46%), the difference was not significant (Table 1).

Table 1. Profile of patients

| Variables | Mesh (n=26) Mean±SD or Number(%) | Suture (n=34) Mean±SD or Number(%) | p-value |
|-------------------------------|-------------------------------------|---------------------------------------|---------|
| Age (years) | 49.72±6.18 | 51.92±7.31 | 0.391 |
| Range | 20-76 | (23-72) | |
| Gender | | | 0.794 |
| Male | 17(65.38) | 21(61.76) | |
| Female | 9(34.62) | 13(38.24) | |
| BMI (kg/m²) | 27.9±6.1 | 26.4±5.8 | 0.608 |
| Range | 22.9-36.4 | 21.7-35.8 | |
| ASA score | | | 0.192 |
| I | 16(61.54) | 14(38.89) | |
| II | 10(38.46) | 20(52.63) | |

Clinical Profile of the Cases: The main part of cases in mesh and suture group had PUH (76.29% and 82.35%). Recurrent PUH was reported in 11.53% and 11.76% of the patients, respectively. Statistically, there is no significant variation between the two groups in types of hernia.

In group A, the majority of indication of surgery was obstructed hernia found in 19 patients (73.08%), while strangulated bowel was seen in 11 patients (42.31%); 9 of whom (81.82%) underwent bowel resection. In group B, small bowel obstruction was found in 23 patients (67.64%), while the strangulated bowel was seen in 9 patients (26.47%) in which 8 patients of them required bowel resection with no significant difference.

The omentum was strangulated in one case in group A (3.84%) and in two cases in group B (5.88%) with no significant difference (Table 2).

Table 2. Operative characteristics of the cases

| Variables | Mesh (n=26) Number(%) | Suture (n=34) Number(%) | Total (n=60) Number(%) | p-value |
|---|--------------------------|----------------------------|---------------------------|---------|
| Types of hernia | | | | |
| PUH | 20(76.92) | 28(82.35) | 48(80) | 0.962 |
| Recurrent PUH | 3(11.53) | 4(11.76) | 7(11.66) | |
| Incisional | 2(7.69) | 2(5.88) | 4(6.66) | |
| Epigastric | 1(3.84) | 0(0) | 1(1.66) | |
| Obstructed bowel | | | | |
| No | 7(26.92) | 11(32.35) | 18(30) | 0.779 |
| Yes | 19(73.08) | 23(67.65) | 42(70) | |
| Strangulated bowel | | | | |
| No | 15(57.69) | 25(73.53) | 40(66.67) | 0.764 |
| Yes | 11(42.31) | 9(26.47) | 20(33.33) | |
| Resection of strangulated hernia | | | | |
| No | 2(18.18) | 1(11.11) | 3(15) | 0.881 |
| Yes | 9(81.82) | 8(88.89) | 17(85) | |
| Strangulated omentum | | | | |
| No | 25(96.15) | 32(94.11) | 57(95) | 0.626 |
| Yes | 1(3.84) | 2(5.88) | 3(5) | |

PUH: Para-umbilical hernia

Postoperative Complications: It is worth mentioning that all patients in both groups had a successful surgery without any notable intraoperative complications. Postoperative complications are listed in table 3. In group A; 4 patients (15.38%) out of 26 developed SSI of whom one patient had deep SSI treated with open drainage, while the other three patients had SSI and treated with antibiotics. In group B: 3 patients (8.82%) out of 34 patients developed SSI of whom only one patient had deep SSI and two patients had superficial SSI. Those patients were treated in similar pattern as in group A.

Seroma incidence is more common in mesh group than suturing group (15.38% (4 cases) vs. 8.82% (3 patients)) with no significant difference. Patients who developed seroma in either group were treated antibiotics and aspiration in the outpatient clinic by utilizing a 50ml sterile syringe under aseptic technique with the guidance of ultrasound.

In contrast, the recurrence rate was almost three times higher in suture repair (23.52% (8 patients) vs. 7.69% (2 patients)); however, Fisher exact test revealed no significant difference between the two groups. Interestingly, no patient required postoperative intensive care unit (ICU) or respiratory care unit (RCU) admission after surgery.

Table 3. Postoperative complications

| Variables | Mesh (n=26) Number(%) | Suture (n=34) Number(%) | p-value |
|--------------------------------|--------------------------|----------------------------|---------|
| Surgical site infection | | | |
| Total | 4(15.38) | 3(8.82) | |
| Superficial | 3(11.54) | 2(5.88) | 0.454 |
| Deep | 1(3.85) | 1(2.94) | |
| Seroma | 4(15.38) | 3(8.82) | 0.454 |
| Recurrence | 2(7.69) | 8(23.52) | 0.163 |
| Total | 10(38.46) | 14(41.18) | 0.832 |

Discussion

Numerous studies conducted worldwide have shown widespread approval of mesh repair, as infection is uncommon and the use of mesh significantly reduces the recurrence ratio (10). However, there is limited research on the mesh outcome application in emergency situations where the surgical field is often contaminated due to bowel involvement. In the present study, both the mesh repair and suture repair groups had similar patient demographics and hernia features, which helps reduce the potential for selection based on linked with prospective investigations. A notable finding in this study was the nonsignificant variation between mesh and suture repair groups in terms of the incidence of deep and superficial surgical site infections (SSI). This finding is consistent with many previous studies. Emile et al. (11) conducted a research with 122 cases to study the outcomes of strangulated ventral hernias. More than half of the patients underwent Onlay mesh repair, while the rest underwent suture repair (54% and 46%, respectively). The rate of SSI was 7.5% and 5.3% in the mesh and suture groups, respectively, with no significant difference. Similar results were obtained in other studies (8, 12-16). However, a retrospective research of 23 cases who underwent emergency hernia repair with intestinal resection reported a nonsignificant higher rate of wound infection in the suture group (35%) compared to the mesh group (22%) (17). The relatively low infection rate in the mesh group can be attributed to the fact that polypropylene meshes, commonly used in these procedures, have properties that make them ideal for contaminated or clean-contaminated surgical fields (e.g., obstructed or strangulated hernias). These meshes are composed of monofilamentous structures with wide pores (70 microns) that allow immune cells and antibiotics to infiltrate while providing contact between bacteria (1-micron diameter) and the immune system cells (granulocytes and macrophages) that measure 7-11 microns in radius (17-19).

In the present study, the development of seroma was more frequent in the mesh group (15.38%) compared to the suture group (8.82%). These results are consistent with an Egyptian study by Abd El-Kader et al. (13), which reported a seroma frequency of 6.7% in both the mesh and suture repair groups. However, another study reported a higher rate of seroma in the mesh group (22.7%) compared to the suture repair group (7.1%), although the variation was not significant (11).

One of the most significant findings in this study was that the mesh repair group had a lower recurrence rate than the suture repair group. The nonsignificant difference observed in this study may be attributed to the relatively small sample size. Similar findings have been reported in several other studies worldwide. Abdel-Baki et al. (20) conducted a prospective randomized study involving 42 patients and compared the utility of prosthetic mesh with suture repair in the emergency control of ventral hernias. Cases are observed in 11-21 months, and no recurrences are reported in the mesh group, while the suture group has a recurrence rate of 19%, which was statistically significant. A meta-analysis (21), which included 13 articles with a total of 1790 patients, also reported that mesh repair clearly decreased the recurrence rate without a significant variation in postoperative complications for the repair of ventral hernias. Several other studies have indicated similar findings (22, 23).

The application of prosthetic mesh in the repair of emergent complicated ventral abdominal wall hernia is possible and safe. Regarding the acceptable risk of Surgical Site Infection, manageable seromas and reducing recurrent rate, to reduce the hazard of seroma in either method, the study recommends dissection, accurate homeostasis, slight use of diathermy, use of pressure dressing with a binder for 4-6 weeks and placement of subcutaneous drains with avoiding of premature removal.

Acknowledgment

The authors highly appreciate the great help of all surgical teams at Al-Imamain Al-Kadhumain Medical city/Baghdad.

References

1. Das C, Jamil T, Stanek S, Baghmanli Z, Macho JR, Sferra J, et al. Inguinal Hernia. In: Charles Brunicaardi F, Andersen DK, Billiar TR, Dunn DL, Hunter JG, Kao LS, et al, editors. *Schwartz's Principles of Surgery*, 11st ed. NewYork: McGraw Hill; 2019. p.1599-624.
2. Helgstrand F, Rosenberg J, Kehlet H, Bisgaard T. Outcomes after emergency versus elective ventral hernia repair: a prospective nationwide study. *World J Surg*. 2013;37(10):2273-9.
3. Ventral Hernia Working Group; Breuing K, Butler CE, Ferzoco S, Franz M, Hultman CS, Kilbridge JF, et al. Incisional ventral hernias: review of the literature and recommendations regarding the grading and technique of repair. *Surgery*. 2010;148(3):544-58.
4. Mohammadi M, Enhesari A, Ghaedamini H, Amirbeigi A, Farahbakhsh S. Investigating the Diagnostic Accuracy of Focused Assessment with Sonography in Trauma (FAST) Compared to CT Scan in Patients with Blunt Abdominal Trauma. *J Babol Univ Med Sci*. 2023;25(1):143-51. [In Persian]
5. Asadi Amoli A, Mehrabani S, Esmaeili Dooki M, Nikpour M, Hadipour A, Pournasrollah M, et al. Comparison of Clinical Findings of Acute Appendicitis and Mesenteric Lymphadenitis in Children with Acute Abdominal Pain. *J Babol Univ Med Sci*. 2023;25(1):204-12. [In Persian]
6. Donoso PC, Pérez MP, Aguirre CC, Barbosa AO, Gómez CM, Jimenez AM, et al. Primary adrenal angiosarcoma. A case report. *Archivos de Patología*. 2022;3(3):96-103.
7. Baylón K, Rodríguez-Camarillo P, Elías-Zúñiga A, Díaz-Elizondo JA, Gilkerson R, Lozano K. Past, Present and Future of Surgical Meshes: A Review. *Membranes (Basel)*. 2017;7(3):47.
8. Zafar H, Zaidi M, Qadir I, Memon AA. Emergency incisional hernia repair: a difficult problem waiting for a solution. *Ann Surg Innov Res*. 2012;6(1):1.
9. Machairas A, Liakakos T, Patapis P, Petropoulos C, Tsapralis D, Misiakos EP. Prosthetic repair of incisional hernia combined with elective bowel operation. *Surgeon*. 2008;6(5):274-7.
10. Martínez-Serrano MA, Pereira JA, Sancho J, Argudo N, López-Cano M, Grande L. Specific improvement measures to reduce complications and mortality after urgent surgery in complicated abdominal wall hernia. *Hernia*. 2012;16(2):171-7.
11. Emile SH, Elgendy H, Sakr A, Gado WA, Abdelmawla AA, Abdelnaby M, et al. Outcomes following repair of incarcerated and strangulated ventral hernias with or without synthetic mesh. *World J Emerg Surg*. 2017;12:31.
12. Abd Ellatif ME, Negm A, Elmorsy G, Al-Katary M, Yousef Ael-A, Ellaithy R. Feasibility of mesh repair for strangulated abdominal wall hernias. *Int J Surg*. 2012;10(3):153-6.
13. Abd El-Kader AM, Ali HE. The outcome of using a prosthetic mesh in the repair of emergent abdominal midline incisional hernias: a prospective comparative study. *Egyptian J Surg*. 2018;37(2):147-54.
14. Haskins IN, Amdur RL, Lin PP, Vaziri K. The Use of Mesh in Emergent Ventral Hernia Repair: Effects on Early Patient Morbidity and Mortality. *J Gastrointest Surg*. 2016;20(11):1899-903.
15. Lari Najafi M, Nasiri M. Review of drug abuse patterns and their association with some individual and social variables among addicts. *J Adv Pharm Educ Res*. 2019;9(2):99-101.
16. Vix J, Meyer Ch, Rohr S, Bourtooul Ch. The treatment of incisional and abdominal hernia with a prosthesis in potentially infected tissues — A series of 47 cases. *Hernia*. 1997;1:157-61.
17. Nieuwenhuizen J, van Ramshorst GH, ten Brinke JG, de Wit T, van der Harst E, Hop WC, et al. The use of mesh in acute hernia: frequency and outcome in 99 cases. *Hernia*. 2011;15(3):297-300.

18. Franciosi C, Romano F, Caprotti R, De Fina S, Colombo G, Visintini G, et al. Ernioplastica con rete in prolene secondo Lichtenstein. Risultati su 692 casi [Hernia repair with prolene mesh according to the Lichtenstein technique. Results of 692 cases]. *Minerva Chir.* 2000;55(9):593-7.
19. Horharin P, Wilasrusmee C, Cherudchayaporn K, Pinyaku N, Phanpradi O, Phromsopha N. Comparative study of tailor-made mesh plug herniorrhaphy versus Lichtenstein herniorrhaphy versus Bassini operation: a prospective clinical trial. *Asian J Surg.* 2006;29(2):74-8.
20. Abdel-Baki NA, Bessa SS, Abdel-Razek AH. Comparison of prosthetic mesh repair and tissue repair in the emergency management of incarcerated para-umbilical hernia: a prospective randomized study. *Hernia.* 2007;11(2):163-7.
21. Aslani N, Brown CJ. Does mesh offer an advantage over tissue in the open repair of umbilical hernias? A systematic review and meta-analysis. *Hernia.* 2010;14(5):455-62.
22. Bessa SS, Abdel-fattah MR, Al-Sayes IA, Korayem IT. Results of prosthetic mesh repair in the emergency management of the acutely incarcerated and/or strangulated groin hernias: a 10-year study. *Hernia.* 2015;19(6):909-14.
23. Siddiqui A, Lyons NB, Anwoju O, Cohen BL, Ramsey WA, O'Neil CF, et al. Mesh Type With Ventral Hernia Repair: A Systematic Review and Meta-analysis of Randomized Trials. *J Surg Res.* 2023;291:603-10.