

Pyogenic Granuloma in Pregnancy: A Case Report

I. Naghi (MD)¹, F. Keypour (MD)^{*2}

1.Department of Obstetrics & Gynecology, Shahid Beheshti University of Medical Sciences, Tehran, I.R.Iran

2.Department of Obstetrics & Gynecology, Akbarabadi Teaching Hospital, Iran University of Medical Sciences, Tehran, I.R.Iran

J Babol Univ Med Sci; 21; 2019; PP: 153-6

Received: Aug 27th 2018, Revised: Dec 4th 2018, Accepted: Jan 9th 2019.

ABSTRACT

BACKGROUND AND OBJECTIVE: Pyogenic granuloma is a lesion that affects pregnant women between the third and ninth month of pregnancy. It is a benign vascular proliferative disease that often appears on the gingiva, but may also appear on the lips, skin and extramucosal tissues. The purpose of the report is to introduce a pregnant woman with pyogenic granuloma with a lesion on her face.

CASE REPORT: The patient is a pregnant woman at 39 weeks of gestation without a history of a specific illness who referred to Shahid Akbarabadi Hospital in Tehran due to labor pain. A vascular nodule was visible on her face, which appeared from the first half of pregnancy and was reported to be normal in terms of paraclinical experiments. This vascular nodule improved after delivery but did not completely disappear. The patient underwent aesthetic surgery for the vascular nodule three months after delivery. The results of the pathology confirmed pyogenic granuloma.

CONCLUSION: According to the results of this report, if unusual lesions are observed on the face during pregnancy, oral and dental problems should be considered and patients should be examined by the dentist.

KEY WORDS: *Pyogenic Granuloma, Vascular Nodule, Pregnancy.*

Please cite this article as follows:

Naghi I, Keypour F. Pyogenic Granuloma in Pregnancy: A Case Report. J Babol Univ Med Sci. 2019;21:153-6.

* Corresponding Author: F. Keypour (MD)

Address: Department of Obstetrics & Gynecology, Akbarabadi Teaching Hospital, Iran University of Medical Sciences, Tehran, I.R.Iran

Tel: +98 21 55630858

E-mail: keypour.f@iums.ac.ir

Introduction

The pregnancy tumor or "pyogenic granuloma" is a lesion that affects pregnant women between the third and ninth month of pregnancy (1, 2). This injury is more known as an inflammatory pseudotumor, rather than a neoplasm. This vascular nodule occurs in the gingiva in most cases, and its occurrence is more common in maxilla and the anterior mandible (3, 4). Pyogenic granuloma may clinically interfere with chewing and lead to malnutrition in mothers. A person may notice some blood after brushing their teeth, which attracts the patient's attention. Sometimes severe bleeding also occurs in relation to these injuries and causes physical and psychological complications for the patient. In some cases, the inhibition and treatment of this injury or its complications due to problems during pregnancy causes great trouble for the patient and the therapist (2–5). This lobular capillary hemangioma is seen in 2% of pregnant women (6).

Oettinger et al. showed the role of female sex hormones, vascular proliferation and local stimuli in the emergence of pyogenic granuloma (7). Diaz-Guzman et al. showed that the prevalence of pyogenic granuloma in pregnant women is 20 times higher than non-pregnant women (8). Lawoyin et al. selected 400 pregnant women randomly and discovered 15 cases of pyogenic granuloma among them (9). After investigating gingival diseases in 130 pregnant women, Machuca et al. emphasized on the importance of prevention and treatment of periodontal diseases in pregnant women (10). In 1904, the vascular origin of the disease was discovered and the term "pyogenic granuloma" was used for it (6). This lesion may appear on the skin or mucosa. When the lesion is observed on the mucosa or on the gingiva, it is called the Epulis, which is caused by the growth of the gingival capillaries. Benign proliferation of the vessels in the gingiva often occurs in the second to fifth month of gestation (6).

Many skin diseases occur for the first time in pregnancy. Some dermatoses are only observed during pregnancy. Some of them are associated with poor pregnancy outcomes while some others are aesthetically important and lack any risk for the mother and fetus. Therefore, proper and timely diagnosis and treatment of the disease is important for the improvement of mother and the pregnancy outcomes (4). Since hormonal changes during pregnancy may cause physiological changes in the skin and can be of great concern to mothers aesthetically, the outcome and recovery or the lack of recovery from these changes are highly

important. In this study, a case of pyogenic granuloma on the face is presented and the results are reported.

Case report

The patient is a 22-year-old pregnant woman at 39 weeks of gestation who referred to Shahid Akbar Abadi Hospital in Tehran due to labor pain in 2017. A red vascular nodule was visible on her face (Figure 1), which appeared from the first half of pregnancy according to the patient. Clinically speaking, this vascular lesion had no pain, itching, or bleeding. All paraclinical tests including WBC, hemoglobin, hematocrit, and blood platelet count were normal. Liver and kidney tests were also normal. The patient did not mention any history of specific illness. The delivery process was performed for her through vaginal delivery, and the baby was born with appropriate Apgar score and weighed 3420 grams. The vascular nodule became smaller within three months after delivery. However, the patient decided to undergo aesthetic surgery for this vascular nodule and recovered. The pathology results confirmed pyogenic granuloma. Figure 2 shows the microscopic view of pyogenic granuloma.

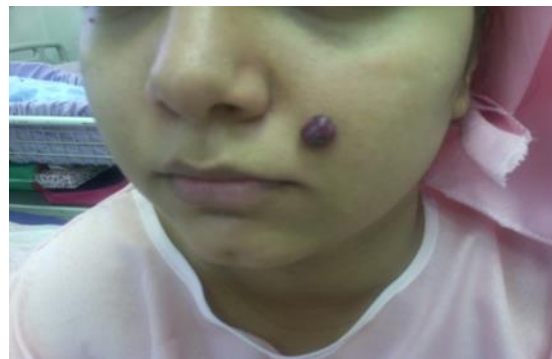


Figure 1. Pregnancy tumor (pyogenic granuloma) on the face of the pregnant woman

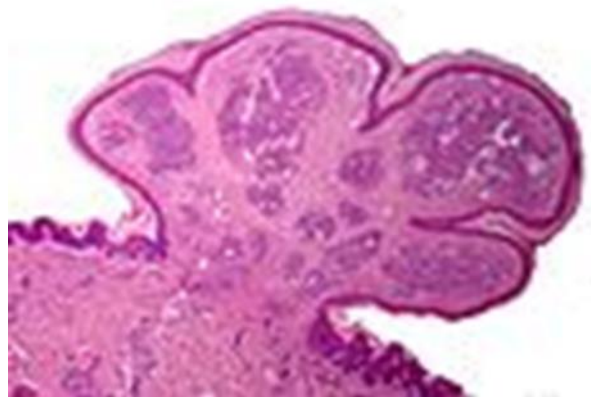


Figure 2. Microscopic view of pregnancy tumor (lobular capillary hemangioma)

Discussion

A 22-year-old pregnant woman with pyogenic granuloma is reported in this study. In the study of Chamani et al., the mean age of pregnant women with pyogenic granuloma was 27 years (11), which is similar to this case. In a study by Khatibi et al., the mean age was 26.8 years and the location of the lesion was reported in the gingiva (12), but in our case, the location of the lesion was observed on the face of a pregnant woman, which is quite rare. Physiological changes in pregnancy include changes in the skin, hair and nails. Human skin changes during pregnancy due to endocrine, metabolic, and mechanical system, and blood flow (13).

Physiological changes are important in terms of aesthetics. It is obvious that skin diseases that affect the reproductive age are commonly seen during pregnancy. Many skin tumors appear for the first time in pregnancy. Due to increased estrogen and its effects on arteries, some of these diseases do not lead to any risk for mother and baby and are expected to improve after delivery (6, 8, 13). In addition, a few dermatoses are only visible during pregnancy (13). Pyogenic granuloma is a benign vascular growth in the form of lobular capillary hemangioma, which is commonly seen in pregnancy. It may be observed on the skin or oral mucosa (1). Although the etiology of this disorder is not fully known yet, estrogen-induced hormonal changes in pregnancy are shown to be effective in its occurrence. Mohtasham et al. also showed that estrogen and progesterone receptors play a role in the incidence of pyogenic granuloma (14). Diaz-Guzman et al. showed that the prevalence of pyogenic granuloma in pregnant women

is 20 times higher than that of non-pregnant women (8). Lawoyin et al. studied 400 pregnant women and found 15 cases of pyogenic granuloma among them (9). In all cases, lesion was observed in the gingiva, but in our case, the lesion was observed on the face.

Most of these vascular lesions often resolve within a few months after delivery. However, in the case of symptomatic lesions or when the lesions are persisting, or if the diagnosis is unclear, the vascular nodule can be removed by surgery, laser photocoagulation or electro-surgical curettage (13, 15). Amelanotic melanoma should be considered in the differential diagnosis of this lesion. Biopsy contributes to the diagnose of this disease (16). In a case report, YarKac et al. emphasized that pyogenic granuloma is a non-neoplastic lesion. Using laser surgery, they shortened the duration of the operation and reduced the amount of bleeding during the operation, and removed the lesion using laser (17). The reason for the difference in the method of removing the lesion in our study and this study is the large size of lesion, since laser therapy causes homeostasis and contraction of collagen in arterial walls. What is more important is the adverse effects of some of these skin diseases on the mother and the fetus during pregnancy. Therefore, timely and proper diagnosis and treatment of the disease is important for the improving the condition of the mother and the outcome of pregnancy.

Acknowledgment

Hereby, we would like to thank Shahid Akbarabadi Clinical Research Development Unit, Iran University of Medical Sciences to support this research.

References

1. Lawiey LP, Levy ML, Corona R. Pyogenic granuloma (Lobular capillary hemangioma). UpToDate. 2016. Available from: <https://www.uptodate.com/contents/pyogenic-granuloma-lobular-capillary-hemangioma>
2. Cunningham FG, Leveno KJ, Bloom SL, Dashe JS, Hoffman BL, Casey BM, Spong CY. Williams Obstetrics, 25th ed. New York: McGraw Hill; 2018. p. 1238.
3. Terezhalmay G, Riley C, Moore W. Pyogenic granuloma (pregnancy tumor). Quintessence Int. 2000;31(6):440-1.
4. Wang P, Chao HT, Lee WL, Yuan CC, Ng HT. Severe bleeding from a pregnancy tumor. A case report. J Reprod Med. 1997;42(6):359-62.
5. Sills ES, Zegarelli DJ, Hoschander MM, Strider WE. Clinical diagnosis and management of hormonally responsive oral pregnancy tumor (pyogenic granuloma). J Reprod Med. 1996;41(7):467-70.
6. Neville BW, Damm DD, Allen CM, Chi AC. Oral and maxillofacial pathology, 4th ed. Elsevier: Saunders; 2015.
7. Oettinger-Barak O, Machtei EE, Ofer BI, Barak S, Peled M. Pregnancy tumor occurring twice in the same individual: report of a case and hormone receptors study. Quintessence Int. 2006;37(3):213-8.
8. Diaz-Guzman LM, Castellanos-Suarez JL. Lesions of the oral mucosa and periodontal disease behavior in pregnant patients. Med Oral Patol Oral Cir Bucal. 2004;9(5):434-7; 430-3.
9. Lawoyin JB, Arotiba JT, Dosumu OO. Oral pyogenic granuloma: a review of 38 cases from Ibadan, Nigeria. Br J Oral Maxillofac Surg. 1997;35(3):185-9.
10. Machuca G, Khoshfeiz O, Lacalle JR, Machuca C, Bullón P. The influence of general health and socio-cultural variables on the periodontal condition of pregnant women. J Periodontol. 1999;70(7):779-85.
11. Chamani G, Navabi N, Abdollahzadeh S. Prevalence of Pregnancy Tumor in Pregnant Women. J Dent. 2009; 10(1): 79-82.
12. Khatibi M, Niromanesh S, Abhari S, Falakflaki N. Prevalence of Pregnancy Tumor (Pyogenic Granuloma) and Related Factors in Pregnant Women Referred to Tehran Mirza Kuchak Khan Hospital during 2010-2011. Iran J Obstet Gynecol Infertil. 2013; 16(71): 1-6.
13. Gomes SR, Shakir QJ, Thaker PV, Tavadia JK. Pyogenic granuloma of the gingiva: A misnomer?—A case report and review of literature. J Indian Soc Periodontol. 2013;17(4):514.
14. Mohtasham N, Salehinejad J, Ghafarzadegan K, Naseh A, Ghazi N. Evaluation of Estrogen and Progesterone Receptor Expression in Pyogenic Granuloma and Pregnancy Tumor of Oral Mucosa by Immunohistochemistry. J Mashhad Dent Sch. 2009; 33(1): 63-8.
15. Carr SR. High risk pregnancy: management options. JAMA. 1995;273(3):259-60. Available from: <https://jamanetwork.com/journals/jama/article-abstract/386313>
16. Creasy RK, Resnik R, Iams JD. Maternal-fetal medicine: principles and practice, 5th ed. Philadelphia: W.B. Saunders; 2004.
17. Ucan Yarkac F, Gokturk O. Pyogenic Granuloma in pregnancy: A Case Report. Biomed J Sci Tech Res. 2018; 5(1): 1-3.