









## The Effect of Iranian Propolis on Oral Mucositis Induced by X-Ray Irradiation in Rats

M. Rouhi (DDS, MS)<sup>1,2</sup> , M. Motallebnejad (DDS, MS)<sup>3</sup> , H. R. Nouri (PhD)<sup>4</sup> ,  
M. Seyedmajidi (DDS, MS)<sup>5</sup> , D. Moslemi (MD)<sup>6</sup> , A. Bijani (MD, PhD)<sup>7</sup> , S. Kazemi (PhD)<sup>4</sup> ,  
F. Asgharpour (PhD)<sup>\*4</sup> 

1. Student Research Committee, Babol University of Medical Sciences, Babol, I.R.Iran.

2. Department of Oral and Maxillofacial Medicine, School of Dentistry, Guilan University of Medical Sciences, Rasht, I.R.Iran.

3. Oral Health Research Center, Health Research Institute, Babol University of Medical Sciences, Babol, I.R.Iran.

4. Cellular and Molecular Biology Research Center, Health Research Institute, Babol University of Medical Sciences, Babol, I.R.Iran.

5. Dental Material Research Center, Health Research Institute, Babol University of Medical Sciences, Babol, I.R.Iran.

6. Department of Radiation Oncology, School of Medicine, Babol University of Medical Sciences, Babol, I.R.Iran.

7. Social Determinants of Health Research Center, Health Research Institute, Babol University of Medical Sciences, Babol, I.R.Iran.

\*Corresponding Author: F. Asgharpour (PhD)

Address: Cellular and Molecular Biology Research Center, Health Research Institute, Babol University of Medical Sciences, Babol, I.R.Iran.

Tel: +98 (11) 32190072. E-mail: f\_asgharpour@yahoo.com

### Article Type

### ABSTRACT

#### Research Paper

**Background and Objective:** Ionizing radiation has destructive effects on the oral mucosa during head and neck cancer treatment, the most common complication of which is oral mucositis. The present study was conducted to investigate the effect of Iranian propolis as a natural substance on the prevention and treatment of radiotherapy-induced oral mucositis in rats.

**Methods:** In this experimental study, 48 adult Wistar rats were randomly divided into 4 groups receiving normal saline (C), propolis 400 mg/kg (P), propolis 400 mg/kg + X-ray irradiation (PR), and normal saline + X-ray irradiation (SR). PR and SR groups were exposed to 15 Gy of X-rays. Rats were injected intraperitoneally with propolis every day (P and PR groups), and the severity of oral mucositis was recorded after irradiation using the Parkins scale until day 10. Histopathological samples were prepared from the middle third of the tongue of the rats on day 5 and 10 and were then examined.

**Findings:** The severity of mucositis increased from day 1 to day 10 in each group separately and was significantly lower in the PR group than the SR group on days 4 and 6 to 10 ( $p < 0.001$ ). The changes in the histopathological appearance of the samples in the irradiated groups were more severe than in the non-irradiated groups ( $p < 0.001$ ). Furthermore, the SR group showed the lowest body weight compared to the other groups on day 10 ( $p < 0.001$ ).

**Conclusion:** According to the results of this study, it seems that Iranian propolis plays an effective role in the treatment and control of radiotherapy-induced oral mucositis and is recommended as a suitable medicine to relieve the symptoms of mucositis and reduce oral ulcers.

**Keywords:** X-Ray, Propolis, Mouth, Mucositis.

Received:

Sep 7<sup>th</sup> 2024

Revised:

Nov 17<sup>th</sup> 2024

Accepted:

Jan 20<sup>th</sup> 2025

**Cite this article:** Rouhi M, Motallebnejad M, Nouri HR, Seyedmajidi M, Moslemi D, Bijani A, et al. The Effect of Iranian Propolis on Oral Mucositis Induced by X-Ray Irradiation in Rats. *Journal of Babol University of Medical Sciences*. 2025; 27: e73.

## Introduction

Ionizing radiation (X-rays and gamma rays) is widely used in various sciences, especially medicine, as it is used to diagnose and treat diseases such as cancer (1). In radiotherapy, healthy cells can be damaged by toxic substances produced by ionization (2, 3). Chemotherapy-induced and radiotherapy-induced oral mucositis is one of the most common and significant side effects in cancer patients (4, 5). Almost all patients who receive radiotherapy for head and neck cancers develop oral mucositis (6, 7). The severity of mucositis depends on the size of the irradiated area, the interval between irradiations, the radiation dose, the history of previous exposure, or the presence of underlying diseases such as diabetes and connective tissue diseases (8). Therefore, identifying the most effective methods to prevent or reduce the severity of radiotherapy-induced mucositis can be of great clinical importance (4).

Propolis has been extensively studied as a natural and non-toxic substance with antimicrobial, antiviral, antifungal, anticancer, and anti-inflammatory effects (9-11). Approximately 300 chemical compounds have been identified in propolis, depending on the environment and type of vegetation in the region, including resin (55%), beeswax (30%), essential oil (10%), bee pollen (5%), and organic compounds such as phenolic acids and flavonoids (5%) (10-12). In a study by Severo et al., propolis was effective in treating 5-fluorouracil (5-FU)-related oral mucositis (OM) in rats, and immunity increased on the eighth day of treatment and the level of antioxidant glutathione (GSH) increased on the fourteenth day compared to the control (13). In another study, the effect of propolis on the oral mucosa showed that the oral mucositis index (OMI) and proinflammatory markers were significantly reduced in the propolis-treated groups (14). Propolis gel was also effective as a potential topical drug to prevent radiotherapy-induced oral mucositis in patients selected for radiotherapy for oral cancer, and most patients did not develop mucositis (15). In addition, propolis mouthwash was also shown to be an effective and safe drug that can be used to reduce oral mucositis and dysphagia in patients undergoing head and neck radiotherapy (16). There are several studies in animal models regarding the beneficial effect of propolis in reducing radiotherapy-induced oral mucositis, but despite many studies, no direct and definitive treatment has been introduced yet. Therefore, the present study was conducted to investigate the effect of alcoholic extract of Iranian propolis on radiotherapy-induced oral mucositis in rats exposed to X-rays. As a natural substance rich in phenolic and flavonoid compounds, propolis was prepared from Alborz Mountains in Mazandaran Province (Polur region) (10).

## Methods

After approval by the Ethics Committee of Babol University of Medical Sciences with the code IR.MUBABOL.REC.1399.403 and in compliance with ethical guidelines, the present experimental study was conducted on 48 adult Wistar rats with a mean age of 7-11 weeks and a weight range of  $160 \pm 20$  g. The rats were kept at a temperature of  $22 \pm 2^\circ\text{C}$ , humidity of 45-55%, and a daily light/dark cycle (12/12 h) (17). The rats were randomly divided into 4 experimental groups, including 12 rats in each group:

Group 1: Normal saline (Control group, C)

Group 2: Propolis 400 mg/kg (P group)

Group 3: Propolis 400 mg/kg + X-ray irradiation (PR group)

Group 4: Normal saline + X-ray irradiation (SR group)

**Propolis preparation:** Tween 80, water, and ethanol were used to obtain a homogeneous propolis solution. To achieve a uniform mixture, propolis was mixed in 5 mL of ethanol, 10 mL of Tween 80, and distilled water on a hot plate at  $50\text{--}60^\circ\text{C}$  and stirred for six hours. Before each injection, the mixture was brought to room temperature and injected intraperitoneally (IP) into rats daily (18).

**Radiation:** A preliminary study was conducted to observe the course of radiation, the onset of radiation-induced mucositis, determine the maximum effects of radiation, and recovery from mucositis (day 10) according to the study by Molania et al. (17). Before irradiation, all rats were weighed, and the PR and SR groups assigned to radiation exposure were transferred to Shahid Rajaei Hospital in Babolsar. On the first day, rats were anesthetized with 100 mg/kg ketamine intraperitoneally and then exposed to a 15 Gy X-ray beam (Siemens 6MV, 15 Gy, 884 Mu) in a single exposure. The tube was positioned so that the entire cranium of the rats was in the radiation field (Figure 1). Two groups were irradiated (PR and SR) and two groups were not irradiated. After the irradiation, the rats were returned to the animal care center of Babol University of Medical Sciences and were weighed during the 10-day experimental period. Rats in groups P and PR were injected intraperitoneally with 400 mg/kg propolis daily, while groups C and SR were injected with normal saline (17).



**Figure 1. Preparation of the rats for X-ray irradiation**

**Oral mucositis assessment:** Daily oral mucositis assessments of rats were performed based on the PARKINZ criteria (19) by two oral pathologists separately and the results were compared. 0: normal, 0.5: light pink, 1: light red, 2: dark red, 3: localized scaling, 4: discharge and scaling in less than half of the lip, 5: discharge and scaling in more than half of the lip.

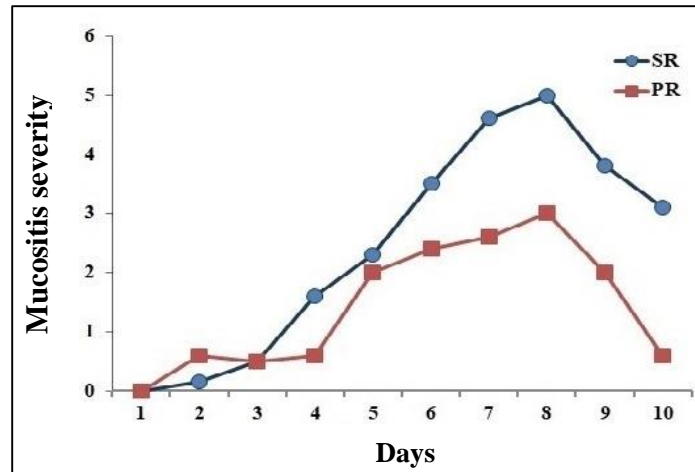
**Histopathological examination:** Half of the rats (in all four groups) were anesthetized with ketamine (100 mg/kg IP) on the fifth day and the other half on the tenth day, and tissue samples (from the middle third of the tongue) were prepared to assess the severity of mucositis, and then the rats were sacrificed by guillotine. After removing the entire rat tongue, tissue samples were prepared from the middle third of the tongue and fixed in 10% formalin (pH=7.4) for 24 hours, then paraffin blocks were prepared. Histological sections were 5 µm thick, stained with H&E, and evaluated by an oral pathologist using a 10X light microscope (Olympus BX41, Tokyo, Japan) (18). The affected areas were classified according to a five-point ordinal scale developed by Ertekin (20): 0 (normal), I (minimal,  $\geq 5\%$ ), II (mild, 6-20%), III (moderate, 21-50%), IV (marked, 51-75%), and V (severe, 76-100%).

Data analysis was performed with SPSS V.20 statistical software. One-Way ANOVA analysis and Bonferroni post hoc test were used to compare weight. Mann-Whitney was used to compare the severity of mucositis between both groups, and  $p < 0.05$  was considered significant.

## Results

Forty-eight male rats were studied over a 10-day period. Except for one rat in the SR group and two rats in the PR group that died after irradiation, the rest of the rats survived. The results of the study showed that

the severity of mucositis significantly increased from day 1 to day 10 in both the PR and SR groups ( $p<0.001$ ) (Figure 2). Moreover, by comparing the severity of mucositis between the two groups on each day of the study, it was found that the PR group showed a lower severity compared to the SR group on days 4 and 6 to 10 ( $p<0.001$ ) (Figure 2).



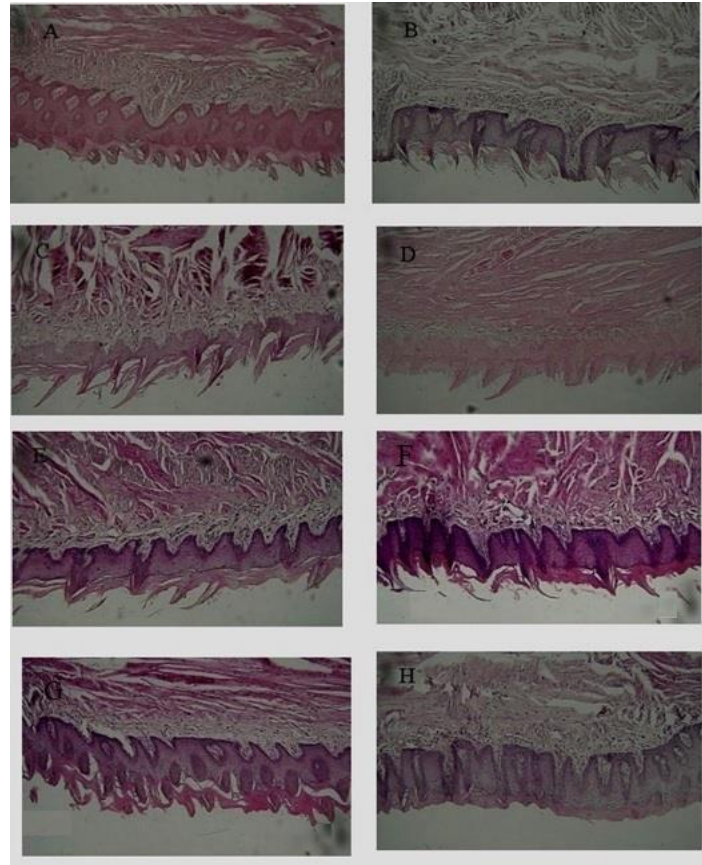
**Figure 2. Mucositis trend in SR and PR groups during the ten-day assessment**

The mean time required for the onset of mucositis in the SR group was  $6.50\pm0.5$  days and in the PR group was  $9.60\pm0.5$  days, indicating a significant difference between the two groups ( $p<0.001$ ) (Table 1). Histopathology of the tongue mucosa in the four groups on days 5 and 10 showed that the histopathological changes were more severe in the irradiated groups than in the non-irradiated groups (Figure 3). However, the severity of these changes was greater in the SR group compared to the PR group (Tables 2 and 3). Furthermore, on day 0 of the study, there was no statistically significant difference between the weight of the rats in the irradiated groups, but the SR group showed the lowest body weight on day 10 ( $p<0.001$ ) (Table 4).

**Table 1. Mean mucositis severity based on the Parkins scale on days 1 to 10 between the two radiation groups**

	SR(n=11) Mean±SD	PR(n=11) Mean±SD	p-value
Day 1	0	0	-
Day 2	0.22±0.34	0.4±0.39	0.29
Day 3	0.54±0.41	0.45±0.43	0.61
Day 4	1.72±0.64	0.7±0.34	<0.001
Day 5	2.00±0.77	1.9±0.73	0.76
Day 6	3.5±0.54	2.4±0.54	0.009
Day 7	4.66±0.51	2.0±0.54	<0.001
Day 8	5.00±0.00	3.00±0.70	<0.001
Day 9	3.83±0.75	2.00±0.70	0.003
Day 10	3.16±0.40	0.60±0.22	<0.001

Data are based on mean±standard deviation of three replicates.



**Figure 3. Histopathology of the tongue mucosa in the four groups.** A. Control group, day 5, B. P group, day 5, C. PR group, day 5, D. SR group, day 5 (reduced epithelial thickness or absence of acanthosis, hyperkeratosis, detachment of keratin from surface of papillae, submucosal inflammatory infiltrate and congested blood vessels are visible), E. Control group, day 10, F. P group, day 10, G. PR group, day 10 (detachment of keratin from the surface of the epithelium and mild inflammatory infiltrate in the submucosal area with fine blood vessels are visible), H. SR group, day 10 (atrophic changes of the papillae, degeneration of the basal layer, inflammatory infiltrate in the submucosal area with congested blood vessels are visible).

**Table 2. Comparison of changes in the histopathological appearance of the dorsal surface of the tongue on the fifth day between the study groups**

Variable	Group C Number(%)	Group P Number(%)	PR Group Number(%)	SR Group Number(%)	p-value
<b>Acanthosis</b>					
No	4(66.7)	-	5(100)	4(80)	0.001
Yes	2(33.3)	6(100)	-	1(20)	
<b>Hyperkeratosis</b>					
No	4(66.7)	-	-	-	0.005
Yes	2(33.3)	6(100)	5(100)	5(100)	
<b>Papillary changes</b>					
No	6(100)	3(50)	-	-	0.001
Yes	-	3(50)	5(100)	5(100)	
<b>Changes in the basal layer</b>					
Without change	6(100)	6(100)	-	-	<0.001
6-20%	-	-	1(20)	1(20)	
51-50%	-	-	3(60)	2(40)	



51-75%	-	-	1(20)	1(20)	
>75	-	-	-	1(20)	
<b>Congestion</b>					
Without Congestion	6(100)	6(100)	-	-	
Mild	-	-	3(60)	3(60)	<0.001
Moderate	-	-	2(40)	1(20)	
Severe	-	-	-	1(20)	
<b>Submucosal inflammation</b>					
Without inflammation	4(66.7)	5(83.3)	-	-	
Mild	2(33.3)	1(16.7)	2(40)	2(40)	0.002
Moderate	-	-	2(40)	3(60)	
Severe	-	-	1(20)	-	
<b>Damage according to Ertekin criteria</b>					
Normal	-	-	1(20)	-	<0.001
Mild	-	-	1(20)	-	
Moderate	-	-	2(40)	2(40)	
Severely symptomatic	-	-	1(20)	3(60)	

**Table 3. Comparison of changes in the histopathological appearance of the dorsal surface of the tongue on the tenth day between the study groups**

Variable	Group C Number(%)	Group P Number(%)	PR Group Number(%)	SR Group Number(%)	p-value
<b>Acanthosis</b>					
No	5(83.3)	1(16.7)	5(100)	4(66.7)	0.02
Yes	1(16.7)	5(83.3)	-	2(33.3)	
<b>Hyperkeratosis</b>					
No	5(83.3)	-	2(40)	1(16.7)	0.01
Yes	1(16.7)	6(100)	3(60)	5(83.3)	
<b>Papillary changes</b>					
No	6(100)	5(83.3)	3(60)	-	0.002
Yes	-	1(16.7)	2(40)	6(100)	
<b>Changes in the basal layer</b>					
Without change	6(100)	6(100)	-	-	<0.001
6-20%	-	-	3(60)	-	
51-50%	-	-	2(40)	4(66.7)	
51-75%	-	-	-	1(16.7)	
>75	-	-	-	1(16.7)	
<b>Congestion</b>					
Without Congestion	4(66.7)	5(83.3)	-	-	0.88
Mild	2(33.3)	1(16.7)	4(80)	4(66.7)	
Moderate	-	-	1(20)	2(33.3)	
Severe	-	-	-	-	
<b>Submucosal inflammation</b>					
Without inflammation	-	-	-	-	0.003
Mild	6(100)	5(83.3)	4(80)	-	
Moderate	-	1(66.7)	1(20)	6(100)	
Severe	-	-	-	-	
<b>Damage according to Ertekin criteria</b>					
Normal	1(16.7)	5(83.3)	-	-	0.001
Mild	5(83.3)	1(16.7)	4(80)	1(16.7)	
Moderate	-	-	1(20)	2(33.3)	
Severely symptomatic	-	-	-	3(50)	

**Table 4. Comparison of weight changes on days 0, 5, and 10 between different groups**

Groups Time period	Normal saline injection Mean±SD	Propolis injection Mean±SD	Propolis injection+radiation Mean±SD	Serum injection+radiation Mean±SD	p-value*
Day Zero	172.08±3.11	171.08±2.60	171.75±2.05	170.08±2.67	0.274
Day ten	180.16±2.22 <sup>a**</sup>	177.50±2.73 <sup>a</sup>	162.20±1.92 <sup>b</sup>	157.50±2.88 <sup>c</sup>	<0.001

\*Based on One-way ANOVA test, \*\*Dissimilar letters indicate significant differences between pairs of groups at  $\alpha=0.05$  level based on Tukey test.

## Discussion

In the present study, comparison of the severity of oral mucositis between groups showed that propolis can delay the onset of mucositis, reduce its peak, and accelerate the healing process of mucositis. Consistent with the present study, Akhavan Karbasi et al. (21) and Guler et al. (14) reported that the use of propolis can systemically reduce the severity of acute mucositis with its anti-inflammatory properties (22). This is probably due to the elimination of the infectious component of the inflammatory process, regulation of inflammatory cytokines, growth factors, and increased angiogenesis to promote wound healing (23). Moreover, a study by Hamzah et al. showed that 2.5% propolis mouthwash was effective in reducing the severity of oral mucositis and its use in nasopharyngeal carcinoma (NPC) patients did not cause any adverse side effects (24). In addition, the use of propolis mouthwash in patients with head and neck cancer was able to improve radiation-induced mucositis (16, 25). In another study, the mean incidence and severity of mucositis in the radiation control group was significantly higher than in the group receiving cinnamaldehyde (50 mg/kg) plus radiation (17). On the other hand, in the study of Tomažević et al. (26) and Salehi et al. (18), propolis did not have a positive effect on the healing process of mucositis. It seems that the dose and duration of propolis use play a significant role in the effect of this substance on the inflammatory process. Therefore, the time of assessment of the appearance of mucositis in the irradiated groups was another useful point in our study, and in this regard, it has been shown that propolis prolongs the time of appearance of mucositis, thus reducing or delaying radiation-induced mucositis.

Comparison of histopathological changes among different groups in our study showed that propolis reduced the radiation-induced tissue changes in the dorsal surfaces of the tongue. In general, chemotherapeutic and radiotherapy drugs affect the proliferation of cells with high mitotic activity, including oral mucosal cells (27) and can therefore lead to histopathological changes in oral tissues (28). Histopathological examination in the study of Salehi et al. (18) showed that propolis could reduce the degree of dysplasia at doses of 100, 200 and 400 mg/kg compared to the control, and in the group that received 400 mg/kg of propolis, only two rats showed mild dysplasia and the rest were normal. This indicates that increasing the concentration of propolis leads to a decrease in the degree of dysplasia, indicating a dose-dependent effect of propolis. Propolis varies in terms of polyphenolic and flavonoid compositions due to differences in local vegetation, and its medicinal activity varies greatly depending on its geographical origin (29).

In the assessment of weight changes in rats between the groups exposed to radiation and those without radiation, it is obvious that radiation causes a decrease in the weight of rats, which is due to a decrease in the ability to feed. In the assessment of weight changes in rats in a study by Molania et al., a significant increase was observed in the control group compared to the group receiving cinnamaldehyde (50 mg/kg). Such a weight loss was attributed to the allergic and toxic nature of cinnamaldehyde compared to normal saline injection. However, the weight change between the irradiated groups was not significant (17).

Oral mucositis can be very painful and can lead to malnutrition and significant weight loss due to inadequate oral intake. This can affect quality of life and disrupt cancer treatment protocols (23). Based on the findings of this study, it appears that Iranian propolis has an effective role in the treatment and control of radiotherapy-induced mucositis and is recommended as a suitable drug to relieve mucositis symptoms and reduce oral ulcers. Although there is no clear evidence for the direct control of mucositis despite numerous studies in this area, there are solutions in this regard and research is ongoing into the use of radioprotective agents such as propolis, but more studies are needed for preventive and supportive oral mucositis treatment.

### **Acknowledgment**

We would like to express our gratitude to the Vice Chancellor for Research and Technology of Babol University of Medical Sciences for supporting the research, as well as to the efforts of our colleagues at the Laboratory Animal Center of University, Mr. Mostafa Sheikhzadeh, and other colleagues who helped us in conducting this study.



## References

1. Aghel S, Pouramir M, Moghadamnia AA, Moslemi D, Molania T, Ghassemi L, et al. Effect of Iranian Propolis on Salivary Total Antioxidant Capacity in Gamma-irradiated Rats. *J Dent Res Dent Clin Dent Prospects*. 2014;8(4):235-9.
2. Alfouzan AF. Radiation therapy in head and neck cancer. *Saudi Med J*. 2021;42(3):247-54.
3. Wang K, Tepper JE. Radiation therapy-associated toxicity: Etiology, management, and prevention. *CA Cancer J Clin*. 2021;71(5):437-54.
4. Pulito C, Cristaudo A, Porta C, Zapperi S, Blandino G, Morrone A, et al. Oral mucositis: the hidden side of cancer therapy. *J Exp Clin Cancer Res*. 2020;39(1):210.
5. Brown TJ, Gupta A. Management of Cancer Therapy-Associated Oral Mucositis. *JCO Oncol Pract*. 2020;16(3):103-9.
6. Villa A, Sonis ST. Pharmacotherapy for the management of cancer regimen-related oral mucositis. *Expert Opin Pharmacother*. 2016;17(13):1801-7.
7. Pai RR, Ongole R, Banerjee S, Prasad K, George LS, George A, et al. Oral Care Protocol for Chemotherapy- and Radiation Therapy-Induced Oral Complications in Cancer Patients: Study Protocol. *Asia Pac J Oncol Nurs*. 2019;6(4):417-23.
8. Lorini L, Perri F, Vecchio S, Belgioia L, Vinches M, Brana I, et al. Confounding factors in the assessment of oral mucositis in head and neck cancer. *Support Care Cancer*. 2022;30(10):8455-63.
9. Asgharpour F, Moghadamnia AA, Zabihi E, Kazemi S, Ebrahimzadeh Namvar A, Gholinia H, et al. Iranian propolis efficiently inhibits growth of oral streptococci and cancer cell lines. *BMC Complement Altern Med*. 2019;19(1):266.
10. Asgharpour F, Moghadamnia AA, Kazemi S, Nouri HR, Motalebnejad M. Applying GC-MS analysis to identify chemical composition of Iranian propolis prepared with different solvent and evaluation of its biological activity. *Caspian J Intern Med*. 2020;11(2):191-8.
11. Asgharpour F, Moghadamnia AA, Kazemi S, Nouri HR, Pouramir M, Mousavi SN, et al. Chemical composition analysis and in vitro investigation of cytotoxic and antioxidative activities of Iranian propolis against breast cancer cell line, MCF-7. *ChemistrySelect*. 2018;3(39):10857-63.
12. Asgharpour F, Moghadamnia AA, Motalebnejad M, Nouri HR. Propolis attenuates lipopolysaccharide-induced inflammatory responses through intracellular ROS and NO levels along with downregulation of IL-1 $\beta$  and IL-6 expressions in murine RAW 264.7 macrophages. *J Food Biochem*. 2019;43(8):e12926.
13. Severo MLB, Thieme S, Silveira FM, Tavares RPM, Gonzaga AKG, Zucolotto SM, et al. Comparative study of royal jelly, propolis, and photobiomodulation therapies in 5-fluorouracil-related oral mucositis in rats. *Support Care Cancer*. 2022;30(3):2723-34.
14. Guler Avci G, Erdim I, Ozmen ZC, Gevrek F, Colak S, Demirsoy MS, et al. The effect of systemic application of propolis on tongue damage and oral mucositis in rats exposed to radiation. *Eur Arch Otorhinolaryngol*. 2022;279(2):1043-52.
15. Noronha VR, Araujo GS, Gomes RT, Iwanaga SH, Barbosa MC, Abdo EN, et al. Mucoadhesive propolis gel for prevention of radiation-induced oral mucositis. *Curr Clin Pharmacol*. 2014;9(4):359-64.
16. Dastan F, Ameri A, Dodge S, Hamidi Shishvan H, Pirsalehi A, Abbasinazari M. Efficacy and safety of propolis mouthwash in management of radiotherapy induced oral mucositis; A randomized, double blind clinical trial. *Rep Pract Oncol Radiother*. 2020;25(6):969-73.
17. Molania T, Moghadamnia AA, Pouramir M, Aghel S, Moslemi D, Ghassemi L, et al. The effect of Cinnamaldehyde on mucositis and salivary antioxidant capacity in gamma-irradiated rats (a preliminary study). *Daru*. 2012;20(1):89.

- 18.Salehi M, Saeedi M, Ghorbani A, Ghodrati P, Moosazadeh M, Rostamkalaei S, et al. The Effect of Propolis Tablet on Oral Mucositis Caused by Chemotherapy. *Gazi Med J*. 2018;29(3):196-201.
- 19.Parkins CS, Fowler JF, Yu S. A murine model of lip epidermal/mucosal reactions to X-irradiation. *Radiother Oncol*. 1983;1(2):159-65.
- 20.Ertekin MV, Tekin SB, Erdogan F, Karslioglu I, Gepdiremen A, Sezen O, et al. The effect of zinc sulphate in the prevention of radiation-induced dermatitis. *J Radiat Res*. 2004;45(4):543-8.
- 21.Akhavan Karbasi MH, Forat Yazdi M, Ahadian H, Jalili Sadrabad M. Evaluating Baremoom Mouthwash Efficacy in Treatment of Chemotherapy-Induced Mucositis. *J Shahid Sadoughi Uni Med Sci*. 2016;23(12):1202-14. [In Persian]
- 22.Yang J, Pi A, Yan L, Li J, Nan S, Zhang J, et al. Research Progress on Therapeutic Effect and Mechanism of Propolis on Wound Healing. *Evid Based Complement Alternat Med*. 2022;2022:5798941.
- 23.Wilkinson HN, Hardman MJ. Wound healing: cellular mechanisms and pathological outcomes. *Open Biol*. 2020;10(9):200223.
- 24.Hamzah MH, Mohamad I, Musa MY, Abd Mutalib NS, Siti-Azrin AH, Wan Omar WA. Propolis mouthwash for preventing radiotherapy-induced mucositis in patients with nasopharyngeal carcinoma. *Med J Malaysia*. 2022;77(4):462-7.
- 25.Javadzadeh Bolouri A, Pakfetrat A, Tonkaboni A, Aledavood SA, Fathi Najafi M, Delavarian Z, et al. Preventing and Therapeutic Effect of Propolis in Radiotherapy Induced Mucositis of Head and Neck Cancers: A Triple-Blind, Randomized, Placebo-Controlled Trial. *Iran J Cancer Prev*. 2015;8(5):e4019.
- 26.Tomažević T, Jazbec J. A double blind randomised placebo controlled study of propolis (bee glue) effectiveness in the treatment of severe oral mucositis in chemotherapy treated children. *Complement Ther Med*. 2013;21(4):306-12.
- 27.Gul OV, Parlak K, Yerlikaya Aydemir FH, Babalıoglu I, Ozdemir U, Koc M, et al. Protective effect of melatonin against radiobiological damage in the brain of rats exposed to low and high dose rate radiotherapy. *Radiat Phys Chem*. 2024;224:112098.
- 28.Taheri J, Razavi M, Hazhir S, Vaziri P, Bakhtiari S. Evaluation of oral hypothermia effect on prevention or reduction of chemotherapy induced mucositis symptoms. *Shahid Beheshti Dent Facul Med Univ*. 2010;3(27):146-54.
- 29.Hossain R, Quispe C, Khan RA, Saikat ASM, Ray P, Ongalbek D, et al. Propolis: An update on its chemistry and pharmacological applications. *Chin Med*. 2022;17(1):100.