

Immune Thrombocytopenic Purpura Following Acute Lymphoblastic Leukemia Treatment in a Child: A Case Report

H. Mahmoodi Nesheli (MD)^{*1}, S. Osia (MD)²

1. Non-Communicable Pediatric Disease Research Center, Health Research Institute, Babol University of Medical Sciences, Babol, I.R.Iran.

2. Clinical Research Development Unit of Amirkola Children's Hospital, Babol University of Medical Sciences, Babol, I.R.Iran.

*Corresponding Author: H. Mahmoodi Nesheli (MD)

Address: Non-Communicable Pediatric Diseases Research Center, Amirkola Children's Hospital, Amirkola, Babol, I.R.Iran.

Tel: +98 (11) 32346963. E-mail: mahmoodi86@yahoo.com

Article Type

ABSTRACT

Case Report

Background and Objective: In acute lymphoblastic leukemia, platelet counts are typically observed to be below the normal range. White blood cell counts may be within normal limits, decreased, or elevated depending on the individual case. Immune thrombocytopenia typically manifests as isolated severe thrombocytopenia. Our report presents a rare case of a child with leukemia who developed idiopathic thrombocytopenic purpura (ITP) several months after completing treatment.

Case Report: The patient is a 6-year-and-9-month-old girl who was hospitalized at Shafizadeh Children's Hospital in Amirkola, northern Iran, presenting with fever and right hip joint pain suggestive of septic arthritis. Following bone marrow aspiration, she was diagnosed with acute lymphoblastic leukemia and treatment was initiated. She achieved complete remission by the third week of therapy. Treatment continued for a total of two and a half years. Several months after the treatment, the patient referred with petechiae and purpura. Bone marrow aspiration was performed due to concern for disease relapse. The patient was subsequently diagnosed with immune thrombocytopenic purpura and received conventional treatment; however, she experienced recurrent episodes of severe thrombocytopenia at short intervals. She did not respond adequately to standard medications. Due to treatment difficulties and financial constraints, splenectomy was performed, following which the patient achieved complete remission. She has been followed for eight years and remains asymptomatic with no health problems.

Conclusion: According to the results of the present study, ITP should be taken into consideration when thrombocytopenia is detected after completing leukemia treatment.

Keywords: *Leukemia, ITP, Splenectomy, Bone pain.*

Received:

Dec 31st 2024

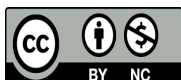
Revised:

Mar 17th 2025

Accepted:

May 5th 2025

Cite this article: Mahmoodi Nesheli H, Osia S. Immune Thrombocytopenic Purpura Following Acute Lymphoblastic Leukemia Treatment in a Child: A Case Report. *Journal of Babol University of Medical Sciences*. 2026; 28: e19.



Introduction

Acute lymphoblastic leukemia constitutes 30% of all malignancies occurring in children under 15 years of age, making it the most common childhood cancer (1). The disease may present either insidiously or acutely. Clinical symptoms can range from extensive bleeding and severe infection to fatal respiratory distress. The typical manifestations of leukemia include fever, pallor, easy bruising, petechiae, and bone pain. Bone pain is a particularly significant clinical sign that results from pressure exerted on the bone marrow space, involvement of the periosteum of the bone, or irritation of the joint capsule. This pain may manifest clinically as limping in an affected child. Involvement of other organs, such as the liver and spleen, is correlated with peripheral blood leukocyte counts and blast percentages. Platelet counts in children diagnosed with acute lymphoblastic leukemia are typically below 100,000/mm² (2, 3). In approximately 20% of affected children, the white blood cell count exceeds 50,000/mm² (4). In immune thrombocytopenia, severe thrombocytopenia with platelet counts below 20,000/mm² is characteristically present. In leukemia, thrombocytopenia is generally accompanied by other hematologic and clinical abnormalities; however, in immune thrombocytopenia, hematologic abnormalities are confined to isolated thrombocytopenia, meaning that anemia or leukocytosis is not observed (5). In chronic lymphoblastic leukemia, thrombopoietin receptors are overexpressed on T cells, leading to the activation of T cell-mediated responses (6). Ineffective treatment of immune thrombocytopenic purpura with acalabrutinib has been reported in a case associated with chronic lymphocytic leukemia (7).

The occurrence of immune thrombocytopenic purpura (ITP) following treatment for malignancies such as acute or chronic leukemia is considered a rare event (7). The specific association of ITP with acute lymphoblastic leukemia in the pediatric population has been infrequently reported in the medical literature (8). Additionally, reports documenting the coexistence of chronic lymphoblastic leukemia with ITP, as well as the effectiveness of imatinib therapy in such cases, have been described (9, 10). Thrombocytopenia may arise from various etiologies; however, in immune thrombocytopenia, an increase in platelet size as detected by complete blood count flow cytometry is a finding observed across all stages of the disease (11). Similar to many hematologic disorders including leukemia and aplastic anemia, ITP also exhibits seasonal variation, occurring with greater frequency during specific months of the year (12). Furthermore, ITP may develop in a patient with acute lymphoblastic leukemia following infection with COVID-19 (13). The reverse temporal association has also been documented, wherein an individual with a prior diagnosis of ITP subsequently developed chronic myeloid leukemia (10). Nevertheless, cases involving a child with leukemia who develops thrombocytopenia several months following the completion of antileukemic therapy, where the thrombocytopenia is confirmed to be of immune origin, have been less frequently reported. Of particular note, our patient did not demonstrate an adequate response to conventional therapeutic agents and ultimately required splenectomy. Following splenectomy, she has remained in complete remission for a period of eight years.

The primary objective of this case report is to demonstrate that the thrombocytopenia (reduced platelet count) observed in this patient was not the result of a relapse of the original leukemic disease. While it is well established that a decrease in platelet count is typically among the earliest clinical indicators of disease recurrence, this particular case proved to be an exception. The underlying cause of the thrombocytopenia in our patient was an immune-mediated reaction, which constitutes a rare and unusual clinical entity in this context.

Case Report

This study was approved by the Ethics Committee of Babol University of Medical Sciences under the ethics approval code IR.MUBABOL.REC.1404.002. The patient described in this report is a 6-year-and-9-month-old girl who initially referred to an infectious disease specialist due to fever and pain in the right hip, symptoms that had begun one day prior to presentation. In 2014, the patient was referred to and subsequently hospitalized at Shafizadeh Children's Hospital in Amirkola, northern Iran, with a suspected diagnosis of septic arthritis. The initial complete blood count (CBC) revealed the following values: WBC 5300, P 72%, L 25%, M 1.2%, Hb 8.5, PLT 170,000, ESR 36, and CRP 72. Based on these findings and the initial diagnosis, the patient received appropriate treatment. A repeat complete blood count was performed several days later, and these results are presented in Table 1.

Table 1. Patient laboratory profile

Test Type	Test Date	At admission	3 days after admission	7 days after admission
WBC		10,100	5,300	11,300
P		43	72	18
L		55%	25%	82%
M		2	1	-
EO		-	0	-
Hb		9.3	8.5	8.7
PLT		151,000	190,000	209,000
CRP		92	81	-
ESR		36	136	128

The diagnosis of leukemia is based on clinical history and presenting symptoms, and the complete blood count (CBC) serves as the key diagnostic tool for leukemia in the pediatric population. In our patient, given the clinical symptoms along with elevated CBC parameters and an elevated erythrocyte sedimentation rate (ESR), bone marrow aspiration was performed. The bone marrow examination revealed that nearly all cellular lineages consisted of lymphoblasts (Figure 1).

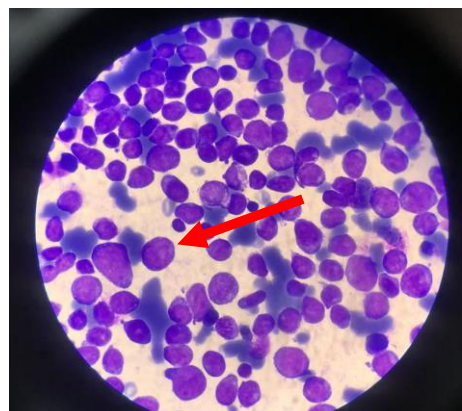


Figure 1. Acute lymphoblastic leukemia (ALL). Approximately 100% of the cellular population consists of lymphoblasts

The patient subsequently received chemotherapy with a regimen including vincristine, PEG-asparaginase, Adriamycin, cyclophosphamide, cytarabine, methotrexate, and mercaptopurine. She achieved complete remission by the third week of treatment, and therapy was continued for a total duration of two and a half years. Approximately three months after the discontinuation of her therapy, the patient presented with petechiae and purpura. Due to suspicion of disease relapse, bone marrow aspiration was performed again. Fortunately, abundant megakaryocytes were observed on bone marrow examination (Figure 2).

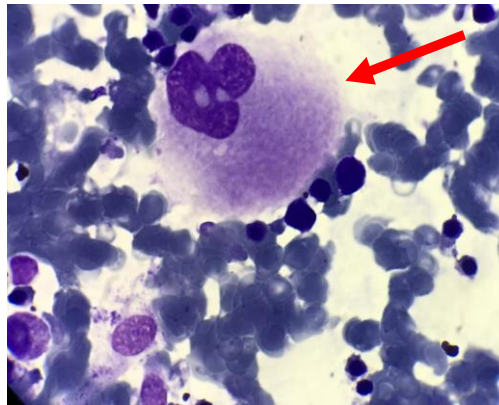


Figure 2. Immune thrombocytopenic purpura demonstrating abundant or increased megakaryocytes

The patient was diagnosed with immune thrombocytopenic purpura (ITP) and received treatment with intravenous immunoglobulin (IVIgG), following which she showed clinical improvement. Unfortunately, one month later she developed severe thrombocytopenia again and proved refractory to treatment with steroids, cyclosporine, and other immunosuppressive agents. The patient experienced recurrent episodes of severe thrombocytopenia and received additional IVIgG infusions; this relapsing pattern persisted for a duration of fourteen months. Throughout this period, evaluations for other conditions associated with thrombocytopenia in children, including systemic lupus erythematosus, were performed multiple times. Because of the high financial cost of IVIgG and the potential for greater risks associated with long-term ITP management, the patient was considered a suitable candidate for splenectomy. Prior to splenectomy, she received vaccinations against pneumococcus, meningococcus, and Haemophilus influenzae. Splenectomy was performed three years after the initiation of treatment. Over the subsequent follow-up period, the patient has remained free of acute lymphoblastic leukemia and immune thrombocytopenic purpura, and currently maintains a healthy and active status eight years post-splenectomy.

Discussion

In the patient described in this report, the observed thrombocytopenia was not the result of relapse of the underlying acute lymphoblastic leukemia. Rather, the cause of the low platelet count was immune-mediated, representing an unusual and rare clinical entity. It is generally recognized that following the completion of antileukemic therapy, the development of thrombocytopenia is typically among the earliest laboratory findings that suggest disease relapse (14).

Leukemia is the most common malignancy affecting the pediatric population, and bone and joint pain represent important clinical symptoms that should raise diagnostic suspicion. Although children presenting with bone pain must be evaluated for various infectious etiologies including brucellosis, typhoid fever, and septic arthritis, acute childhood leukemia should never be excluded from the differential diagnosis. The complete blood count (CBC) serves as the key diagnostic tool for pediatric acute leukemia. White blood cell counts may be either elevated or decreased; when the WBC count exceeds 100,000/mm³, leukemia is almost invariably present (3). However, it is crucial to recognize that this important diagnosis should still be considered even in cases where the CBC falls within normal limits. In the child described in this report, hemoglobin levels were below the normal range from the time of initial presentation, which raised clinical suspicion for leukemia. White blood cell differential analysis is also of great diagnostic importance. Although the initial laboratory evaluation demonstrated an elevated percentage of polymorphonuclear cells, the lymphocyte percentage was observed to increase on subsequent days, a finding that assisted in establishing the diagnosis. Additionally, the erythrocyte sedimentation rate (ESR) showed a gradual increasing trend. All of these laboratory findings collectively contribute to the diagnostic process. When clinical symptoms are present, further diagnostic evaluation and longitudinal follow-up are essential. In patients who experience leukemic relapse, the typical laboratory findings include leukocytosis, thrombocytopenia, and decreasing hemoglobin levels. ITP is rarely considered in this clinical context, and such occurrences have been infrequently documented in the medical literature.

The study conducted by Dokurel Çetin et al. demonstrated that the presence of thrombocytopenia persisting for more than three weeks following the achievement of remission could serve as an easily accessible hematologic parameter with potential utility in predicting disease relapse (15). However, in the patient described in our report, the observed thrombocytopenia was due to immune thrombocytopenic purpura, which represents an interesting and clinically noteworthy case. Although leukemia is typically associated with thrombocytopenia at presentation, it is worth noting that at the time of initial diagnosis in our patient, the platelet count never fell below the normal range. This finding is also of clinical interest because a normal platelet count cannot be relied upon to exclude the diagnosis of leukemia. Additionally, while splenectomy is generally not considered an appropriate or first-line procedure in the pediatric population, in high-risk circumstances where other treatment options have failed, this surgical intervention may be performed out of clinical necessity (1, 16).

It is recommended that vaccination against encapsulated bacteria (including pneumococcus, meningococcus, and Haemophilus influenzae) be administered at least two weeks prior to splenectomy (8). Although our patient has experienced no adverse complications during seven years of follow-up following the procedure, it must be emphasized that splenectomy is not among our early treatment recommendations. This surgical intervention should be performed as infrequently as possible, as splenectomy has been associated with serious and potentially life-threatening risks, including post-splenectomy sepsis and portal vein thrombosis (17, 18). Leukemia is typically associated with thrombocytopenia at presentation. In our case, however, the patient had a normal platelet count at the time of initial diagnosis. Furthermore, while thrombocytopenia occurring after completion of antileukemic therapy is usually considered a sign of disease relapse, our patient was ultimately diagnosed with immune thrombocytopenic purpura, which represents a rare clinical entity.

Ethical considerations: Written informed consent was obtained from the patient's parents prior to inclusion in this case report.

Acknowledgment

The authors hereby wish to express their sincere appreciation and gratitude to the Pediatric Non-Communicable Diseases Research Center of the Health Research Institute at Babol University of Medical Sciences, the Clinical Research Development Unit of Amirkola Children's Hospital, the esteemed staff of the hospital (with special thanks to Ms. Fariba Khabiri), and the patient's family for their invaluable cooperation and support in conducting this study.

References

- 1.Chater C, Terriou L, Duhamel A, Launay D, Chambon JP, Pruvot FR, et al. Reemergence of Splenectomy for ITP Second-line Treatment?. *Ann Surg.* 2016;264(5):772-7.
- 2.Kourti A, Dimopoulou A, Zavras N, Sakellariou S, Palamaris K, Kanavaki I, et al. Inflammatory fibroid polyp of the anus in a 12-month-old girl: Case report and review of the literature. *J Paediatr Child Health.* 2022;58(8):1313-6.
- 3.Blaney SM, Adamson PC, Helman LJ. *Pizzo and Poplack's Pediatric Oncology*, 8th ed. Wolters Kluwer Health; 2021. p. 420.
- 4.Mitura-Lesiuk MM, Dubaj M, Dembowska A, Bigosiński K, Raniewicz M. Hyperleukocytosis in Pediatric Patients with Acute Lymphoblastic Leukemia: Demographic and Clinical Characteristics. *J Clin Med.* 2024;13(17):5185.
- 5.Cooper N, Ghanima W. Immune Thrombocytopenia. *N Engl J Med.* 2019;381(10):945-55.
- 6.Huang MZ, Wang SX, Li F. [Immune Thrombocytopenia in Patients with Chronic Lymphocytic Leukemia: Pathological Mechanism and Treatment Progress---Review]. *Zhongguo Shi Yan Xue Ye Xue Za Zhi.* 2021;29(5):1671-5. [Chinese]
- 7.O'Connor-Byrne N, Quinn J, Glavey SV, Lavin M, Brett F, Murphy PT. Venetoclax for chronic lymphocytic leukemia associated immune thrombocytopenia following recovery from progressive multifocal leukoencephalopathy. *Leukemia research.* 2020;95:106390.
- 8.Shahrabi S, Behzad MM, Jaseb K, Saki N. Thrombocytopenia in leukemia: Pathogenesis and prognosis. *Histol Histopathol.* 2018;33(9):895-908.
- 9.Nakamura Y, Itoh Y, Wakimoto N. Improvement of immune thrombocytopenia with imatinib therapy following chronic myeloid leukemia. *Int J Hematol.* 2023;117(4):613-7.
- 10.Autore F, Sora' F, Chiusolo P, Minnella G, Colangelo M, Rossi E, et al. Chronic Myeloid Leukemia in a Patient with Previous Idiopathic Thrombocytopenic Purpura: How to Manage Imatinib Together with Eltrombopag. *Medicina (Kaunas).* 2021;57(12):1326.
- 11.Jachiet V, Moulis G, Hadjadj J, Segquier J, Laribi K, Schleinitz N, et al. Clinical spectrum, outcome and management of immune thrombocytopenia associated with myelodysplastic syndromes and chronic myelomonocytic leukemia. *Haematologica.* 2021;106(5):1414-22.
- 12.Hassan J, Adil SO, Haider Z, Zaheer S, Anwar N, Nadeem M, et al. Seasonal variations in hematological disorders: A 10-year single-center experience. *Int J Lab Hematol.* 2021;43(1):93-8.
- 13.Dongre A, Jameel PZ, Deshmukh M, Bhandarkar S. Immune thrombocytopenic purpura secondary to SARS-CoV-2 infection in a child with acute lymphoblastic leukaemia: a case report and review of literature. *BMJ Case Rep.* 2021;14(11):e245869.
- 14.Neunert CE. Management of newly diagnosed immune thrombocytopenia: can we change outcomes?. *Hematology Am Soc Hematol Educ Program.* 2017;2017(1):400-5.
- 15.Dokurel Çetin İ, Özdemir N, Celkan TT, Erdogan S, Apak H. The Probable Suspect in the Prediction of Relapse in Acute Leukemia: Thrombocytopenia. *Van Med J.* 2022;29(1):27-35.
- 16.Chaturvedi S, Arnold DM, McCrae KR. Splenectomy for immune thrombocytopenia: down but not out. *Blood.* 2018;131(11):1172-82.
- 17.Hassan MN, Tahereb GM, Ahmad T, Asghar DA, Reza ED, Ali B, et al. Correlation of splenectomy with portal vein thrombosis in beta-thalassemia major. *J Pak Med Assoc.* 2011;61(8):760-2.
- 18.Tahir F, Ahmed J, Malik F. Post-splenectomy Sepsis: A Review of the Literature. *Cureus.* 2020;12(2):e6898.