



## Axillary Vein Spasm during Real-time Venography-Guided Puncture for Cardiac Electronic Device Implantation

A. J. J. al-Gburi (MD)\*1

1. Department of Medicine, College of Medicine, al-Mustansiriyah University, Baghdad, Iraq.

Article Type	ABSTRACT
Research Paper	<p><b>Background and Objective:</b> There are an increasing number of cardiac electronic device implantation with an expansion of their indications. Axillary vein puncture guided by contrast venography has grown in popularity due to its effectiveness and low complication rate. Venous spasm has been reported previously. The aim of this study was to determine the rate of axillary venous spasms during real-time contrast venography-guided puncture as well as its effect on puncture success.</p> <p><b>Methods:</b> In this cross-sectional study, 137 consecutive patients admitted for permanent pacemaker or implantable cardioverter-defibrillator implantation utilizing real-time contrast venography were included in the study. After the success of puncture or a period of five minutes had been passed, the venography was repeated. Axillary venous spasm is characterized by a luminal diameter reduction of more than 50%. Grade I (50-90%) and Grade II (&gt;90%) spasm were classified as a percentage decrease in luminal diameter.</p> <p><b>Findings:</b> The axillary venous puncture within five minutes was successfully done in 124 patients (90.5%) and was done using the subclavian access in the others. The overall incidence of axillary venous spasm more than 50% was 33.6% (46 patients; 32 female and 14 male). Grade I spasm was observed in 38 patients (27.8%) and Grade II spasm observed in 8 patients (5.8%). Successful puncture within five minutes was significantly less in patients with venous spasm (37 (80.4%) vs 87 (95.6%), <math>p=0.010</math>).</p> <p><b>Conclusion:</b> According to the results of this study, spasm of the axillary vein is not uncommon during real-time contrast venography-guided axillary venous puncture and occurs more in older age and females and it has a significant unfavorable impact on puncture duration, the number of attempts, and puncture success.</p> <p><b>Keywords:</b> <i>Axillary Vein Spasm, Venography, Cardiac Electronic Device, Cardiac Implantable Electronic Device, Pacemaker, Implantable Cardioverter-Defibrillator.</i></p>
Received: May 27 <sup>th</sup> 2022	
Revised: Sep 19 <sup>th</sup> 2022	
Accepted: Oct 18 <sup>th</sup> 2022	

**Cite this article:** al-Gburi AJJ. Axillary Vein Spasm during Real-time Venography-Guided Puncture for Cardiac Electronic Device Implantation. *Journal of Babol University of Medical Sciences*. 2023; 25(1): 10-9.



© The Author(S).

Publisher: Babol University of Medical Sciences

\*Corresponding Author: A. J. J. al-Gburi (MD)

Address: Department of Medicine, College of Medicine, al-Mustansiriyah University, Baghdad, Iraq.

Tel: +964 (01) 5413485. E-mail: abdulamerjasim@gmail.com

## Introduction

The last decades have witnessed an increasing number of cardiac electronic device implantations with an expansion of their indications (1). Most of these procedures are done through percutaneous transvenous technique.

Access to the central veins is an important first step in the implantation procedure which is done by cephalic vein cut-down or subclavian veins and axillary puncture techniques (2-7). The complication rates of inadvertent arterial injury, hemothorax, and pneumothorax are relatively higher in subclavian puncture compared with other techniques (8, 9). Also, lead fractures sometimes occur in the space between the clavicle and first rib "Subclavian crush syndrome" (10). Cephalic venous cut-down has a lower success rate and takes more time (11, 12). For all these reasons, numerous institutions have increased their use of the axillary venous route.

For almost 30 years, the axillary vein has been utilized to implant pacemaker leads (13-17). Axillary vein puncture guided by contrast venography was reported lately and has grown in popularity due to its increased effectiveness and low complication rate (4, 5, 18). In comparison to the conventional contrast venography method by storing and using the venogram as a roadmap on the reference monitor, the use of real-time contrast venography had been found to be beneficial for implantation procedures, particularly for less experienced implanters with fewer puncture attempts (19).

Venous spasm was detected on a few occasions during contrast venography-guided axillary vein puncture (20-22) and was recognized as a prevalent event (23). It has a detrimental impact on the success of venous puncture (23, 24).

Injuries to the vein's surrounding tissues and the vein wall may elicit a vascular spasm as a reflex phenomenon. In severe cases, this might result in full obliteration of the vein, complicating the procedure's progress and perhaps resulting in subsequent adverse events (23, 25). The smooth muscle layer of the vascular wall (tunica media) has a role in this response (26). Several causes may contribute to this phenomenon, including mechanical venous damage (lead insertion and venous puncture) and surrounding tissue compression, thermal changes, and chemical triggers (contrast agents) (20, 23).

There is a paucity of published data on axillary venous spasm during pacemaker and defibrillator implantation. The objective of this research was to determine the rate of axillary venous spasms during real-time contrast venography-guided puncture of the axillary vein for cardiac electronic device lead placement, as well as its effect on the puncture success.

## Methods

This cross-sectional study was conducted from January 2021 to April 2022 among 137 consecutive patients admitted for permanent pacemaker or implantable cardioverter-defibrillator implantation utilizing real-time contrast venography-guided axillary vein puncture. The study was done in Ibn al-Bitar Specialized Center for Cardiac Surgery in Baghdad, Iraq. Demographic, clinical, and investigation data were obtained. These include age, sex, smoking status, Body Mass Index, medication use, blood pressure, Glomerular Filtration Rate (27), hemoglobin, ejection fraction, presence of hypertension (28), diabetes (29), coronary artery disease, and indications for device implantation. We excluded patients with a history of significant contrast allergy, patients with significant venous anomalies, and those on dialysis or those who had a previous ipsilateral or contralateral implanted device. The research was conducted in compliance with

the Declaration of Helsinki and its later revisions and 31 codes of ethics in the Islamic Republic of Iran and with the approval of the local ethics committee with the code REG0501/2021. All patients provided their informed consent.

The procedure was done using a standard sterile technique with hemodynamic and ECG monitoring. Initially, the application of local anesthesia was done using lidocaine. Venography was conducted using C-arm fluoroscopy (Philips Allura Xper) in anteroposterior (AP) projection at 7.5 frames per second by administering 5-10 mL of Iodixanol contrast agent via the ipsilateral antecubital venous access followed by flushing with 20 mL of saline. In the real-time approach, the middle of the axillary vein was targeted and punctured using an 18-gauge needle with continuous negative pressure application by syringe under fluoroscopic monitoring in the AP view. The needle trajectory was toward the first rib to avoid pneumothorax (30). The contrast-enhanced images of the axillary and subclavian veins were also saved on the reference display. The operator was free to decide the quantity of contrast agent and acquisition of another venography. Then the procedure continued with the introduction of a 0.035-inch guidewire and further steps according to standard techniques. Another venous puncture may be needed according to the number of leads needed. When more than five minutes passed and all attempts failed, switching to subclavian access was done.

After the success of puncture or a period of five minutes had been passed, the venography was repeated. The puncture time was determined as the period from the needle skin penetration to the guidewire venous entrance for each lead. The number of attempts is the number of needle skin punctures per patient (single or dual leads). The type of device implanted, the use of temporary pacing, the implantation side, and the total amount of contrast used were documented. Serum creatinine, bedside echocardiography, ECG, and chest X-ray were done the next day after the procedure. All significant complications during or after puncture were documented.

Venograms of the axillary vein before and after the puncture were studied offline. Venous spasm degree was measured by the decrease in the luminal diameter of the axillary vein following puncture, using a quantitative method which is expressed as a percentage narrowing in diameter from the second venogram in comparison to the baseline venogram (23). Axillary venous spasm is characterized by a luminal diameter reduction of more than 50%. Grade I (50-90%) and Grade II (>90%) spasms were classified as a percentage decrease in luminal diameter.

**Statistical analysis:** Normally distributed continuous variables were represented as mean with standard deviation as a measure of dispersion and compared across groups using the unpaired Student's t-test. The non-parametric Mann-Whitney test was used to compare continuous, non-normally distributed data and represented as median and interquartile range. Categorical variables were represented as a number (with percentages) and Fisher's Exact Test was used to compare groups. Statistical significance was defined as a p-value of less than 0.05. Statistical Package for the Social Sciences (SPSS) Version 26.0 for Windows (SPSS Inc., Chicago, IL, USA) was used for conducting the analysis.

## Results

The study population consists of 137 patients (age  $70.38 \pm 11.97$  years, 77 females). The axillary venous puncture within five minutes was successfully done in 124 patients (90.5%) and was done using the subclavian access in the others. All patients had successful venous access and device placement. The mean age of patients experiencing axillary venous spasm was higher than those without it ( $73.33 \pm 9.18$  years vs  $68.89 \pm 12.95$  years,  $p=0.040$ ) and patients were more likely to be over 70 years ( $32/46$  (69.6%) vs

33/91 (36.3%),  $p < 0.001$ ) and to be females (32/46 (69.6%) vs 45/91 (49.5%),  $p = 0.029$ ). In terms of patient characteristics, device indications, laboratory findings, and ejection fraction, no significant differences were observed between the groups as shown in Table 1.

The percentage decrease in axillary vein luminal diameter after puncture was  $45.71 \pm 19.15\%$ . The overall incidence of axillary venous spasm more than 50% was 33.6% (46 patients; 32 females and 14 males). Grade I (50-90%) venous spasm was observed in 38 patients (27.8%) and Grade II (>90%) venous spasm was observed in 8 patients (5.8%). Successful puncture within five minutes was significantly less in patients with venous spasm (37/46 (80.4%) vs 87/91 (95.6%),  $p = 0.010$ ). In situations when axillary vein puncture failed, subclavian vein puncture was successful in all patients with no evidence of venous spasm seen within it.

The puncture duration (Per Lead) and the number of attempts (Per Patient) were significantly higher in patients with axillary venous spasm than in those without spasm (72.47 s [58.67-81.53] vs 37.92 s [30.87-46.72],  $p < 0.001$  and  $4.54 \pm 2.16$  vs  $3.34 \pm 1.76$ ,  $p = 0.001$ , respectively). There is no significant difference in the side of implantation, the use of a temporary pacemaker, contrast volume, complications, and device types between the two groups as shown in Table 2. The percentage of different degrees of axillary venous spasm with their sex distribution were shown in Figure 1.

**Table 1. Comparison between patients who develop axillary venous spasm and those without spasm regarding baseline characteristics and device indications**

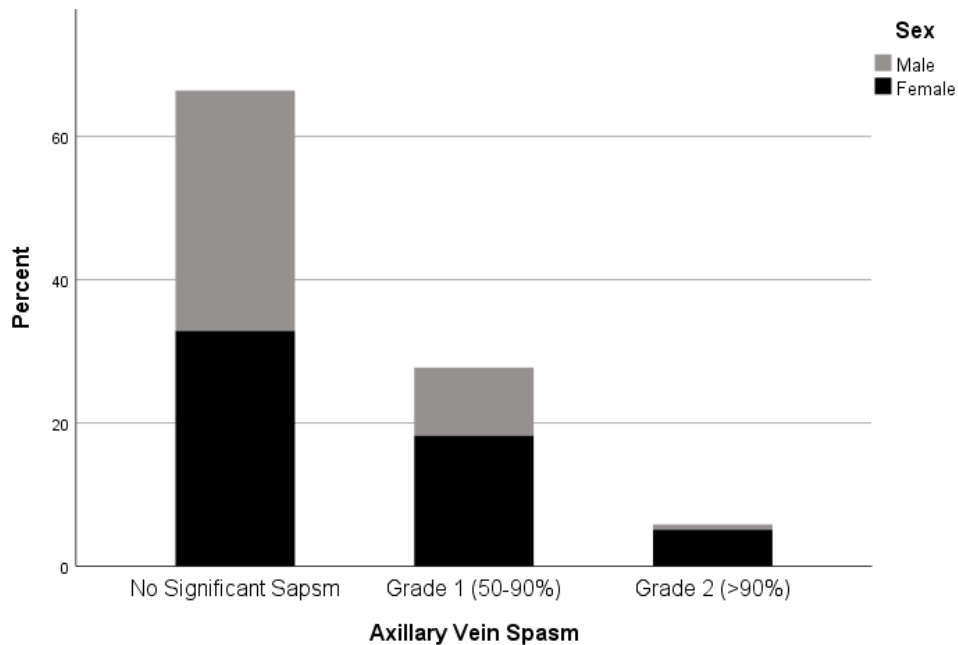
	No Spasm, n=91 (66.4%) Mean±SD or Number(%)	Spasm, n=46 (33.6%) Mean±SD or Number(%)	p-value
<b>History and examination findings</b>			
Age, years	68.89±12.95	73.33±9.18	<b>0.040</b>
Age>70 Years	33(36.3)	32(69.6)	<b>&lt;0.001</b>
Female	45(49.5)	32(69.6)	<b>0.029</b>
Hypertension	72(79.1)	36(78.3)	1.000
Diabetes	18(19.8)	10(21.7)	0.824
Smoking	19(20.9)	17(37.0)	0.063
Coronary Artery Disease	52(57.1)	31(67.4)	0.272
Use of Nitrate	7(7.7)	4(8.7)	1.000
Use of Calcium Channel Blockers	14(15.4)	8(17.4)	0.808
Body Mass Index (BMI), kg/m <sup>2</sup>	22.80±6.13	23.96±7.67	0.338
Systolic Blood Pressure, mmHg	126.43±28.34	125.08± 27.22	0.790
Diastolic Blood Pressure, mmHg	75.35±17.58	69.14±19.62	0.063
<b>Investigation findings</b>			
Baseline eGFR, ml/min/1.73 m <sup>2</sup>	52.12±22.32	50.58±20.81	0.698
Hemoglobin, g/dL	12.44±1.86	12.33±1.62	0.725
Atrial Fibrillation	10(11.0)	6(13.0)	0.781
LV Ejection Fraction, %	41.10±22.28	40.35±24.21	0.856
<b>Device indication</b>			
Sinus Node Dysfunction (SND)	19(20.9)	10(21.7)	0.870
Atrioventricular block	45(49.5)	19(41.3)	
Ventricular Tachycardia	11(12.1)	6(13.0)	
Heart Failure	7(7.7)	4(8.7)	
Others	9(9.9)	7(15.2)	

**Abbreviation:** eGFR: estimated Glomerular Filtration Rate, LV: Left Ventricular.

Significance is denoted by bold font.

**Table 2. Comparison between patients who develop axillary venous spasm and those without spasm regarding procedural characteristics, complications, and device type**

	No Spasm, n=91 (66.4%) Mean±SD or Number(%)	Spasm, n=46 (33.6%) Mean±SD or Number(%)	p-value
<b>Procedural characteristics</b>			
Degree of lumen diameter reduction, %	34.68±10.64	67.53±12.25	< <b>0.001</b>
Axillary Venous Access Success within 5 min	87(95.6)	37(80.4)	<b>0.010</b>
Puncture Duration (Per Lead), s	37.92 (30.87-46.72)	72.47 (58.67-81.53)	< <b>0.001</b>
Number of attempts (Per Patient)	3.34±1.76	4.54±2.16	<b>0.001</b>
Right Sided Access	6(6.6)	5(10.9)	0.507
Temporary Pacing	35(38.5)	21(45.7)	0.464
Contrast Volume, mL	17.43±5.67	16.84±6.22	0.581
<b>Complications</b>			
Inadvertent Artery Puncture	5(5.5)	7(15.2)	0.105
Pneumothorax	2(2.2)	3(6.5)	0.334
Pocket Hematoma	1(1.1)	1(2.2)	1.000
<b>Device type</b>			
Dual-chamber pacemaker	73(80.2)	33(71.7)	0.319
Single-chamber pacemaker	9(9.9)	4(8.7)	
Dual-chamber ICD	5(5.5)	3(6.5)	
Single-chamber ICD	4(4.4)	6(13.0)	
<b>Abbreviation:</b> eGFR: estimated Glomerular Filtration Rate, ICD: Implantable Cardioverter-Defibrillator. Significance is denoted by bold font.			

**Figure 1. Percentage of different grades of axillary vein spasm with their sex distribution**

## Discussion

The current research reveals that venous spasm was not uncommon (33.6%) during real-time venography-guided puncture of the axillary vein. Grade I spasm was observed in 27.8% and Grade II spasm observed in 5.8%. Failure of axillary vein puncture within five minutes is significantly associated (80.4% vs 95.6%,  $p=0.010$ ) with the presence of venous spasm (>50% decrease in lumen diameter). The mean age of patients experiencing axillary venous spasm was higher than those without it and patients were more likely to be aged over 70 years and to be females. The puncture duration and the number of attempts were significantly higher while successful puncture within five minutes was significantly less in patients with venous spasm.

Vascular spasm may result in a temporary, full occlusion of blood flow. Generally, the condition resolves on its own without intervention or consequences. Nevertheless, axillary vein spasms that occur during the device implantation might significantly alter its outcome. This may lead to insertion of the leads through a subclavian puncture or switching to the other side of the chest (22).

Venous spasm developing during other procedures and veins also had been reported (31-36). Rarely has venous spasm been described after axillary vein puncture (20-22). In our research, however, the venous spasm was not uncommon. These findings may be explained by the use of venography in all patients in this study unlike previous practice which use it selectively and many patients might develop spasm but goes undetected with success after many attempts or switching to subclavian vein without venography. Patients experiencing axillary venous spasm were older and were more likely to be above 70 years of age than those without it. Hence, aging may increase the risk of axillary venous spasm. Prior research reports the occurrence of mild (50-90%) venous spasm in 29.7% and severe (>90%) venous spasm in 8.1% with the mean degree of spasm was  $38.5\pm 28.1\%$  (23). Severe venous spasm is an independent risk factor for difficult and failed axillary venous puncture. The current study shares some similar findings to this previous study. In another study done by Steckiewicz et al. (24), axillary vein spasm was observed in 12 patients (3%) (age  $57\pm 25$  years) out of 403 patients and severe spasm had a significant effect on the procedure. They found a full obstruction of contrast flow through the axillary vein, with preserved flow through the cephalic vein or collateral veins, followed by a resumption of flow. Contrast-enhanced venous wall motions demonstrated that the spasm propagated both proximally and distally throughout the vein, with subsequent venous wall relaxation occurring synchronously along the spasm-affected venous segment.

The success rate of venography-guided axillary venous puncture ranged between 95 and 98% as shown in many prior investigations (4, 5, 18) and specifically in real-time technique (19). The success rate of axillary vein puncture in our research was 90.5% within 5 minutes. Overall, a venous puncture for lead insertion and device implantation was successful in all patients after the use of subclavian access in failed axillary vein puncture. A success rate of 95.9% had been reported by Duan et al (23). Ramza et al. (4) conducted the first study of contrast-guided axillary vein puncture for implanting pacemaker and defibrillator leads with puncture success rate of 98%. In another study of patients undergoing biventricular pacing, a successful puncture was achieved in 34/35 (97.1%) patients with one patient's vein being too small (5). In another larger report of 142 patients, the success rate was 95% and the failure cause was not reported (18). Due to venous spasm, the axillary vein puncture was difficult or even unsuccessful in a few case reports (20-22, 37, 38). In the current study, axillary venous spasm occurred more in patients with failed puncture within five minutes.

Intravenous nitroglycerine had been reported to have a preventative effect in one study (39), but not in a case report(20). Sedatives (benzodiazepines) may prevent or reduce the duration of venous spasms. The spasm usually resolves gradually and spontaneously (21, 39). There is a need for future studies regarding

the optimal dose of nitroglycerine and the effectiveness of other vasodilators like calcium channel blockers as prophylactic and therapeutic agents.

**Limitations:** This is a single-center study that includes a small number of patients. Grade I spasm and Grade II spasm were determined based on past research (23, 39), not on a guideline or consensus. It is difficult to totally eliminate the effect of extrinsic compression caused by a local hematoma.

Although real-time contrast venography-guided axillary vein puncture has an excellent success rate, there are still some patients has challenging or even unsuccessful puncture. Spasm of the axillary vein is not uncommon during contrast-guided venous puncture, and it has a significant unfavorable impact on the puncture success and procedure progress.

### **Acknowledgment**

I gratefully thank the personnel (LAH and HRA) at the Ibn al-Bitar Specialized Center for Cardiac Surgery for their support.

## References

1. Glikson M, Nielsen JC, Kronborg MB, Michowitz Y, Auricchio A, Barbash IM, et al. 2021 ESC Guidelines on cardiac pacing and cardiac resynchronization therapy. *Eur Heart J*. 2021;42(35):3427-520.
2. Chan NY, Kwong NP, Cheong AP. Venous access and long-term pacemaker lead failure: comparing contrast-guided axillary vein puncture with subclavian puncture and cephalic cutdown. *Europace*. 2017;19(7):1193-7.
3. Shimada H, Hoshino K, Yuki M, Sakurai S, Owa M. Percutaneous cephalic vein approach for permanent pacemaker implantation. *Pacing Clin Electrophysiol*. 1999;22(10):1499-501.
4. Ramza BM, Rosenthal L, Hui R, Nsah E, Savader S, Lawrence JH, et al. Safety and Effectiveness of Placement of Pacemaker and Defibrillator Leads in the Axillary Vein Guided by Contrast Venography. *Am J Cardiol*. 1997;80(7):892-6.
5. Chan NY, Liem LB, Mok NS, Wong W. Clinical experience of contrast venography guided axillary vein puncture in biventricular pacing R1. *Int J Cardiol*. 2003;92(1):55-8.
6. Belott P. How to access the axillary vein. *Heart Rhythm*. 2006;3(3):366-9.
7. Steckiewicz R, Świętoń E, Stolarz P, Grabowski M. Clinical implications of cephalic vein morphometry in routine cardiac implantable electronic device insertion. *Folia Morphol (Warsz)* 2015;74(4):458-64.
8. Parsonnet V, Bernstein AD, Lindsay B. Pacemaker-implantation complication rates: An analysis of some contributing factors. *J Am Coll Cardiol*. 1989;13(4):917-21.
9. Kirkfeldt RE, Johansen JB, Nohr EA, Moller M, Arnsbo P, Nielsen JC. Pneumothorax in cardiac pacing: a population-based cohort study of 28,860 Danish patients. *Europace*. 2012;14(8):1132-8.
10. Magney JE, Flynn DM, Parsons JA, Staplin DH, Chin-Purcell MV, Milstein S, et al. Anatomical mechanisms explaining damage to pacemaker leads, defibrillator leads, and failure of central venous catheters adjacent to the sternoclavicular joint. *Pacing Clin Electrophysiol*. 1993;16(3 Pt 1):445-57.
11. Calkins H, Ramza BM, Brinker J, Atiga W, Donahue K, Nsah E, et al. Prospective randomized comparison of the safety and effectiveness of placement of endocardial pacemaker and defibrillator leads using the extrathoracic subclavian vein guided by contrast venography versus the cephalic approach. *Pacing Clin Electrophysiol*. 2001;24(4 Pt 1):456-64.
12. Tse HF, Lau CP, Leung SK. A cephalic vein cutdown and venography technique to facilitate pacemaker and defibrillator lead implantation. *Pacing Clin Electrophysiol*. 2001;24(4 Pt 1):469-73.
13. Franco E, Rodriguez Muñoz D, Matía R, Hernandez-Madrid A, Carbonell San Román A, Sánchez I, et al. Wireless Ultrasound-Guided Axillary Vein Cannulation for the Implantation of Cardiovascular Implantable Electric Devices. *J Cardiovasc Electrophysiol*. 2016;27(4):482-7.
14. Beig JR, Ganai BA, Alai MS, Lone AA, Hafeez I, Dar MI, et al. Contrast venography vs. microwire assisted axillary venipuncture for cardiovascular implantable electronic device implantation. *Europace*. 2018;20(8):1318-23.
15. Migliore F, Fais L, Vio R, De Lazzari M, Zorzi A, Bertaglia E, et al. Axillary vein access for permanent pacemaker and implantable cardioverter defibrillator implantation: Fluoroscopy compared to ultrasound. *Pacing Clin Electrophysiol*. 2020;43(6):566-72.
16. Garcia-Rinaldi RF. Insertion of the lead of a permanent transvenous pacemaker utilizing an axillary approach. A solution to the unsuitable cephalic vein. *Chest*. 1978;73(4):561.
17. Davis L, Chik W, Kumar S, Sivagangabalan G, Thomas SP, Denniss AR. Axillary vein access using ultrasound guidance, Venography or Cephalic Cutdown-What is the optimal access technique for insertion of pacing leads?. *J Arrhythm*. 2021;37(6):1506-11.



18. Burri H, Sunthorn H, Dorsaz PA, Shah D. Prospective study of axillary vein puncture with or without contrast venography for pacemaker and defibrillator lead implantation. *Pacing Clin Electrophysiol.* 2005;28(Suppl 1):S280-3.
19. Kashiwagi M, Katayama Y, Kuroi A, Taruya A, Terada K, Tanimoto T, et al. Real-time venography-guided extrathoracic puncture technique for cardiovascular implantable electronic device implantation. *Heart Vessels.* 2022;37(1):91-8.
20. Chan NY, Leung WS. Venospasm in contrast venography-guided axillary vein puncture for pacemaker lead implantation. *Pacing Clin Electrophysiol.* 2003;26(1 Pt 1):112-3.
21. Cooper RM, Krishnan U, Pyatt JR. Central venous spasm during pacemaker insertion. *Heart.* 2010;96(18):1484.
22. Duan X, Ling F, Shen Y, Xu HY. Venous spasm during pacemaker implantation. *Anadolu Kardiyol Derg.* 2011;11(6):E24.
23. Duan X, Ling F, Shen Y, Yang J, Xu HY. Venous spasm during contrast-guided axillary vein puncture for pacemaker or defibrillator lead implantation. *Europace.* 2012;14(7):1008-11.
24. Steckiewicz R, Górko D, Świętoń EB, Szparecki G, Stolarz P. Axillary vein spasm during cardiac implantable electronic device implantation. *Folia Morphol (Warsz).* 2016;75(4):543-9.
25. Jacobs DM, Fink AS, Miller RP, Anderson WR, McVenes RD, Lessar JF, et al. Anatomical and morphological evaluation of pacemaker lead compression. *Pacing Clin Electrophysiol.* 1993;16(3 Pt 1):434-44.
26. Charles AK, Gresham GA. Histopathological changes in venous grafts and in varicose and non-varicose veins. *J Clin Pathol.* 1993;46(7):603-6.
27. Khwaja A. KDIGO clinical practice guidelines for acute kidney injury. *Nephron Clin Pract.* 2012;120(4):c179-84.
28. Whelton PK, Carey RM, Aronow WS, Casey DE, Collins KJ, Dennison Himmelfarb CD, et al. 2017 ACC/AHA/AAPA/ABC/ACPM/AGS/APhA/ASH/ASPC/NMA/PCNA Guideline for the Prevention, Detection, Evaluation, and Management of High Blood Pressure in Adults: A Report of the American College of Cardiology/American Heart Association Task Force on Clinical Practice Guidelines. *Hypertension.* 2018;71(6):1269-324.
29. American Diabetes Association Professional Practice Committee. 2. Classification and Diagnosis of Diabetes: Standards of Medical Care in Diabetes-2022. *Diabetes Care.* 2022;45(Suppl 1):S17-S38.
30. Byrd CL. Clinical experience with the extrathoracic introducer insertion technique. *Pacing Clin Electrophysiol.* 1993;16(9):1781-4.
31. Guragai N, Rampal U, Vasudev R, Patel H, Joshi MB, Shamoof F. A rare case of late onset saphenous vein graft spasm. *J Community Hosp Intern Med Perspect.* 2017;7(5):332-5.
32. Steckiewicz R, Świętoń EB, Bogdańska M, Stolarz P. Vasoconstrictive responses of the cephalic vein during first-time cardiac implantable electronic device placement. *Folia Morphol (Warsz).* 2018;77(3):464-70.
33. Wennevold A, Christiansen I, Lindeneg O. Complications in 4,413 catheterizations of the right side of the heart. *Am Heart J.* 1965;69(2):173-80.
34. Barber CJ. Central venous catheter placement for intravenous digital subtraction angiography: an assessment of technical problems and success rate. *Br J Radiol.* 1989;62(739):599-602.
35. Wall JL, Kierstead VL. Peripherally inserted central catheters: resistance to removal: a rare complication. *J Intraven Nurs.* 1995;18(5):251-4.
36. Cunningham E, Korbon GA. Venospasm preventing peripheral venous access. *Anesthesiology.* 1983;59(2):141-2.
37. Krishnappa D, Sakaguchi S, Kasinadhuni G, Tholakanahalli VN. An unyielding valve leading to venous spasm during pacemaker implantation: a case report. *Eur Heart J Case Rep.* 2019;3(4):1-4.

- 38.Vemuri KS, Parashar N, Bootla D, Revaiah PC, Kanabar K, Nevali KP, et al. Refractory axillary venous spasm during permanent pacemaker implantation. *Egypt Heart J.* 2020;72(1):71.
- 39.Duan X, Ling F, Shen Y, Yang J, Xu HY, Tong XS. Efficacy and safety of nitroglycerin for preventing venous spasm during contrast-guided axillary vein puncture for pacemaker or defibrillator leads implantation. *Europace.* 2013;15(4):566-9.