Journal of
Babol University of Medical Sciences
JBUMS
e-ISSN: 2251-7170 p-ISSN: 1561-4107

The Correlation between Predictive Factors and Intravitreal Bevacizumab Therapy Outcomes in Central Retinal Vein Occlusion

S. A. Rasoulinejad (MD)[*1], F. Maroufi (BSc)[2], A. Alizadeh (PhD)[3]

1.Department of Ophthalmology, School of Medicine, Babol University of Medical Sciences, Babol, IR.Iran.

2.Department of Medical Laboratory Sciences, School of Allied Medical Sciences, Qazvin University of Medical Sciences, Qazvin, I.R.Iran.

3.Metabolic Diseases Research Center, Qazvin University of Medical Sciences, Qazvin, I.R.Iran.

Article Type

Research Paper

Received:
Feb 18th 2022
Revised:
Apr 4th 2022
Accepted:
May 21st 2022

ABSTRACT

Background and Objective: Central retinal vein occlusion (CRVO) is a common age-related vascular retinal disorder and is a condition in which the main vein of the retina is blocked partially or completely. This leads to macular edema (ME) and can cause blurred vision and loss of visual function. The aim of this study is evaluating the prognostic factors of visual acuity (VA) and macular thickness (MT) changes in response to intravitreal bevacizumab therapy.

Methods: In this historical cohort study, 107 patients with CRVO were examined and their hypertension, hyperlipidemia and diabetes mellitus status were recorded. All of the patients were treated with an intravitreal injection of 1.25 mg/0.05 ml bevacizumab. Visual acuity and macular thickness were examined at baseline and at all follow-up visits. Follow-up examinations were performed for three months and then VA and MT changes were analyzed.

Findings: After the intervention with bevacizumab, there was significant improvement in MT (0.104±0.13 versus 0.296±0.22) and VA (425.41±64 versus 325.94±51.82) ($p<0.001$, for both). The improvement of MT in response to bevacizumab therapy in hyperlipidemic patients was significantly less than patients with normal lipid profile ($p=0.035$). No significant relationship was found between MT reduction and hypertension or diabetes mellitus. Also, no significant relationship was observed between VA improvement and hyperlipidemia, hypertension, diabetes mellitus, age and gender.

Conclusion: Bevacizumab therapy was effective to successfully improve VA and MT. Hyperlipidemia has prognostic value in bevacizumab therapy in CRVO patients.

Keywords: *Retinal Vein Occlusion, Bevacizumab, Vascular Endothelial Growth Factor, Visual Acuity.*

Cite this article: Rasoulinejad SA, Maroufi F, Alizadeh A. The Correlation between Predictive Factors and Intravitreal Bevacizumab Therapy Outcomes in Central Retinal Vein Occlusion. *Journal of Babol University of Medical Sciences*. 2022; 24(1): 179-88.

© The Author(S).
Publisher: Babol University of Medical Sciences

[*]Corresponding Author: S. A. Rasoulinejad (MD)
Address: Department of Ophthalmology, School of Medicine, Babol University of Medical Sciences, Babol, IR.Iran.
Tel: +98 (11) 32238301. **E-mail:** rasolisa2@gmail.com

[DOR: 20.1001.1.15614107.1401.24.1.23.9]
[DOI: 10.22088/jbums.24.1.179]

Introduction

Central retinal vein occlusion (CRVO) is a common age-related vascular retinal disorder and is a condition in which the main vein of the retina is blocked partially or completely. This leads to macular edema (ME) and can cause blurred vision and loss of visual function (1). Various factors are involved in CRVO pathogenesis but its specific cause is still unknown. Blocks of central retinal vein due to blood clots or reduced blood flow leads to CRVO development. Many studies approved that a large number of conditions may increase the risk of CRVO such as high levels of blood glucose, high blood pressure, increased levels of lipids profile, coagulation disorders and other predisposing factors for clot formation (2-4).

Increased levels of vascular endothelial growth factor (VEGF) have been observed in vascular retinal disorders like CRVO (5, 6). VEGF have many biologic effects including neovascularization, angiogenesis and it may also induce macular edema by increasing the permeability of retinal vessels and disrupting the blood–retina barrier, which leads to bleeding propensity. Therefore, VEGF inhibition could be a promising treatment for CRVO. According to the results of the clinical trials, periodic intravitreal injections of an anti-VEGF drug into the eye can decrease the newly blood vessel growth and swelling (7, 8).

Anti-VEGF drugs consist of bevacizumab (Avastin), ranibizumab (Lucentis), and aflibercept (Eylea). However, treatment with anti-VEGF drug is temporary and re-injection is often needed. In the last two decades, there is a lot of evidence of intravitreal injection of bevacizumab (Avastin) as a full-length, humanized, anti-VEGF monoclonal antibody that leads to improved visual acuity (VA) and decreases central retinal thickness (CRT) or macular thickness (MT) in CRVO (9, 10). The response to bevacizumab therapy in some patients is weak or not effective, despite multiple intravitreal injections (11).

It is still unclear which factors play a role in determining the rate of response to bevacizumab therapy. As earlier mentioned, diabetes, hypertension and hyperlipidemia are the risk factors for CRVO, and maybe they can be effective on the response to the bevacizumab and in fact, they can be considered as potential predictors of anti-VEGF therapy outcomes (12-14). In this study, we survey the role of some risk factors such as hypertension, hyperlipidemia, and diabetes mellitus in response to intravitreal bevacizumab therapy in CRVO patients.

Methods

After being approved by the Ethics Committee of Babol University of Medical Sciences with code IR.MUBABOL.HRI.REC.1398.145, this historical cohort study was conducted among 107 patients with CRVO who were conferred to the Ophthalmology center of Ayatollah Rouhani Hospital affiliated to Babol University of Medical Sciences from 2014 to 2020. Informed written consent form was collected from each patient and the experimental application of bevacizumab was explained in detail to each patient and all of them agreed with it. Patients were only included if they had no other ocular disease and were not previously treated for retinal vein occlusions. Inclusion criteria were sudden vision loss, vascular tortuosity and dilatation in four quadrants of retina found by fundoscopy. Exclusion criteria included the presence of diabetic retinopathy, age-related macular degeneration and retinal detachment.

Before injection, all patients underwent some ophthalmological examination, including VA and optic coherence tomography (OCT). Macular evaluation was performed using Stratus OCT (Carl Zeiss Meditec Inc., Dublin, CA, USA) and MT was measured using Retinal Map analysis protocol. The same situation was selected for MT measurement before and after intervention based on the characteristic morphology of the retinal vessels. Also, an accurate history of the underlying diseases and medications was obtained from

[DOR: 20.1001.1.15614107.1401.24.1.23.9]
[DOI: 10.22088/jbums.24.1.179]

each patient including blood pressure, blood glucose and lipid profile to determine hypertension (blood pressure>140/90 mm Hg), hyperlipidemia (cholestrol≥200 mg/dL, triglyceride>150 mg/dL) and diabetes (fasting plasma glucose >126 mg/dL) in CRVO patients.

Then, patients were treated with an intravitreal injection of 1.25 mg/0.05 ml bevacizumab (Avastin®, Roche, Germany) in the distance of 3-4-millimeter of limbus (3 mm in aphakia and pseudophakia patients, and 4 mm in phakic patients) under sterile conditions. To prevent unwanted infections, antibiotics were prescribed for a week, starting three days before the injection. Follow-up examinations was performed for three months.

Statistical analysis was performed with SPSS 21.0 software. VA was converted to logMAR to analysis and MT was evaluated in micrometers (μm) for all patients. Quantitative variables are described with Mean±SD and qualitative variables as percentages. T-test was performed to evaluate changes in VA and MT with 95% CI. Multivariate analysis of covariance (MANCOVA) was employed to compare the variables in the presence of risk factors and Wilks' Lambda was used for multivariate analysis. Correlation between VA and MT before and after bevacizumab intervention was calculated using Pearson correlation. The level of significance was set at $p<0.05$ for all statistical tests.

Results

A total of 107 eyes in 107 patients were reviewed (n=107). The age of patients ranged from 32 to 84 years and the average age of the patients was 57.37±10.698 years. 54 (50.5%) of them were female and 53 (49.5%) were male. In this study, 90 (84.1%) of patients had hypertension, 58 (54.2%) of them had hyperlipidemia and 41 (38.3%) had diabetes mellitus (Table 1).

Table 1. Patients characteristics and the changes of MT and VA before and after intervention

Parameters Number(%) or Mean±SD	Patients (n=107)	p-value
Gender		
Female	54(50.5)	
Male	53(49.5)	
Age (year)	57.37±10.69	
Risk factors		
Hypertension	90(84.1)	
Hyperlipidemia	58(54.2)	
Diabetes mellitus	41(38.3)	
Macular Thickness (μm)		
Before injection	425.41±64	<0.001*
After injection	325.94±51.82	
Visual Acuity (LogMAR)		
Before injection	0.104±0.13	<0.001*
After injection	0.296±0.22	

*Macular thickness and visual acuity were significantly improved compared with before injection.

[DOR: 20.1001.1.15614107.1401.24.1.23.9]
[DOI: 10.22088/jbums.24.1.179]

Moreover, there was significant difference in MT and VA before and after the intervention with bevacizumab ($p<0.001$, for both). The mean MT of patients before intervention was 425.41±64 μm and after intravitreal injection significantly decreased into 325.94±51.82 μm. Also, the mean VA of patients increased after intravitreal injection of bevacizumab ($p<0.001$), indicating that bevacizumab therapy was effective to successfully improve the VA and MT. Univariate analysis in hyperlipidemic patients injected with bevacizumab showed that the response to treatment (MT reduction) was significantly less than other risk factors ($p=0.035$) (Table 2).

Table 2. The relationship between variables (MT or VA) and risk factors in response to bevacizumab therapy

Source	Multivariate Analysis		Univariate Analysis			
	Wilks' Lambda	p-value	Macular Thickness		Visual acuity	
			Partial Eta Squared	p-value	Partial Eta Squared	p-value
Gender	0.986	0.496	0.012	0.282	0.006	0.448
Hypertension	0.991	0.633	0.008	0.376	0.003	0.56
Hyperlipidemia	0.921	0.017	0.044	0.035	0.019	0.169
Diabetes mellitus	0.988	0.555	0	0.932	0.012	0.284
Age	0.982	0.405	0.003	0.561	0.018	0.186

In the other words, MT after intravitreal injection of bevacizumab of hyperlipidemic patients was significantly higher than patients without hyperlipidemia ($p=0.015$) (Figure 1-A) and the MT changes (ΔMT) before and after treatment in hyperlipidemic patients was less than patients without hyperlipidemia. Also, the multivariate analysis found a significant association between variables of VA and MT and hyperlipidemia ($p=0.017$).

The average relative percentage change ($\bar{y}$) of MT improvement in hyperlipidemic patients was -21.42%, meaning that MT on average decreased by 21.42% in patients with hyperlipidemia, but the average relative percentage change of MT reduction in patients without hyperlipidemia was -24.24%. Therefore, due to the obvious difference between the average relative percentage changes, the improvement of MT in response to bevacizumab therapy in hyperlipidemic patients was less than patients with normal lipid profile (Figure 2-A).

Considering the response to intravitreal injection of bevacizumab, no significant relationship was found between MT reduction and hypertension ($p=0.376$) or diabetes mellitus ($p=0.932$) (Table 2). Also, there was no significant difference in MT reduction rate after treatment with bevacizumab in positive and negative patients in terms of hypertension ($p=0.750$) and diabetes ($p=0.181$) (Figure 1-B and 1-C). Relative percentage change of reduction rate of MT analysis showed no obvious difference in average relative percentage change ($\bar{y}$) between negative and positive cases in terms of hypertension ($\bar{y}$ in negative cases= -21.56%, $\bar{y}$ in positive cases= -22.38%) (Figure 2-B), and diabetes mellitus ($\bar{y}$ in negative cases= -22.91%, $\bar{y}$ in positive cases= -21.55%) (Figure 2-C). In addition, there was no significant relation between age ($p=0.282$) or gender ($p=0.561$) and MT changes. Finally, the results revealed that there was no significant influence of hypertension and diabetes as risk factors on MT improvement in response to bevacizumab injection. Only hyperlipidemia played a significant role in reducing MT and outcome of treatment.

[DOR: 20.1001.1.15614107.1401.24.1.23.9]
[DOI: 10.22088/jbums.24.1.179]

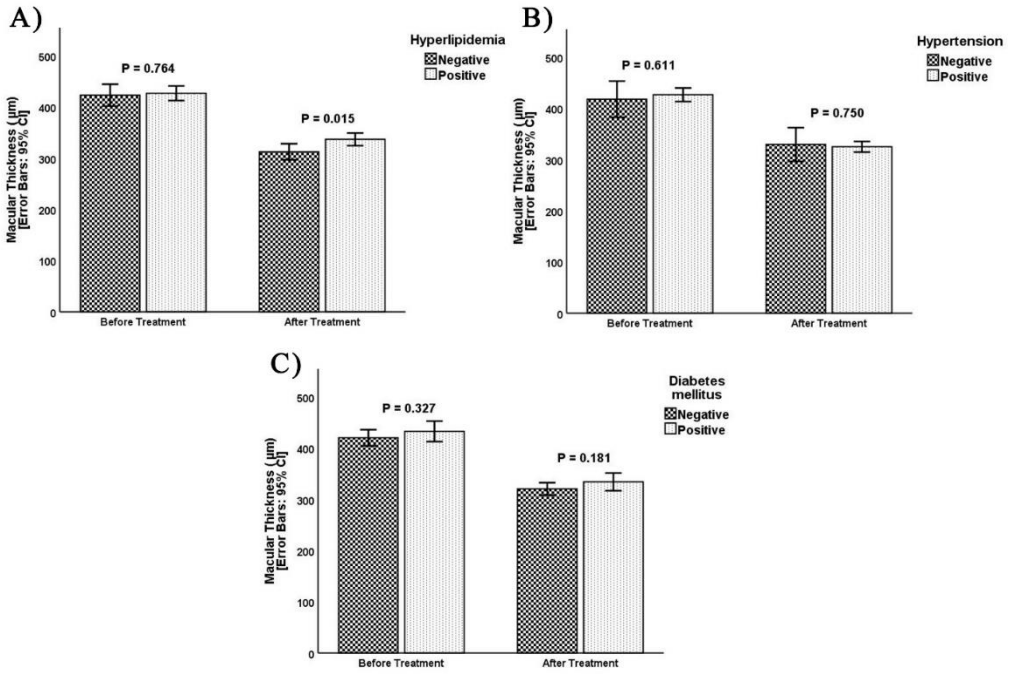

Figure 1. Comparison of macular thickness changes in the presence or absence of risk factors. **A) Hyperlipidemia; MT after intravitreal injection of bevacizumab of hyperlipidemic patients was significantly more than the patients without hyperlipidemia (p=0.015). B) Hypertension; there was no significant difference in MT after intravitreal injection of bevacizumab between the patients with hypertension and patients with normal blood pressure (p=0.750).C) Diabetes mellitus; there was no significant difference in MT after intravitreal injection of bevacizumab between diabetic and non-diabetic patients (p=0.181).**

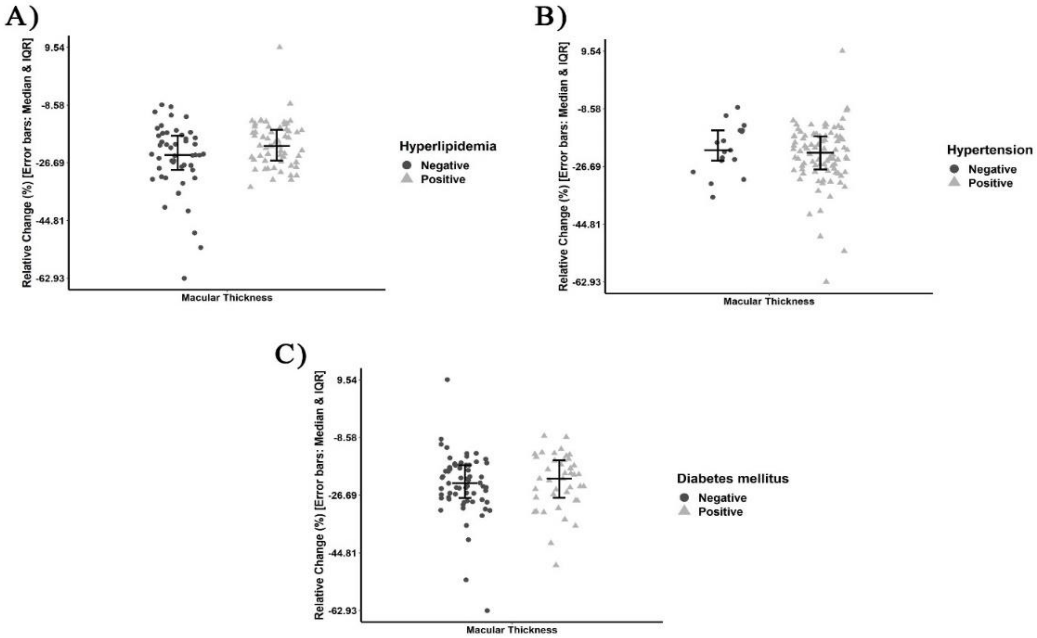

Figure 2. Comparison of the relative percentage changes of macular thickness in the presence or absence of risk factors. **A) Hyperlipidemia; Mean and range of relative percent change of macular thickness in hyperlipidemic patients was less than non-lipidemic patients. B) Hypertension; there was no obvious difference in average relative percentage change between negative and positive cases of hypertension. C) Diabetes mellitus; there was no obvious difference in average relative percentage change between negative and positive patients with diabetes mellitus.**

[DOR: 20.1001.1.15614107.1401.24.1.23.9]
[DOI: 10.22088/jbums.24.1.179]

According to results of analysis, no significant relationship was observed between VA improvement and risk factors including hyperlipidemia (p=0.169), hypertension (p=0.56) and diabetes mellitus (p=0.284). Also, age (p=0.186) and gender (p=0.448) had no effect on VA improvement. Also, there was no significant difference between VA changes after injection of bevacizumab in positive and negative patients in terms of hyperlipidemia (p=0.299) hypertension (p=0.447) and diabetes (p=0.327) (Figure 3-A, 3-B and 3-C). Comparison of relative percentage change in VA changes demonstrated no considerable differences in ȳ between negative and positive cases of hyperlipidemia (ȳ in negative cases= 200, ȳ in positive cases= 300) (Figure 4-A), hypertension (ȳ in negative cases= 166.6667, ȳ in positive cases= 200.00) (Figure 4-B), and diabetes mellitus (ȳ in negative cases= 200, ȳ in positive cases= 250) (Figure 4-C). Therefore, results showed that there was no significant influence of risk factors including hyperlipidemia, hypertension and diabetes mellitus on VA improvement in response to bevacizumab therapy.

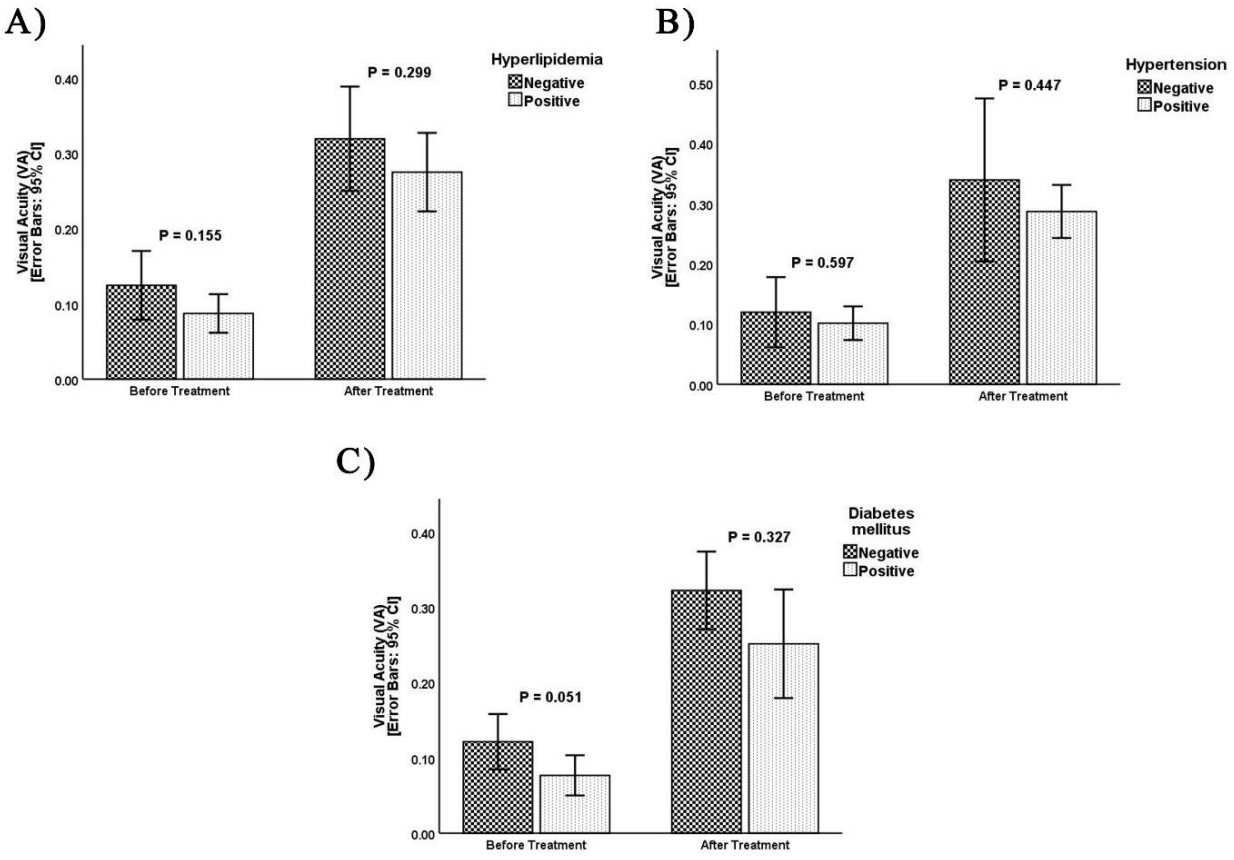

Figure 3. Comparison of visual acuity changes in the presence or absence of risk factors. A) Hyperlipidemia; there was no significant difference in VA changes after injection of bevacizumab between hyperlipidemic patients and non-lipidemic patients (p=0.299). B) Hypertension; no significant relevance in VA changes after injection of bevacizumab was observed in patients with hypertension and patient with normal blood pressure (p=0.447). C) Diabetes mellitus; no significant difference in VA changes in response to bevacizumab therapy was found in diabetic patients and patient without diabetes (p=0.327).

[DOR: 20.1001.1.15614107.1401.24.1.23.9]
[DOI: 10.22088/jbums.24.1.179]

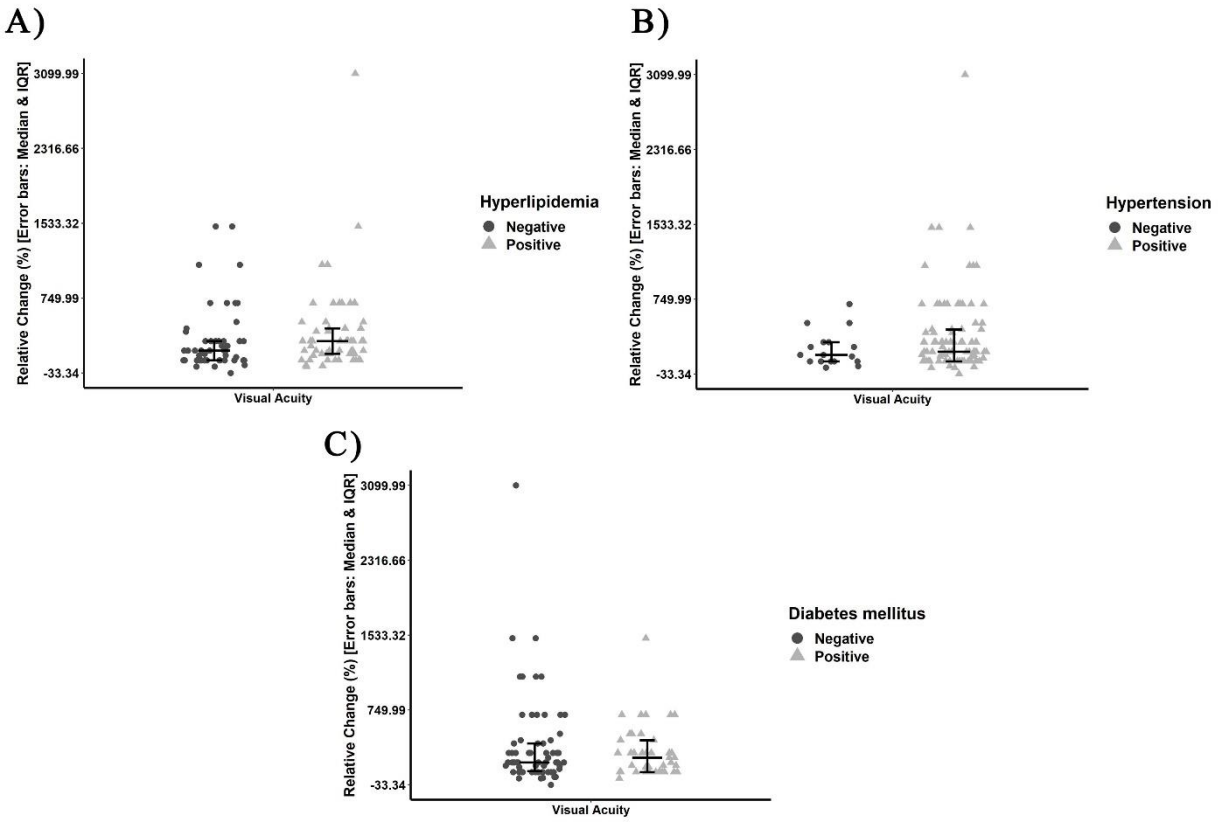

Figure 4. comparison of the relative percentage changes of visual acuity in the presence or absence of risk factors. **A) Hyperlipidemia; Mean and range of relative percent change of VA after intravitreal injection of bevacizumab in hyperlipidemic patients showed no considerable difference between hyperlipidemic and non-lipidemic patients. B) Hypertension; there was no obvious difference in average relative percentage change in VA changes between negative and positive cases of hypertension. C) Diabetes mellitus; there was no obvious difference in average relative percentage change in VA between diabetic patients and patients without diabetes.**

Discussion

In recent two decades, intravitreal injection of bevacizumab has become common in the treatment of CRVO. Various studies proved that anti-VEGF therapy can improve the vascular retinal diseases like CRVO (15-18). However, the response rate is not the same in all patients, some of them are responding weaker or show no response (19-22). Our analysis demonstrated that bevacizumab can improve vision by reducing the MT and increasing the VA ($p<0.05$, for both). Some situations and risk factors can effect CRVO pathogenesis (23-26) and response rate to bevacizumab therapy; so we can predict the treatment outcome by presence of these risk factors which are known as predictive factors. Our findings showed that the response to treatment (MT reduction) was significantly lower in hyperlipidemic CRVO patients compared to healthy CRVO patients ($p=0.035$). Thus, hyperlipidemia reduces the response to treatment and can be a predictive factor for response to bevacizumab therapy in CRVO patients. Some similar studies have been conducted to evaluate prognostic factors of response to intravitreal bevacizumab therapy of CRVO and many of them introduced age (27, 28) and central retinal thickness (CRT) or VA as prognostic predictors in bevacizumab therapy in CRVO patients (29). Ach et al. found that younger patients with lower CRT at

[DOR: 20.1001.1.15614107.1401.24.1.23.9]
[DOI: 10.22088/jbums.24.1.179]

baseline show significantly better response to treatment (30). In addition, Daien et al. found that early injections of bevacizumab in young patients leads to a significant improvement in VA (31) but in our study, age and gender had no prognostic value for treatment outcome and we considered MT and VA changes as a major criterion for evaluating the response rate to the bevacizumab therapy.

Chen et al. showed a significant association between primary open-angle glaucoma, retinal vasculitis, pseudotumor cerebri hypercoagulable state, history of deep vein thrombosis/pulmonary embolism and hyperlipidemia, and CRVO. They found that hyperlipidemia is a risk factor to develop CRVO (OR 3.60, p=0.003) (14). Our findings showed no significant correlation between diabetes mellitus and CRVO. Despite our finding, in a meta-analysis, Wang et al. introduced diabetes mellitus as a risk factor for CRVO (4).

Of course, our study had some shortcomings, including its retrospective nature, lack of a control group, small sample size, and short follow-up but despite these limitations, our results are promising and increased our understanding about the effective factors in response to bevacizumab therapy in CRVO patients. According to our results, reducing hyperlipidemia can increase the response to bevacizumab therapy. Future studies can identify other risk factors in response to anti-VEGF therapy such as underlying diseases like hypothyroidism, renal failure, liver diseases, obesity, coagulation diseases and heart failure or medications like hormonal drugs, corticoids, thiazides, aspirin, anti-allergic drugs and so on.

Acknowledgment

We hereby express our gratitude to the Research and Technology Department of Babol University of Medical Sciences for supporting the research.

[DOR: 20.1001.1.15614107.1401.24.1.23.9]
[DOI: 10.22088/jbums.24.1.179]

References

1.Haymore JG, Mejico LJ. Retinal vascular occlusion syndromes. Int Ophthalmol Clin. 2009;49(3):63-79.

2.Rasoulinejad SA, Zarghami A, Hosseini SR, Rajaee N, Rasoulinejad SE, Mikaniki E. Prevalence of age-related macular degeneration among the elderly. Caspian J Intern Med. 2015;6(3):141-7.

3.Rasoulinejad SA, Iri HO. Determination of serum lipid profile in patients with diabetic macular edema that referred to Shahid Beheshti and Ayatollah Rouhani Hospitals, Babol during 2011-2012. Caspian J Intern Med. 2015;6(2):77-81.

4.Wang Y, Wu S, Wen F, Cao Q. Diabetes mellitus as a risk factor for retinal vein occlusion: A meta-analysis. Medicine (Baltimore). 2020;99(9):e19319.

5.Aiello LP, Avery RL, Arrigg PG, Keyt BA, Jampel HD, Shah ST, et al. Vascular endothelial growth factor in ocular fluid of patients with diabetic retinopathy and other retinal disorders. N Engl J Med. 1994;331(22):1480-7.

6.Pe'er J, Shweiki D, Itin A, Hemo I, Gnessin H, Keshet E. Hypoxia-induced expression of vascular endothelial growth factor by retinal cells is a common factor in neovascularizing ocular diseases. Lab Invest. 1995;72(6):638-45.

7.Adamis AP, Shima DT. The role of vascular endothelial growth factor in ocular health and disease. Retina. 2005;25(2):111-8.

8.Spandau U, Wickenhäuser A, Rensch F, Jonas J. Intravitreal bevacizumab for branch retinal vein occlusion. Acta Ophthalmol Scand. 2007;85(1):118-9.

9.Rosenfeld PJ, Fung AE, Puliafito CA. Optical coherence tomography findings after an intravitreal injection of bevacizumab (avastin) for macular edema from central retinal vein occlusion. Ophthalmic Surg Lasers Imaging. 2005;36(4):336-9.

10.Pai SA, Shetty R, Vijayan PB, Venkatasubramaniam G, Yadav NK, Shetty BK, et al. Clinical, anatomic, and electrophysiologic evaluation following intravitreal bevacizumab for macular edema in retinal vein occlusion. Am J Ophthalmol. 2007;143(4):601-6.

11.Zhang H, Xia Y. [Analysis of visual prognosis and correlative factors in retinal vein occlusion]. Zhonghua Yan Ke Za Zhi. 2002;38(2):98-102.

12.Glacet-Bernard A, Coscas G, Chabanel A, Zourdani A, Lelong F, Samama MM. Prognostic factors for retinal vein occlusion: prospective study of 175 cases. Ophthalmology. 1996;103(4):551-60.

13.Januschowski K, Feltgen N, Pielen A, Spitzer B, Rehak M, Spital G, et al. Predictive factors for functional improvement following intravitreal bevacizumab injections after central retinal vein occlusion. Graefes Arch Clin Exp Ophthalmol. 2017;255(3):457-62.

14.Chen TY, Uppuluri A, Zarbin MA, Bhagat N. Risk factors for central retinal vein occlusion in young adults. Eur J Ophthalmol. 2021;31(5):2546-55.

15.Hsu J, Kaiser RS, Sivalingam A, Abraham P, Fineman MS, Samuel MA, et al. Intravitreal bevacizumab (avastin) in central retinal vein occlusion. Retina. 2007;27(8):1013-9.

16.Prager F, Michels S, Kriechbaum K, Georgopoulos M, Funk M, Geitzenauer W, et al. Intravitreal bevacizumab (Avastin) for macular oedema secondary to retinal vein occlusion: 12-month results of a prospective clinical trial. Br J Ophthalmol. 2009;93(4):452-6.

17.Schaal KB, Höh AE, Scheuerle A, Schütt F, Dithmar S. [Bevacizumab for the treatment of macular edema secondary to retinal vein occlusion]. Ophthalmologe. 2007;104(4):285-9.

18.Kashi Z, Mahrooz A, Kianmehr A, Alizadeh A. The role of metformin response in lipid metabolism in patients with recent-onset type 2 diabetes: HbA1c level as a criterion for designating patients as responders or nonresponders to metformin. PLoS One. 2016;11(3):e0151543.

[DOR: 20.1001.1.15614107.1401.24.1.23.9]

[DOI: 10.22088/jbums.24.1.179]

19.Priglinger SG, Wolf AH, Kreutzer TC, Kook D, Hofer A, Strauss RW, et al. Intravitreal bevacizumab injections for treatment of central retinal vein occlusion: six-month results of a prospective trial. Retina. 2007;27(8):1004-12.
20.Rabena MD, Pieramici DJ, Castellarin AA, Nasir MA, Avery RL. Intravitreal bevacizumab (Avastin) in the treatment of macular edema secondary to branch retinal vein occlusion. Retina. 2007;27(4):419-25.
21.Iturralde D, Spaide RF, Meyerle CB, Klancnik JM, Yannuzzi LA, Fisher YL, et al. Intravitreal bevacizumab (Avastin) treatment of macular edema in central retinal vein occlusion: a short-term study. Retina. 2006;26(3):279-84.
22.Kashi Z, Masoumi P, Mahrooz A, Hashemi-Soteh MB, Bahar A, Alizadeh A. The variant organic cation transporter 2 (OCT2)–T201M contribute to changes in insulin resistance in patients with type 2 diabetes treated with metformin. Diabetes Res Clin Pract. 2015;108(1):78-83.
23.Rath EZ, Frank RN, Shin DH, Kim C. Risk factors for retinal vein occlusions. A case-control study. Ophthalmology. 1992;99(4):509-14.
24.Rasoulinejad SA, Hajian-Tilaki K, Mehdipour E. Associated factors of diabetic retinopathy in patients that referred to teaching hospitals in Babol. Caspian J Intern Med. 2015;6(4):224-8.
25.Mahrooz A, Parsanasab H, Hashemi-Soteh MB, Kashi Z, Bahar A, Alizadeh A, et al. The role of clinical response to metformin in patients newly diagnosed with type 2 diabetes: a monotherapy study. Clin Exp Med. 2015;15(2):159-65.
26.Rasoulinejad SA, Montazeri M. Retinopathy of Prematurity in Neonates and its Risk Factors: A Seven Year Study in Northern Iran. Open Ophthalmol J. 2016;10:17-21.
27.Chen JC, Klein ML, Watzke RC, Handelman IL, Robertson JE. Natural course of perfused central retinal vein occlusion. Can J Ophthalmol. 1995;30(1):21-4.
28.Klein R, Moss SE, Meuer SM, Klein BE. The 15-year cumulative incidence of retinal vein occlusion: the Beaver Dam Eye Study. Arch Ophthalmol. 2008;126(4):513-8.
29.Jaissle GB, Szurman P, Feltgen N, Spitzer B, Pielen A, Rehak M, et al. Predictive factors for functional improvement after intravitreal bevacizumab therapy for macular edema due to branch retinal vein occlusion. Graefes Arch Clin Exp Ophthalmol. 2011;249(2):183-92.
30.Ach T, Hoeh AE, Schaal KB, Scheuerle AF, Dithmar S. Predictive factors for changes in macular edema in intravitreal bevacizumab therapy of retinal vein occlusion. Graefes Arch Clin Exp Ophthalmol. 2010;248(2):155-9.
31.Daien V, Navarre S, Fesler P, Vergely L, Villain M, Schneider C. Visual acuity outcome and predictive factors after bevacizumab for central retinal vein occlusion. Eur J Ophthalmol. 2012;22(6):1013-8.

[DOR: 20.1001.1.15614107.1401.24.1.23.9]
[DOI: 10.22088/jbums.24.1.179]