

Radiographic Comparison of the Relation between Mandibular Third Molar Root and Inferior Alveolar Canal in Panoramic Radiography and Cone-Beam Computed Tomography

Z. Mohammadpour (DDS)¹, R. Foroughi (DDS, MS)², F. Abesi (DDS, MS)³, A. Bijani (MD, PhD)⁴,
S. Haghanifar (DDS, MS)^{*2}

1.Student Research Committee, Babol University of Medical Sciences, Babol, I.R.Iran

2.Oral Health Research Center, Institute of Health, Babol University of Medical Sciences, Babol, I.R.Iran

3.Dental Materials Research Center, Institute of Health, Babol University of Medical Sciences, Babol, I.R.Iran

4.Social Determinants of Health Research Center, Health Research Institute, Babol University of Medical Sciences, Babol, I.R.Iran

J Babol Univ Med Sci; 23; 2021; PP: 289-296

Received: Jan 5th 2021, Revised: Mar 1st 2021, Accepted: May 2nd 2021.

ABSTRACT

BACKGROUND AND OBJECTIVE: There is a risk of damage to the inferior alveolar nerve when extracting third molars. A variety of common imaging modalities, such as panoramic radiography (PR) and cone-beam computed tomography (CBCT), are recommended for examination prior to mandibular third molar surgery. The aim of this study was to compare the findings of panoramic radiography and CBCT in evaluating the relation between the root of the mandibular third molar and the inferior alveolar canal.

METHODS: In this cross-sectional study, 75 panoramic and CBCT images were evaluated. Cases in panoramic radiography that were suspected of the relation between the root of the mandibular third molars and the inferior alveolar canal were collected. To determine the type of connection of apex and root canal, the samples were divided into 6 groups: normal, inferior alveolar canal path loss, canal path narrowing, sudden canal path change, radiolucent band over the roots, and root curvature. Cases in the panoramic radiograph that were suspected of root contact with the canal were examined by the CBCT in terms of the position of the canal relative to the tooth (buccal or lingual or middle of the root - upper or lower) and the type of connection (whether the tooth is connected to the canal).

FINDINGS: In panoramic findings, 23 cases (30.7%) were normal, 19 cases (25.3%) showed canal path loss, 9 cases (12%) canal path narrowing, 5 cases (6.7%) sudden canal path change, 3 cases (4%) radiolucent band over the roots and 16 cases (21.3%) showed root curvature. According to CBCT findings, the position of the canal relative to the root apex was lingual in 39 cases (52%) and there was connection between the mandibular canal and the third molar in 39 cases (78.7%). There was no significant relationship between panoramic radiographic and CBCT findings and only in two cases of specific radiolucent band over the roots, there was a complete agreement between panoramic and CBCT findings.

CONCLUSION: Based on the results of this study, if a radiolucent band is observed on the root of the mandibular molars or a sudden change is observed in the canal path, panoramic radiography can be used to detect the relation between the inferior alveolar canal and the root of the third molars.

KEY WORDS: *Computed Tomography, Panoramic Radiography, Inferior Alveolar Canal, Third Molars.*

Please cite this article as follows:

Mohammadpour Z, Foroughi R, Abesi F, Bijani A, Haghanifar S. Radiographic Comparison of the Relation between Mandibular Third Molar Root and Inferior Alveolar Canal in Panoramic Radiography and Cone-Beam Computed Tomography. J Babol Univ Med Sci. 2021; 23: 289-96.

***Corresponding Author: S. Haghanifar (DDS, MS)**

Address: Department of Oral and Maxillofacial Radiology, School of Dentistry, Babol University of Medical Sciences, Babol, I.R.Iran

Tel: +98 11 32291408

E-mail: dr_haghanifar@yahoo.com

Introduction

Extraction of the third molar is a common procedure in maxillofacial surgery. There is the possibility of impaction for any permanent tooth, but the mandibular third molars are the most common impacted teeth (1-4). Extraction of impacted teeth, even for experienced surgeons, can be difficult or relatively simple and uncomplicated (5). One of the problems with mandibular third molars is the possibility of inferior alveolar nerve damage and sensory abnormalities following nerve damage. The prevalence of these injuries is reported to be between 0.6 and 5.3% and the rate of permanent damage is about 1% of all surgeries (6-8).

Imaging is undoubtedly an essential tool for recognizing and managing surgery because it provides valuable information about location, number and morphology of teeth root, especially the connection between these teeth with adjacent structures (9-11). This is necessary not only to facilitate tooth extraction but also to estimate and reduce the risk of inferior alveolar nerve damage (12-14). Once the location of the canal and the position of the impacted wisdom tooth are determined based on the radiograph, the surgeon can perform the surgical procedure more accurately and, if possible, change the surgical procedure to the direction where the least damage to the inferior alveolar nerve occurs (12). Various common imaging tools, such as panoramic radiography and Cone Beam Computed Tomography (CBCT), are recommended for preoperative examination of the mandibular third molars (15-17).

Panoramic imaging is often used as a primary assessment that can provide an overview or help determine the need for other types of imaging. Studies show that there are signs on panoramic radiographs that indicate the possibility of interference and connection of the root of the mandibular third molars with the inferior alveolar canal. These signs include loss of canal path, narrowing of the canal path, sudden change in the canal path, radiolucent band over the roots, and root curvature. However, the presence or absence of these radiographic signs does not always indicate the possibility of damage to the inferior alveolar nerve, showing that panoramic radiography does not have high diagnostic accuracy during mandibular third molar surgery (6).

Although the use of panoramic radiography has found a special place in the treatment of third molar surgery and due to its availability and low cost, radiography is highly preferred in third molar surgery.

Nevertheless, due to failure to show bone thickness and because of having magnification and distortion, this technology has gradually been replaced by other technologies such as CT scan and CBCT, which can be used to view the patient's anatomy in 3D in different directions with minimum distortion (18).

Cone Beam Computed Tomography benefits from a number of applications in dentistry. Its advantages include high image clarity, reduced metal artifacts, a resolution of less than one millimeter, which makes it suitable for examining delicate structures, lower equipment costs, a lower radiation dose (one-fifteenth) and a shorter radiation time of about 10-70 seconds compared to CT imaging (9, 19).

Numerous studies have reported excellent measurement accuracy of CBCT images (17, 20, 21). Although one study found that there was no significant difference in the use of panoramic and CBCT in the assessment of possible inferior alveolar nerve injuries (15), other studies confirmed the superiority of CBCT in showing the anatomy of the area and the position of the canal, indicating a discrepancy between these studies (7, 22, 23). Therefore, the aim of the present study was to examine the findings of panoramic radiography and CBCT in evaluating the connection between the root of the mandibular third molars and the inferior alveolar canal.

Methods

This cross-sectional study was approved by the ethics committee of Babol University of Medical Sciences with the code IR.MUBABOL.HRI.REC.1397.238 and was performed in the form of a census among 70 samples (40 female patients and 30 male patients) and 50 patients who referred to private oral and maxillofacial radiology centers in Sari and Babol, Northern Iran from 2018 until 2020. Samples were selected based on simple random sampling.

Patients with mandibular third molar, no pathological lesion in the mandibular third molar area and having CBCT of the target area (including ramus, mandibular lower border and third molar area) were included in the study and if there was a history of bone diseases and lesions in the mandible, low-quality radiographs, and third molars with immature roots, the subject was excluded. Specifications of the devices used: Panoramic: (Soredex-Helsinki-Finland) Cranex 3D - (Soredex-Helsinki-Finland) Cranex Tome and CBCT: (Newtom-Verona-Italy) Giano - (Acteon-Italy) X mind triumph.

All radiographs were examined by two observers (two oral and maxillofacial radiologists) with a Kappa coefficient of 70.7 ± 0.06 for the connection between the root of the mandibular third molars and the inferior alveolar canal. The two observers recorded their comments separately and finally the comments were collected and reviewed. In cases where two observers disagreed, the case was re-evaluated. A checklist was used to record patient information. Patient's gender, canal position, type of connection, and panoramic radiographic findings were recorded in the checklist. To determine the type of connection of apex of the third molars and the inferior alveolar canal in panoramic radiography, the samples were

divided into 6 groups: normal, inferior alveolar canal path loss, canal path narrowing, sudden canal path change, root curvature, and radiolucent band over the roots in a way that the tooth is grooved by the dental canal or surrounds the canal (Figure 1). In order to examine the samples in CBCT, the findings were divided according to the position of the canal relative to the tooth (buccal or lingual or middle of the root - upper or lower) and the type of connection (whether the tooth is connected to the canal) (Figures 2 to 5). Data were analyzed using SPSS software version 17 by descriptive indices and Chi-square statistical analysis and $p<0.05$ was considered significant.

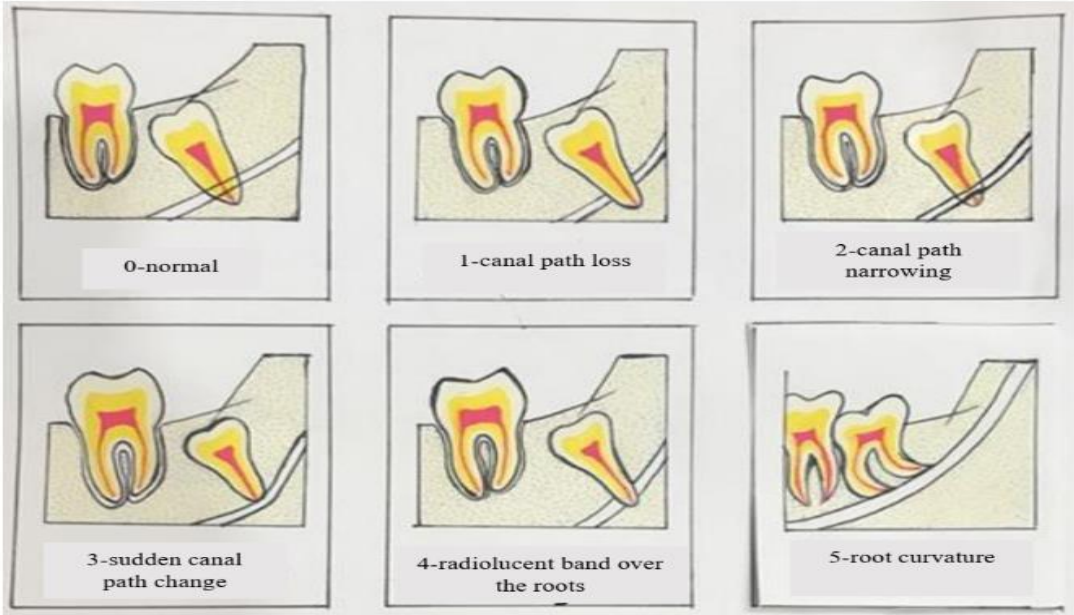


Figure 1. Panoramic radiographic signs

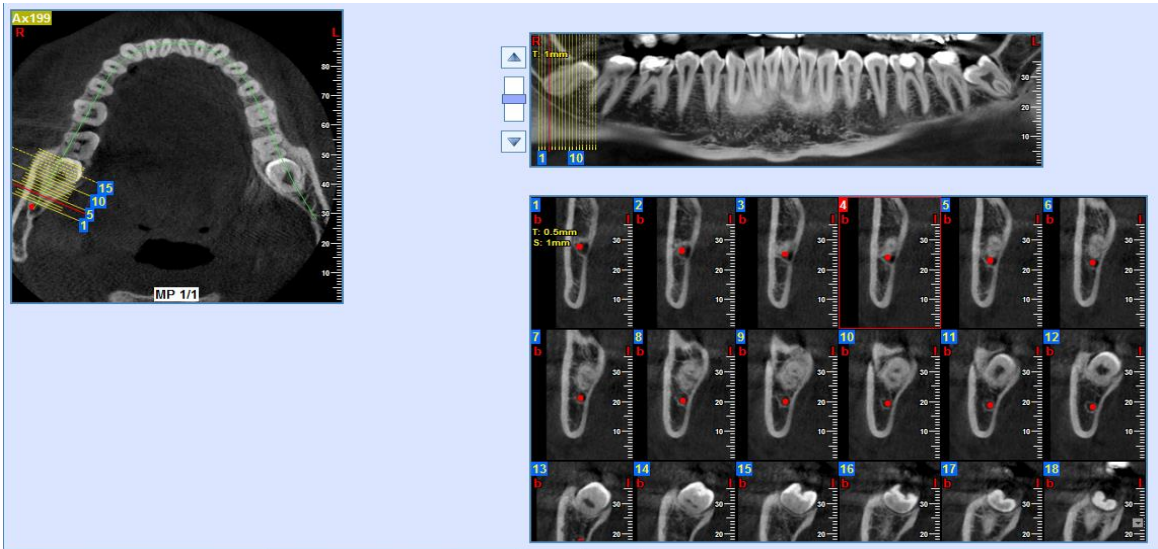


Figure 2. Inferior alveolar canal contact in proximity to the root

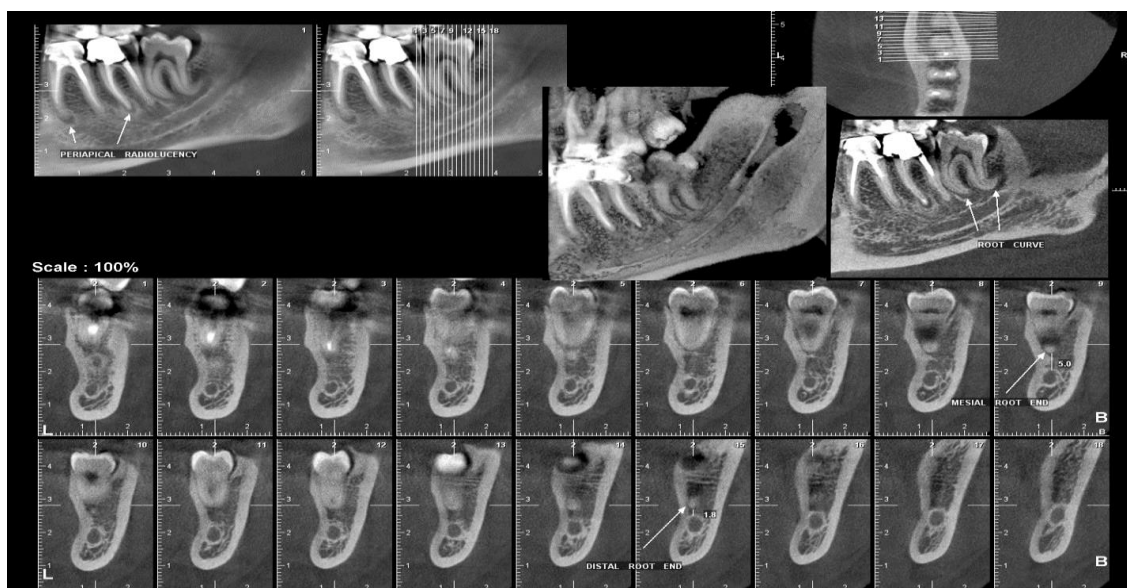


Figure 3. No contact with the inferior alveolar nerve

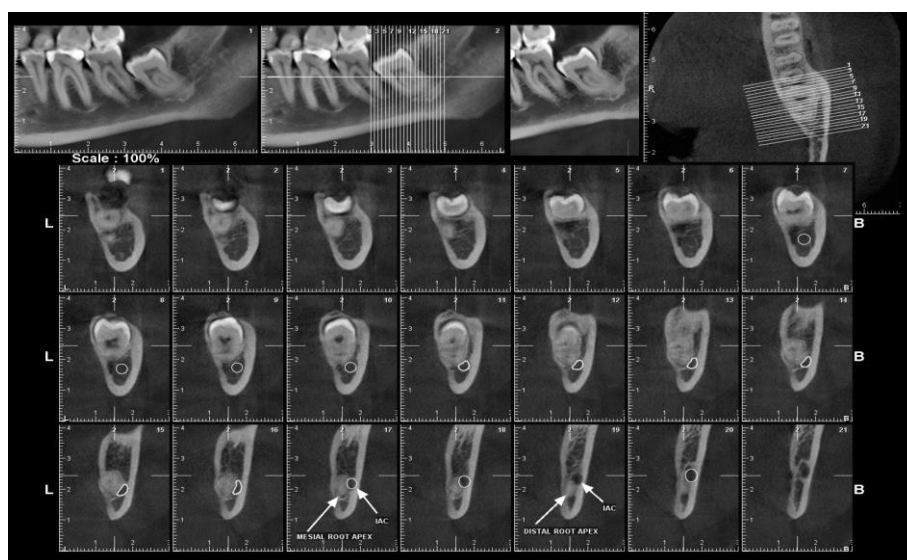


Figure 4. The buccal state of the canal relative to the root

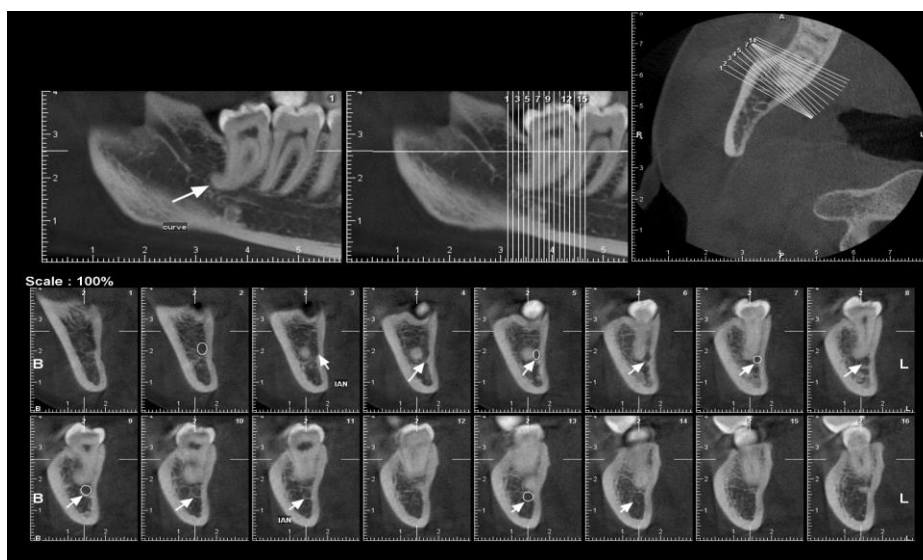


Figure 5. The lingual state of the canal relative to the root

Results

Panoramic radiographic findings: The data were divided into 6 groups, of which 23 cases (30.7%) were normal, 19 cases (25.3%) showed canal path loss, 9 cases (12%) canal path narrowing, 5 cases (6.7%) sudden canal path change, 3 cases (4%) radiolucent band over the roots and 16 cases (21.3%) showed root curvature.

Positioning of the inferior alveolar canal relative to the root apex in CBCT: The canal position was lingual relative to the apex of the root in 39 cases (52%),

buccal in 30 cases (40%), and in the middle of the root in 2 cases (8%). Furthermore, it was in the lower position in 74 cases (98.7%) and it was in the upper position in 1 case (1.3%) and the upper position was seen in the case of canal path loss. Dispersion of contact among 75 cases in CBCT radiography was as follows: 16 cases (21.3%) had no contact with the canal and teeth and 59 cases (78.7%) had contact (Table 1). There was no statistically significant relationship between the findings of panoramic radiography and CBCT (Table 2).

Table 1. Status of tooth apex contact with the inferior alveolar canal

Type of connection in panoramic radiography	CBCT		Total	p-value
	With contact	Without contact		
Normal	16	7	23	-
Inferior alveolar canal path loss	17	2	19	-
Canal path narrowing	8	1	9	-
Sudden canal path change	5	0	5	-
Radiolucent band over the roots	3	0	3	-
Root curvature	10	6	16	-
Total	59	16	75	0.169

Table 2. Status of the inferior alveolar canal relative to the root in CBCT

Type of connection in panoramic radiography	CBCT			Total
	Lingual	Buccal	Middle of root	
Normal	7	14	2	23
Inferior alveolar canal path loss	13	5	1	19
Canal path narrowing	2	5	2	9
Sudden canal path change	3	2	0	5
Radiolucent band over the roots	2	0	1	3
Root curvature	12	4	0	16
Total	39	30	6	75

Discussion

According to the findings of this study, only cases such as observation of specific radiolucent band over the root and sudden change of path of the inferior alveolar canal on the root of the third molar in panoramic radiography have a significant relation with CBCT examinations and in other cases, CBCT is essential for surgery of mandibular third molars. Although the use of panoramic radiography has found a special place in the treatment of third molar surgery and has been used as the primary radiography in third molar surgery, the preference of using CBCT radiography over panoramic radiography in determining the connection between alveolar canal and tooth root is still under debate (18). The present study showed that there is no significant relationship between panoramic radiographic findings and CBCT and accurate evaluation of the mandibular canal with CBCT before invasive surgeries such as wisdom tooth surgery can

help in accurate surgical planning. Ishak et al. concluded that the presence or absence of radiographic signs on panoramic radiographs does not accurately predict the connection between the mandibular third molar root and the mandibular canal, and in cases of overlap of root images with the canal in the patient's panoramic view, CBCT should be evaluated (24), which is consistent with the results of the present study. Moreover, Patel et al., as in the present study, acknowledged the superiority of CBCT over panoramic radiography in examining the connection between the root of the mandibular third molars and the inferior alveolar canal (25). In a systematic review, Del Llano et al. showed that, unlike the present study, panoramic radiography and CBCT have similar ability to assess the reduction of temporary paresthesia of the inferior alveolar nerve after third molar surgery (26). Nasser et al. also reported that panoramic radiographic markers

were statistically consistent with CBCT (27). This difference may be due to the sample size. Jung et al. also reported that there was a significant relationship between panoramic and CBCT findings in an examination of 175 teeth (28). In the present study, in the case of radiolucent band over the roots, there was a complete agreement between the panoramic findings and CBCT, and both are effective in determining the high association between the tooth root and the mandibular canal. The studies of Nunes et al. (29), Pourtaji et al. (10) and Nasser et al. (27) are similar to the present study.

Consistent with the present study, Shujaat et al. (30) and Hosseini Ghoshe et al. (31) acknowledged that the mandibular canal is predominantly in the lingual position relative to the root of the third molar. Furthermore, in the study of Yabroudi et al. (23), canals have been reported in the lingual position relative to the third molar root of the mandible. The result of the present study is not consistent with the study of Yamada et al. (32) in terms of mandibular canal position and in most cases, it has been in the buccal position relative to the apex of the third molar root. The different results obtained in different studies may have been due to differences in how the relationship between the mandibular canal and the mandibular third molar was assessed.

Among the limitations of this study are the small sample size, lack of control over the role of different variables such as radiologist skills in the study due to examining the existing images.

There is a strong correlation between panoramic diagnosis and CBCT in cases of sudden canal path change and radiolucent band over the roots in terms of contact with the canal. However, if other signs are seen on panoramic radiography, CBCT should be performed to determine the relationship between the molars and the inferior alveolar canal. In the study of CBCT, in most cases, the canal was in the lingual position of the root. These findings are very helpful in planning surgery and preventing alveolar nerve damage during surgery, as well as helping to control patient costs.

It is suggested that further studies be performed using a larger sample size and compare the CBCT imaging results in different systems.

Acknowledgment

We would like to thank the Vice Chancellor for Research and Technology of Babol University of Medical Sciences for financial support of the research, as well as Dr. Maryam Johari and Dr. Taraneh Ebrahimifard.

References

1. Eshghpour M, Shaban B, Sarfarzi S, Samieirad S. Oral and Maxillofacial Surgery Department of Mashhad Dental School (2017- Frequency and Difficulty Score of Lower Third Molar Impaction in the Patients Referring to the 2018). J Mash Dent Sch. 2019;42(4):340-7. [In Persian]
2. Arabion H, Gholami M, Dehghan H, Khalife H. Prevalence of impacted teeth among young adults: A retrospective radiographic study. J Dent Mater Tech. 2017;6(3):131-7.
3. Hashemipour M-A, Tahmasbi-Arashlow M, Fahimi-Hanzaei F. Incidence of impacted mandibular and maxillary third molars: a radiographic study in a Southeast Iran population. Med Oral Patol Oral Cir Bucal. 2013;18(1):e140-5.
4. Juodzbalys G, Daugela P. Mandibular third molar impaction: review of literature and a proposal of a classification. J Oral Maxillofac Res. 2013;4(2):e1.
5. Hupp JR, Tucker MR, Ellis E. Contemporary oral and maxillofacial surgery, 6th ed. St. Louis: Elsevier, Mosby; 2014.p.144.
6. Gomes AC, do Egito Vasconcelos BC, de Oliveira Silva ED, de França Caldas Jr A, Neto IC. Sensitivity and specificity of pantomography to predict inferior alveolar nerve damage during extraction of impacted lower third molars. J Oral Maxillofac Surg. 2008;66(2):256-9.
7. Haghanifar S, Moudi E, Yaghoobi S, Bijani A, Ghasemi N. Evaluation of the anatomical relationship between the mandibular canal and roots of the third molars using cone-beam computed tomography (CBCT). J Babol Univ Med Sci. 2016;18(3):7-13. [In Persian]
8. Susarla SM, Dodson TB. Preoperative computed tomography imaging in the management of impacted mandibular third molars. J Oral Maxillofac Surg. 2007;65(1):83-8.
9. White SC, Pharaoh MJ. Oral Radiology: Principles and Interpretation, 7th ed Elsevier, Mosby; 2013.p. 259-68.
10. Purtaji B, Salehifard N, Purtaji M. Comparison of panoramic radiography findings with CBCT findings in evaluation of the relation of impacted mandibular third molar tooth and inferior alveolar canal. J Inflamm Dis. (Previous Title: J Qazvin Univ Med Sci). 2017;21(2):50-6. [In Persian]
11. Haghanifar S, Moudi E, Bijani A, Kazemi Ghanbarabadi M. Morphologic assessment of mandibular anterior teeth root canal using CBCT. Acta Med Acad. 2017;46(2):85-93.
12. Miller CS, Nummikoski PV, Barnett DA, Langlais RP. Cross-sectional tomography. A diagnostic technique for determining the buccolingual relationship of impacted mandibular third molars and the inferior alveolar neurovascular bundle. Oral Surg Oral Med Oral Pathol. 1990;70(6):791-7.
13. Blaeser BF, August MA, Donoff RB, Kaban LB, Dodson TB. Panoramic radiographic risk factors for inferior alveolar nerve injury after third molar extraction. J Oral Maxillofac Surg. 2003;61(4):417-21.
14. Benediktsdottir IS, Hintze H, Petersen JK, Wenzel A. Accuracy of digital and film panoramic radiographs for assessment of position and morphology of mandibular third molars and prevalence of dental anomalies and pathologies. Dentomaxillofac Radiol. 2003;32(2):109-15.
15. Ghaemini H, Meijer GJ, Soehardi A, Borstlap WA, Mulder J, Bergé SJ. Position of the impacted third molar in relation to the mandibular canal. Diagnostic accuracy of cone beam computed tomography compared with panoramic radiography. Int J Oral Maxillofac Surg. 2009;38(9):964-71.
16. Priya PV, Nasyam FA, Ramprasad M, Penumatsa NV, Akifuddin S, Sandeep. Correlating the clinical assessment of impacted mandibular third molars with panoramic radiograph and intraoral periapical radiograph. J Int Soc Prev Community Dent. 2016;6(Suppl 3):S219-25.
17. Huang C-Y, Liao Y-F. Anatomical position of the mandibular canal in relation to the buccal cortical bone in Chinese patients with different dentofacial relationships. J Formos Med Assoc. 2016;115(11):981-90.
18. Lindh C, Petersson A, Klinge B, Nilsson M. Trabecular bone volume and bone mineral density in the mandible. Dentomaxillofac Radiol. 1997;26(2):101-6.
19. Moudi E, Haghanifar S, Madani Z, Bijani A, Nabavi ZS. The effect of metal artifacts on the identification of vertical root fractures using different fields of view in cone-beam computed tomography. Imaging Sci Dent. 2015;45(3):147-51.

20. Barriviera M, Duarte WR, Januário AL, Faber J, Bezerra AC. A new method to assess and measure palatal masticatory mucosa by cone-beam computerized tomography. *J Clin Periodontol.* 2009;36(7):564-8.
21. De Oliveira-Santos C, Souza PH, de Azambuja Berti-Couto S, Stinkens L, Moyaert K, Rubira-Bullen IR, et al. Assessment of variations of the mandibular canal through cone beam computed tomography. *Clin Oral Investig.* 2012;16(2):387-93.
22. Angelopoulos C, Thomas SL, Hechler S, Parissis N, Hlavacek M. Comparison between digital panoramic radiography and cone-beam computed tomography for the identification of the mandibular canal as part of presurgical dental implant assessment. *J Oral Maxillofac Surg.* 2008;66(10):2130-5.
23. Yabroudi F, Sindet-Pedersen S. Cone beam tomography (CBCT) as a diagnostic tool to assess the relationship between the inferior alveolar nerve and roots of mandibular wisdom teeth. *Smile Dent J.* 2012;7(3):12-7.
24. Ishak MH, Zhun OC, Shaari R, Rahman SA, Hasan MN, Alam MK. Panoramic radiography in evaluating the relationship of mandibular canal and impacted third molars in comparison with cone-beam computed tomography. *Mymensingh Med J.* 2014;23(4):781-6.
25. Patel PS, Shah JS, Dudhia BB, Butala PB, Jani YV, Macwan RS. Comparison of panoramic radiograph and cone beam computed tomography finding for impacted mandibular third molar root and inferior alveolar nerve canal relation. *Indian J Dent Res.* 2020;31(1):91-102.
26. Del Llano NC, Ribero RA, Martins CC, Assis NM, Devito KL. Panoramic versus CBCT used to reduce inferior alveolar nerve paresthesia after third molar extractions: a systematic review and meta-analysis. *Dentomaxillofac Radiol.* 2020;49(4):20190265.
27. Nasser A, Altamimi A, Alomar A, AlOtaibi N. Correlation of panoramic radiograph and CBCT findings in assessment of relationship between impacted mandibular third molars and mandibular canal in Saudi population. *Dent Oral Craniofac Res.* 2018;4(4):1-5.
28. Jung Y-H, Nah K-S, Cho B-H. Correlation of panoramic radiographs and cone beam computed tomography in the assessment of a superimposed relationship between the mandibular canal and impacted third molars. *Imaging Sci Dent.* 2012; 42(3): 121-7.
29. Nunes WJ, Vieira AL, de Abreu Guimaraes LD, de Alcantara CE, Verner FS, de Carvalho MF. Reliability of panoramic radiography in predicting proximity of third molars to the mandibular canal: A comparison using cone-beam computed tomography. *Imaging Sci Dent.* 2021;51(1):9-16.
30. Shujaat S, Abouelkheir HM, Al-Khalifa KS, Al-Jandan B, Marei HF. Pre-operative assessment of relationship between inferior dental nerve canal and mandibular impacted third molar in Saudi population. *Saudi Dent J.* 2014;26(3):103-7.
31. Hosseini Ghoosheh SM, Asadi Samani S, Shahidi S, Zamiri B, Asadi Samani S. Anatomical relationship between mandibular third molar roots and mandibular canal in panoramic radiography and CT scans. *Zahedan J Res Med Sci (Tabib-e-Shargh).* 2008;10(3):227-35. [In Persian]
32. Yamada T, Ishihama K, Yasuda K, Hasumi-Nakayama Y, Ito K, Yamaoka M, et al. Inferior alveolar nerve canal and branches detected with dental cone beam computed tomography in lower third molar region. *J Oral Maxillofac Surg.* 2011;69(5):1278-82.