

## The Effect of Receiving L-Glutamine on the Reduction of Renal Tissue Damages and Renal Function Recovery Following Gentamicin-Induced Nephrotoxicity in Rats

R. Naserzadeh (MD)<sup>1</sup>, L. Jafaripour (MSc)<sup>2</sup>, Z. Eslamifar (PhD)<sup>3</sup>, E. Alizamani (MD)<sup>1</sup>,  
N. Nouryazdan (MSc)<sup>4</sup>, H. Ahmadvand (PhD)<sup>\*5</sup>

1.Student Research Committee, Dezful University of Medical sciences, Dezful, I.R.Iran

2.Department of Anatomy, School of Medicine, Dezful University of Medical sciences, Dezful, I.R.Iran

3.Department of Biochemistry, Faculty of Medicine, Dezful University of Medical Sciences, Dezful, I.R.Iran

4.Department of Clinical Biochemistry, Faculty of Medicine, Lorestan University of Medical Sciences, Khorramabad, I.R.Iran

5.Medical Plants and Natural Products Research Center, Hamadan University of Medical Sciences, Hamadan, I.R.Iran

J Babol Univ Med Sci; 23; 2021; PP: 267-274

Received: Dec 11<sup>st</sup> 2020, Revised: Feb 15<sup>th</sup> 2021, Accepted: Feb 24<sup>th</sup> 2021.

### ABSTRACT

**BACKGROUND AND OBJECTIVE:** Gentamicin is one of the aminoglycoside antibiotics that commonly causes nephrotoxicity. Antioxidants are effective in reducing gentamicin-induced nephrotoxicity. In this study, we investigated the possible effect of L-Glutamine on the reduction of renal tissue damages and renal function recovery in gentamicin-induced nephrotoxicity in rats.

**METHODS:** In this experimental study, 32 rats were divided into four groups of eight: Sham group, Gentamicin group (100 mg/kg i.p for 12 days), L-Glutamine group (30 mg/kg by gavage for 12 days), Gentamicin+L-Glutamine group. Then through anesthesia, the blood sample was collected via cardiac and its serum was used to measure the BUN and creatinine levels. The kidney of the rat was used to measure malondialdehyde (MDA), glutathione peroxidase (GPX), catalase (CAT), glutathione (GSH) and determine histopathological parameters.

**FINDINGS:** Receiving gentamicin causes significant elevation in BUN, Creatinine, MDA of the kidney, tubular necrosis, eosinophilic cast, and leukocyte infiltration compared to sham group ( $p<0.05$ ). CAT, GPX, and GSH in gentamicin group caused significant decrease compared to the sham group ( $p<0.05$ ). Glutamine has significantly decreased the MDA level, and leukocyte infiltration compared to gentamicin group ( $p<0.05$ ). Glutamine caused significant increase in GPX (CAT in group 4) compared to gentamicin group ( $p<0.05$ ) and in group 3, BUN, tubular necrosis, eosinophilic caused significant decreases compared to gentamicin group ( $p<0.05$ ).

**CONCLUSION:** Receiving L-Glutamine, 30 mg/kg orally for 12 days has an effective role in the reduction of kidney injuries induced by gentamicin.

**KEY WORDS:** *L-Glutamine, Gentamicin, Nephrotoxicity.*

Please cite this article as follows:

Naserzadeh R, Jafaripour L, Eslamifar Z, Alizamani E, Nouryazdan, Ahmadvand H. The Effect of Receiving L-Glutamine on the Reduction of Renal Tissue Damages and Renal Function Recovery Following Gentamicin-Induced Nephrotoxicity in Rats. J Babol Univ Med Sci. 2021; 23: 267-74.

\*Corresponding Author: H. Ahmadvand (PhD)

Address: Department of Clinical Biochemistry, Faculty of Medicine, Hamadan University of Medical Sciences, Hamadan, I.R.Iran

Tel: +98 81 38381590

E-mail: hassan\_a46@yahoo.com

## Introduction

**G**entamicin, an aminoglycoside antibiotic, has widely been used in the treatment of gram-negative infections. The renal injuries are its most common side effects and approximately 10-20% of patients receiving this drug develop this condition (1, 2). There are other antibiotics known to be used against gram-negative bacteria, causing less nephrotoxicity compared to gentamicin; however, gentamicin is still used against resistant microorganisms against positive beta-lactam due to its low cost and positive effects (1, 2).

Pathological injuries induced by gentamicin include necrosis of kidney tissue and apoptosis caused by oxidative stress, increase of endothelin level, monocyte and macrophage infiltration levels. In addition, gentamicin causes an increase in reactive oxygen species (ROS) such as hydrogen peroxide, superoxide anions, hydroxyl radicals, and reactive nitrogen species in kidney tissue (3). ROS cause irreparable damages in cells and tissues of the body. There is a dynamic balance between ROS and endogenous enzymes such as superoxide dismutase (SOD), catalase (CAT), and glutathione peroxidase (GPX), in a way that these enzymes cause detoxification of ROS and protection of the body against their destructive effects (4).

Most of the studies have shown that different antioxidant factors can halt or decrease the harmful effects of gentamicin in rats. The use of antioxidants in rats being injected with gentamicin can decrease kidney tissue injuries such as tubular necrosis, tubular cell edema, and apoptosis (3, 5, 6). Glutamine, as a precursor for glutathione, leads to antioxidant defense in the body and seems essential for some of the key routes of stressful reactions (7-9). Although glutamine has traditionally been considered as an unessential amino acid, during the rapid growth of the body, stress, or acute disease, it becomes necessary and its use will increase in the body. Thus, it can be defined as a conditionally essential amino acid (10).

L-glutamine has been reported to be effective in reducing gentamicin-induced liver damage, reducing cerebral infarction after cerebral ischemia, and treating sickle cell anemia (11-13). Clinical studies on L-glutamine in the treatment of sickle cell anemia indicate that L-glutamine is tolerable for a short period of time and because these patients are prone to liver, kidney, etc. failures, the use of L-glutamine by these people should be done with caution (13). In many cases, the use of gentamicin is necessary for patients for a long time and on the other hand, kidney damage caused by the use

of this drug is inevitable, so prevention of kidney damage with natural and antioxidant compounds seems necessary. Thus, the purpose of this study is to investigate the possible effect of L-Glutamine on the reduction of renal tissue damages of gentamicin-induced nephrotoxicity in rats by examining kidney function tests, antioxidant enzymes and tissue parameters.

## Methods

**Animals and drug treatment:** All animal experiments in this study are approved by the ethics committee of Dezful University of Medical Sciences, Iran (Ethical number: DURS= 119) based on internationally accepted guidelines for the use of animals. In this experimental study, thirty-two Wistar rats weighting between 200-220 g were provided from the animal lab of Dezful University of medical sciences. These animals were kept at a constant room temperature between 22 and 24°C, and a humidity of 50-60 % and 12 hours of the light/dark cycle. They had free access to water and food.

**Experimental groups:** Rats were randomly divided into four groups of eight:

**1. Sham group**

**2. Gentamicin group:** only received gentamicin 100 mg/kg intraperitoneally for 12 days

**3. L-Glutamine group:** received 30 mg/kg L-Glutamine daily by gavage for 12 days

**4. Gentamicin+L-Glutamine:** received gentamicin and L-Glutamine concomitantly for 12 days

24 hours after the final dose, the animals were anesthetized by injection of 60 mg/kg ketamine and 2.5 mg/kg diazepam. The blood samples were taken, then the right kidney was excised for histopathological studies and left kidney was removed for biochemical experiments and was kept at -80 °c until homogenizing.

**Serum analysis:** The blood sample was centrifuged with 3000 rpm for 10 minutes, and its serum was separated. Urea and creatinine levels were measured by Kits of Pars Azmoon (Pars Azmoon, Tehran, Iran) and biotechnical instruments (BT 1000, Italy).

**Renal Biochemical Analysis:** To measure renal biochemical parameters, kidney tissues were removed from the freezer and homogenized with a homogenizer. Then, tenfold Phosphate Buffered Saline (PBS) solution was added. The solution was centrifuged with (5000 rpm) at 4 °c for 15 min. After removing the supernatant, the solution was used to evaluate parameters such as malondialdehyde (MDA), CAT, glutathione (GSH), and GPX. To measure lipid

peroxidation, briefly, a mixture of homogeneous kidney tissue and trichloroacetic acid was centrifuged, then its supernatant was mixed with Thiobarbituric acid (TBA), and after boiling for 30 minutes, its absorption was read at 530 nm by spectrophotometry (14). To measure glutathione, a mixture of phosphate buffer (PH=7.1), glutathione reductase, EDTA, and kidney sample was prepared and then its adsorption was read at 412 nm by ELISA (15). A mixture of kidney sample with hydrogen peroxide and tert-butyl hydroperoxide was used to measure GPX and was read by ELISA at 420 nm (16). CAT was measured based on the previous study by Aebi. Briefly, a mixture of phosphate buffer (PH=7.4), hydrogen peroxide and kidney sample was prepared and then its absorption at 240 nm was read by a spectrophotometer in 30 seconds for 3 minutes (16, 17).

**Histopathological assessments:** The kidney was fixed inside formaldehyde 10% for 24 hours. After tissue processing and embedding in paraffin, it was cut into 5  $\mu$ m sections and then stained with hematoxylin and eosin. From each kidney, 40 fields at  $\times 400$  magnification were evaluated by microscope to analyze leukocyte infiltration, tubular necrosis, and eosinophilic casts (18). The data were collected semi-qualitatively as follows: No damage= 0, Mild (unicellular)= 1; Moderate (damage less than 25%)= 2; Severe (damage between 25-50%)= 3; highly severe (more than 50% damage)= 4.

**Statistical analysis:** The data analysis was performed by SPSS 21.0. Values were assessed for normality using the Shapiro–Wilk normality test. Data were analyzed by ANOVA test. Data were represented as mean $\pm$ standard deviation of means, the level of significance was determined as p-value<0.05. The graph of data was illustrated by Graph Pad Prism 6 software.

## Results

**Effect of L-Glutamine on Renal function:** The BUN levels in the gentamicin group compared to the sham has significantly increased ( $54.63\pm 10.23$  vs.  $57\pm 6.48$ ,  $p=0.036$ ). BUN levels were reduced in the glutamine-receiving groups, but this decrease was statistically significant only in group 3 (in group 3:  $38\pm 7.56$  vs.  $57\pm 6.48$ ,  $p<0.0001$  and in group 4:  $49\pm 6.82$  vs.  $57\pm 6.48$ ,  $p=0.20$ ) (Figure 1-A). Creatinine in the gentamicin group has significantly increased compared to the sham ( $0.7\pm 0.08$  vs.  $0.58\pm 0.07$ ,  $p=0.036$ ). In this study,

treatment with glutamine could decrease creatinine levels in the group receiving gentamicin but this difference was not statistically significant ( $0.61\pm 0.06$  vs.  $0.7\pm 0.08$   $p=0.14$ ) (Figure 1-B).

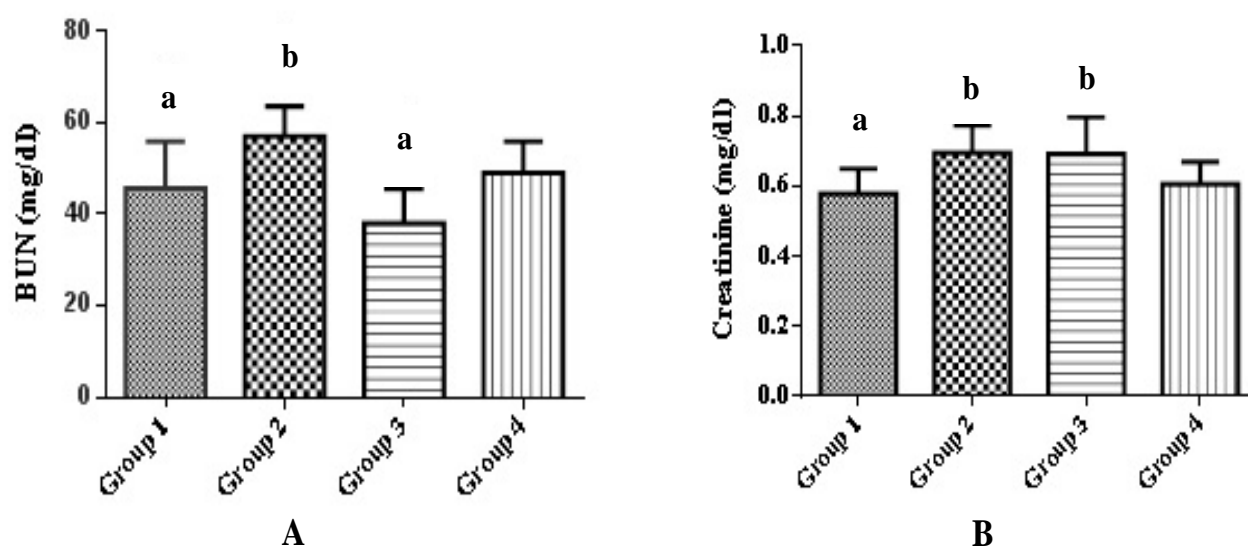
**Effect of L-Glutamine on Renal biochemical parameters:** The MDA level of kidney tissue in the gentamicin group compared to the sham group has increased and this rise was significant ( $62.09\pm 6.73$  vs.  $45.78\pm 9.79$ ,  $p=0.003$ ). Receiving of glutamine in two groups 3 and 4 in comparison with gentamicin (group 2) has decreased the level of MDA and this reduction was significant (in group 3:  $40.26\pm 9.55$  vs.  $62.09\pm 6.73$ ,  $p<0.0001$  and in group 4:  $36.01\pm 6.84$  vs.  $62.09\pm 6.73$ ,  $p<0.0001$ ) (Table 1). Although gentamicin has decreased the glutathione level, this reduction was not significant. The glutathione level has increased in groups receiving glutamine compared to gentamicin group but this elevation was not significant (Table 1). Catalase level in gentamicin group significantly decreased compared to the sham group ( $25.74\pm 10.17$  vs.  $40.91\pm 10.65$ ,  $p=0.042$ ) (Table 1).

Gentamicin has significantly decreased the renal GPX compared to sham group ( $77.66\pm 11.44$  vs.  $123.68\pm 19.55$ ,  $p<0.0001$ ). Glutamine has increased the GPX level in both groups receiving glutamine and this increase was significant compared to gentamicin group (in group 3:  $107.03\pm 12.39$  vs.  $77.66\pm 11.44$ ,  $p=0.005$  and in group 4:  $102.6\pm 18.39$  vs.  $77.66\pm 11.44$ ,  $p=0.019$ ) (Table 1).

**Effect of L-Glutamine on Renal Histopathology parameters:** Gentamicin caused an increase in tubular necrosis in group 2. This increase was significant compared to the sham group ( $2.1\pm 0.24$  vs.  $1.26\pm 0.32$ ,  $p<0.0001$ ). Treatment with glutamine in groups 3 significantly decreased the tubular necrosis compared to gentamicin group ( $1.6\pm 0.28$  vs.  $2.1\pm 0.24$ ,  $p=0.003$ ) (group 3) (Figure 2) (Figure 3).

Eosinophilic casts in the gentamicin group have significantly increased compared to the sham group ( $1.26\pm 0.32$  vs.  $2.1\pm 0.24$ ,  $p<0.0001$ ). Eosinophilic casts in group 3 have significantly decreased compared to the gentamicin group ( $1.6\pm 0.28$  vs.  $2.1\pm 0.24$ ,  $p=0.003$ ) (Figure 2) (Figure 3).

Gentamicin has significantly increased the leukocyte infiltration in kidney tissue compared to the sham group ( $2.16\pm 0.46$  vs.  $1.13\pm 0.28$   $p<0.0001$ ). Glutamine in groups 3 and 4 has decreased the leukocyte infiltration (in group 3:  $1.39\pm 0.25$  vs.  $2.16\pm 0.46$ ,  $p=0.002$ , in group 4:  $1.53\pm 0.47$  vs.  $2.16\pm 0.46$ ,  $p=0.013$ ) (Figure 2) (Figure 3).

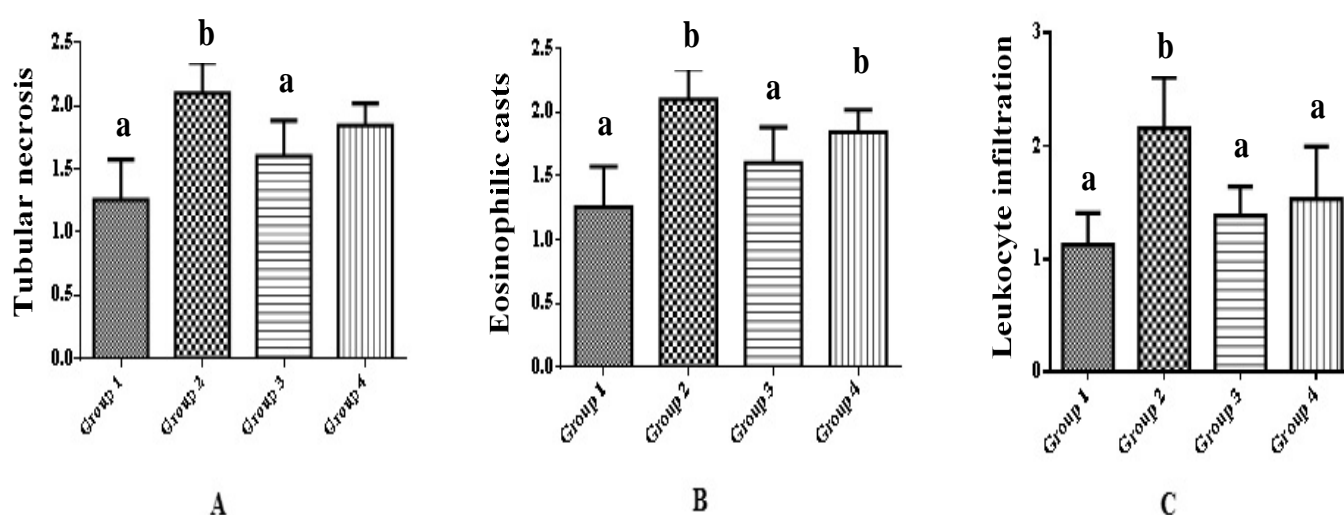


**Figure 1. Effect of L-Glutamine on renal function test in gentamicin induced nephrotoxicity.** Each figure represents the Mean±SD. \*p<0.05 as compared with Group 2 (gentamicin group), #p<0.05 as compared with Group 1 (Sham group).

**Table 1. Effect of L-Glutamine on renal biochemical parameter in gentamicin-induced nephrotoxicity**

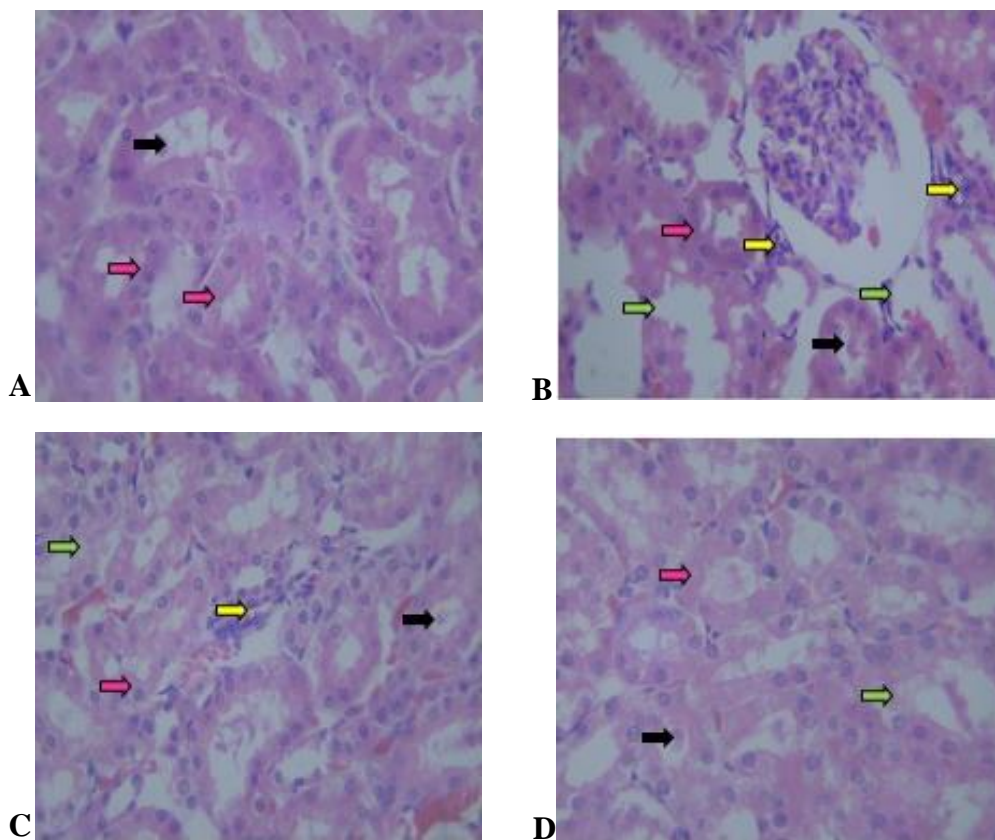
| Group                | MDA             | CAT            | GSH            | GPX            |
|----------------------|-----------------|----------------|----------------|----------------|
|                      | (nm/mg protein) | (U/mg protein) | (U/mg protein) | (U/mg protein) |
|                      | Mean±SD         | Mean±SD        | Mean±SD        | Mean±SD        |
| Sham                 | 45.78±9.79*     | 40.92±10.65*   | 10.40±3.23     | 123.68±19.55*  |
| Gentamicin           | 62.08±6.73#     | 25.74±10.17#   | 9.22±2.90      | 77.66±11.44#   |
| Glutamine            | 40.26±9.55*     | 38.61±10.83    | 11.76±2.63     | 107.03±12.39*  |
| Gentamicin+Glutamine | 36.01±6.84*     | 41.24±12.36*   | 9.35±2.14      | 102.60±18.39*  |

\*p<0.05 as compared with Group 2 (gentamicin group), #p<0.05 as compared with Group 1 (Sham group).



**Figure 2. Effect of L-Glutamine on renal histopathology parameter in gentamicin-induced nephrotoxicity.** Each figure represents the Mean±SD. \*p<0.05 as compared with Group 2 (gentamicin group), #p<0.05 as compared with Group 1 (Sham group).





**Figure 3. Effect of L-Glutamine on histopathological changes of rat kidney in different groups.** A: Sham group, B: Gentamicin group, C: L-Glutamine group, D: Gentamicine+L-Glutamine. Pink arrow shows normal histological structure of renal tubular. Green arrow shows renal epithelial degeneration and tubular necrosis. Black arrow shows epithelial cast of renal. Yellow arrow shows leukocytes infiltration in the interstitial area (H&E,  $\times 400$ ).

## Discussion

In this study, a dose of 100 mg/kg gentamicin increased oxidative stress, kidney damage, and L-glutamine reduced oxidative stress, increased antioxidant activity, and decreased kidney tissue damage. Other studies have shown that gentamicin 40 mg/kg or a higher dose causes acute renal failure (19). The increase in serum BUN and creatinine levels is a sign of renal dysfunction (20, 21). In our study, gentamicin injection has increased the BUN and creatinine levels. Histopathological analysis of group injected with gentamicin showed increase in acute tubular necrosis, leukocyte infiltration, and eosinophilic casts. With regard to biochemical parameters, gentamicin injection has increased the MDA level and has decreased the antioxidant enzymes (GSH, GPX and CAT) of kidney tissue. The use of some compounds such as diclofenac in combination with gentamicin due to reduced blood flow and inhibition of prostaglandins has caused more severe tissue damage in kidney and olive leaf extract, *Lavandula officinalis* and

rosmarinic acid improve kidney tissue due to their antioxidant properties (5, 22-24). In the conducted study, although receiving glutamine has decreased BUN and creatinine levels, this decline was not significant and it has functioned weaker than previous antioxidant inflammatory drugs such as rosmarinic acid, glutathione and garlic juice (5, 25, 26). It may be due to its weaker antioxidant properties than these compounds or the glutamine reduction effect may increase if the dose of the drug increases. Glutamine treatment in rats receiving gentamicin caused a significant decrease in MDA level of kidney tissue due to reduced lipid peroxidation. Some of the previous studies conducted on the use of antioxidants have shown the decline of MDA level kidney and liver tissue (5, 11, 23). Thus, it is possible that the antioxidant activity of glutamine reduces oxidative stress in tissues. Glutamine, due to its antioxidant gene HSP70, has antioxidant properties and also reduces lipid peroxidation (27). In the present study, glutathione, catalase, GPX levels of kidney tissue of rats receiving glutamine along with gentamicin have

significantly increased and this elevation is probably due to the oxidative stress activities of glutamine which resulted in reinforcement of antioxidant system. In the previous studies, some antioxidants such as hydraulic extract of olive leaf, rosmarinic acid have controlled gentamicin-induced nephrotoxicity by increasing the number of antioxidant enzymes of kidney tissues (5, 23).

In some of the studies, it has been mentioned that glutamine increases the antioxidant capacity of tissues, and copes with oxidative stresses by enhancing SOD, glutathione, and GPX activities (11, 27, 28). In our study, it was also shown that glutamine is effective in preventing histopathological changes caused by gentamicin such as reduction of inflammation in the kidney tissue and reduction of inflammation of epithelial tissue tubules. However, the reduction of cellular damage due to its antioxidant and amino acid properties is less than the observations of other studies in this field, which may be related to the dose of this drug and the number of days it is received by rats (5, 29).

However, any increase in the number of days and the dose received should also be carefully considered. Because, very high doses or long-term use may be dangerous. A study found that the rate of glutaminolysis increases in the blood of patients with heart disease and sickle cell anemia, which usually improves with the administration of glutamine and improves these patients. However, appropriate dose, short-term use or the use of a glutaminolysis inhibitor is recommended in these patients (30). The use of glutamine (due to

its antioxidant properties) or glutaminase inhibitor has also been shown to be effective in curing malignancies (31).

Overall, the results of this study showed that L-glutamine has promising effects of antioxidant and anti-oxidative stress in a gentamicin-induced nephrotoxicity model. The findings of this study indicated that 30 mg/kg glutamine by gavage along with gentamicin for 12 days can play an effective role in the decrease of kidney tissue damages and renal function recovery by reducing oxidative stresses due to its anti-inflammatory and antioxidant properties. Based on the results of this study, L-glutamine can be considered as a relatively suitable antioxidant and anti-inflammation in the treatment of renal injuries. It is suggested that effective mechanisms in reducing cellular damage and molecular studies in this field be considered in future research.

**Conflicts of interest:** The authors declared no competing interests.

**Ethical considerations:** Ethical issues (including plagiarism, data fabrication, double publication) have been completely observed by the authors.

## Acknowledgment

We would like to thank Dezful University of Medical Sciences for the financial support and also the staff of Razi Herbal Researches Center of Lorestan University of Medical Sciences, Ms. Forouzan Hadipour and Mr. Reza Rostami and Mr. Ahmad Cheraghi for their assistance in conducting the relevant experiments.

## References

1. Randjelovic P, Veljkovic S, Stojiljkovic N, Sokolovic D, Ilic I. Gentamicin nephrotoxicity in animals: Current knowledge and future perspectives. *EXCLI J*. 2017;16:388-99.
2. Edson RS, Terrell CL. The aminoglycosides. *Mayo Clin Proc*. 1999;74(5):519-28.
3. Safari T, Miri S, Kourkinejad Gharaei F, NazriPanjaki A, Saeidienik F, Bagheri H, et al. Nitric oxide metabolite changes in gentamicin-induced nephrotoxicity; the effects of antioxidant vitamins. *J Renal Inj Prev*. 2018;7(3):201-205.
4. Poulianiti KP, Kaltsatou A, Mitrou GI, Jamurtas AZ, Koutedakis Y, Maridaki M, et al. Systemic redox imbalance in chronic kidney disease: a systematic review. *Oxid Med Cell Longev*. 2016;2016:8598253.
5. Tavafi M, Ahmadvand H. Effect of rosmarinic acid on inhibition of gentamicin induced nephrotoxicity in rats. *Tissue Cell*. 2011;43(6):392-7.
6. Baradaran A, Rafieian-Kopaei M. Histopathological study of the combination of metformin and garlic juice for the attenuation of gentamicin renal toxicity in rats. *J Renal Inj Prev*. 2013;2(1):15-21.
7. Melis GC, ter Wengel N, Boelens PG, van Leeuwen PA. Glutamine: recent developments in research on the clinical significance of glutamine. *Curr Opin Clin Nutr Metab Care*. 2004;7(1):59-70.
8. Novak F, Heyland DK, Avenell A, Drover JW, Su X. Glutamine supplementation in serious illness: a systematic review of the evidence. *Crit Care Med*. 2002;30(9):2022-9.
9. Gündüz E, Ülger BV, İbiloğlu İ, Ekinci A, Dursun R, Zengin Y, et al. Glutamine provides effective protection against deltamethrin-induced acute hepatotoxicity in rats but not against nephrotoxicity. *Med Sci Monit*. 2015;21:1107-14.
10. DeBerardinis RJ, Cheng T. Q's next: the diverse functions of glutamine in metabolism, cell biology and cancer. *Oncogene*. 2010;29:313-24.
11. Jafaripour L, Naserzadeh R, Ahmadvand H, Moradi FH, Ghobadi K, Alizamani E, et al. Effects of L-glutamine on oxidative stress in gentamicin induced hepatotoxicity rats. *J Kerman Univ Med Sci*. 2019;26(1):36-42.
12. Luo L-L, Li Y-F, Shan H-M, Wang L-P, Yuan F, Ma Y-Y, et al. L-glutamine protects mouse brain from ischemic injury via up-regulating heat shock protein 70. *CNS Neurosci Ther*. 2019;25(9):1030-41.
13. Quinn CT. L-Glutamine for sickle cell anemia: more questions than answers. *blood*. 2018;132(7):689-93.
14. Satoh K. Serum lipid peroxide in cerebrovascular disorders determined by a new colorimetric method. *Clin Chim Acta*. 1978;90(1):37-43.
15. Owens CW, Belcher RV. A colorimetric micro-method for the determination of glutathione. *Biochem J*. 1965;94(3):705-11.
16. Dadpisheh S, Ahmadvand H, Jafaripour L, Nouryazdan N, Babaenezhad E, Shati H, et al. Effect of troxerutin on oxidative stress induced by sciatic nerve ischemia-reperfusion injury in rats. *J Kerman Univ Med Sci*. 2020;27(4):338-47.
17. Aebi H. Catalase. In: Bergmeyer H-U, editor. *Methods of enzymatic analysis*, 2<sup>nd</sup> ed. Elsevier; 1974. p. 673-84.
18. Jafaripour L, Naserzadeh R, Alizamani E, Mashhadi SMJ, Rahmani Moghadam E, Nouryazdan N, et al. Effects of rosmarinic acid on methotrexate-induced nephrotoxicity and hepatotoxicity in wistar rats. *Indian J Nephrol*. 2021;31(3):218-24.
19. Abdel-Raheem IT, Abdel-Ghany AA, Mohamed GA. Protective effect of quercetin against gentamicin-induced nephrotoxicity in rats. *Biol Pharm Bull*. 2009;32(1):61-7.
20. Arora MK, Reddy K, Balakumar P. The low dose combination of fenofibrate and rosiglitazone halts the progression of diabetes-induced experimental nephropathy. *Eur J Pharmacol*. 2010;636(1-3):137-44.
21. Tavafi M. Protection of renal tubules against gentamicin induced nephrotoxicity. *J Renal Inj Prev*. 2013;2(1):5-6.
22. Ahmadi M, Hajihashemi S, Rahbari A, Ghanbari F, Ahmadi M. The Effects of Diclofenac on Renal Toxicity Disorders Induced by Gentamicin in Rats. *J Babol Univ Med Sci*. 2018;20(2):33-41. [In Persian]
23. Tavafi M, Ahmadvand H, Toolabi P. Inhibitory effect of olive leaf extract on gentamicin-induced nephrotoxicity in rats. *Iran J Kidney Dis*. 2012;6(1):25-32.

24. Kalantar M, Houshmand Gh, Kalantar H, Asadi M, Goudarzi M. Protective Effect of Hydroalcoholic Extract of *Lavandula Officinalis* L. on Gentamicin Induced Nephrotoxicity in Rats. *J Babol Univ Med Sci*. 2016;18(7):62-7. [In Persian]
25. Ahmadvand H, Babaeenezhad E, Nasri M, Jafaripour L, Mohammadrezaei Khorramabadi R. Glutathione ameliorates liver markers, oxidative stress and inflammatory indices in rats with renal ischemia reperfusion injury. *J Renal Inj Prev*. 2019;8(2):91-7.
26. Nasri H, Rafieian-Kopaei M. Preventive and Curative Effect of Garlic on Nephrotoxic Effect of Gentamicin in Rat. *J Babol Univ Med Sci*. 2014;16(2):42-8. [In Persian]
27. Hu H, Chen L, Dai S, Li J, Bai X. Effect of Glutamine on Antioxidant Capacity and Lipid Peroxidation in the Breast Muscle of Heat-stressed Broilers via Antioxidant Genes and HSP70 Pathway. *Animals (Basel)*. 2020;10(3):404.
28. Li H-T, Feng L, Jiang W-D, Liu Y, Jiang J, Li S-H, et al. Oxidative stress parameters and anti-apoptotic response to hydroxyl radicals in fish erythrocytes: protective effects of glutamine, alanine, citrulline and proline. *Aquat Toxicol*. 2013;126:169-79.
29. Srinivasan KK, Mathew JE, D'Silva KJA, Lobo R, Kumar N. Nephroprotective potential of *Graptophyllum pictum* against renal injury induced by gentamicin. *Iran J Basic Med Sci*. 2015;18(4):412-6.
30. Durante W. The emerging role of l-glutamine in cardiovascular health and disease. *Nutrients*. 2019;11(9):2092.
31. Aboud OA, Habib SL, Trott J, Stewart B, Liang S, Chaudhari AJ, et al. Glutamine addiction in kidney cancer suppresses oxidative stress and can be exploited for real-time imaging. *Cancer Res*. 2017;77(23):6746-58.