

## A Case Report of Rare Kidney and Muscle Hydatid Cyst in an 11-Year-Old Child

S. Rezakhaniha (BSc)<sup>1</sup>, S. Siroosbakht (MD)<sup>\*2</sup>

1. Department of Nutrition, Faculty of Medicine, Science and Research Branch, Islamic Azad University, Tehran, I.R. Iran

2. Department of Pediatrics, Faculty of Medicine, AJA University of Medical Sciences, Tehran, I.R. Iran

J Babol Univ Med Sci; 23; 2021; PP: 109-113

Received: Nov 1<sup>st</sup> 2020, Revised: Nov 30<sup>th</sup> 2020, Accepted: Dec 12<sup>nd</sup> 2020.

### ABSTRACT

**BACKGROUND AND OBJECTIVE:** Hydatid kidney and muscle involvement without liver and lung infection is very rare in children. Hydatid kidney disease can occur as cystic or even solid mass which has a differential diagnosis with a renal cystic tumor. The aim of this rare case report was to investigate the diagnostic and therapeutic pitfall of hydatid renal cyst in endemic areas.

**CASE REPORT:** This is a very rare case in an 11-year-old girl with past history of thigh muscle hydatid cyst 2 years ago who referred with vague abdominal pain. Serologic tests were negative and complex cystic mass with thickened irregular walls with vascularity and relative enhancement in the secretory phase were reported in computerized tomography (CT) scan, without involvement of any organs. Extra-peritoneal nephrectomy was performed with possible diagnosis of renal cystic tumor and final diagnosis was hydatid cyst. Ultrasonography, chest X ray and indirect hemagglutination test were performed and no evidence of recurrence or new infection was observed during one year follow up.

**CONCLUSION:** Considering the introduced case, in patients with complex renal cysts, in addition to considering renal cystic tumors, renal hydatid cysts should be considered in differential diagnosis in endemic areas, even if serological and radiological evaluations are not confirmatory. Furthermore, if surgery is required, it is better to consider extraperitoneal incision.

**KEY WORDS:** *Hydatid Cyst, Kidney, Musculoskeletal, Nephrectomy, Renal Cystic Tumor.*

### Please cite this article as follows:

Rezakhaniha S, Siroosbakht S. A Case Report of Rare Kidney and Muscle Hydatid Cyst in an 11-Year-Old Child. J Babol Univ Med Sci. 2021; 23: 109-13.

**\*Corresponding Author: S. Siroosbakht (MD)**

**Address:** Department of Pediatrics, Faculty of Medicine, AJA University of Medical Sciences, Tehran, I.R. Iran

**Tel:** +98 21 222548008

**E-mail:** soheilasiroosbakht@gmail.com

## Introduction

Hydatid cyst infections remain as a major health concern especially in South and Central America, Middle East, Africa, Russia and China. Any organ is vulnerable to hydatid cyst disease, but the liver and lung are the main sources of involvement (75% and 15%, respectively) and other organs are rarely affected (10%). Primary kidney infection occurs in 2% of cases and musculoskeletal in 1%. Simultaneous infection of two organs has been reported in 5-13% of cases (1). Kidney disease may occur as unilocular, multilocular or even heterogenic solid mass that has a differential diagnosis with a kidney tumor (2).

Renal hydatid cyst usually occurs as asymptomatic, slow and concentric growth over years (3). The most common symptoms are chronic flank or lumbar pain and microscopic hematuria without kidney dysfunction. Hydatiduria, which is the presence of small white grapelike mass in urine, is seen in 10-20% of cases (4). Primary involvement of soft tissues such as kidney and muscle is very rare, especially without liver and lung involvement, and no case has been found in children (5). This is a very rare case of a child with renal mass with no urinary symptoms and a history of muscle hydatid cyst without liver and lung infection. The aim of this rare case report was to investigate the diagnostic and therapeutic pitfall of renal hydatid cyst in endemic areas.

## Case Reports

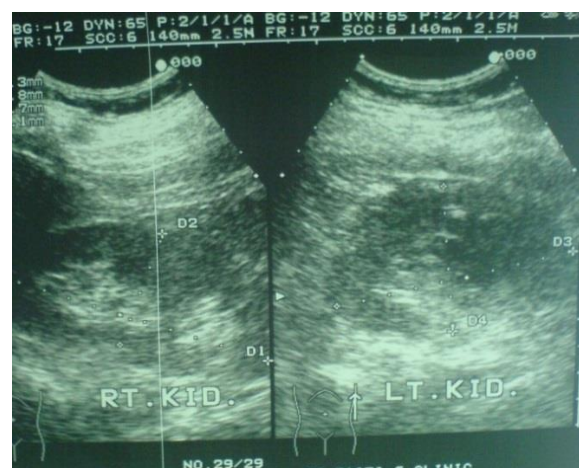This article has been approved by the ethics committee of AJA University of Medical Sciences (IR.AJAUMS.REC.1399.165). An 11-year-old girl with vague abdominal pain and renal mass on ultrasonography and history of groin mass surgery 2 years ago in Isfahan with the final pathology of muscle hydatid cyst was referred to Golestan hospital in Tehran in September 2019. She lives in one of the cities of Isfahan province and had no fever, weight loss and urinary symptoms. She had past history of thigh muscle surgery 2 years ago which the hydatid cyst was final pathologic diagnosis. She did not receive any drugs for the parietal lesion. Diagnostic tests included complete blood count (CBC) (Hb 12.7, WBC 8700, Eosinophil 2.8% and sedimentation rate 27); kidney and liver function tests, calcium, alkaline phosphates, urine analysis and chest X ray were normal. According to the past history of disease, the indirect hemagglutination (IHA) and Casoni test for hydatid infection were requested, but all were negative. Ultrasonography

showed 7×8 cm heterogenic solid mass with clear wall and central necrosis at middle-lower pole of right kidney (Figure 1). Computed tomography (CT) revealed complex cystic mass with thickened irregular walls with vascularity and relative enhancement and attenuated fluid in the secretory phase was reported (Bosniak III) without involvement of any organs (Figure 2).

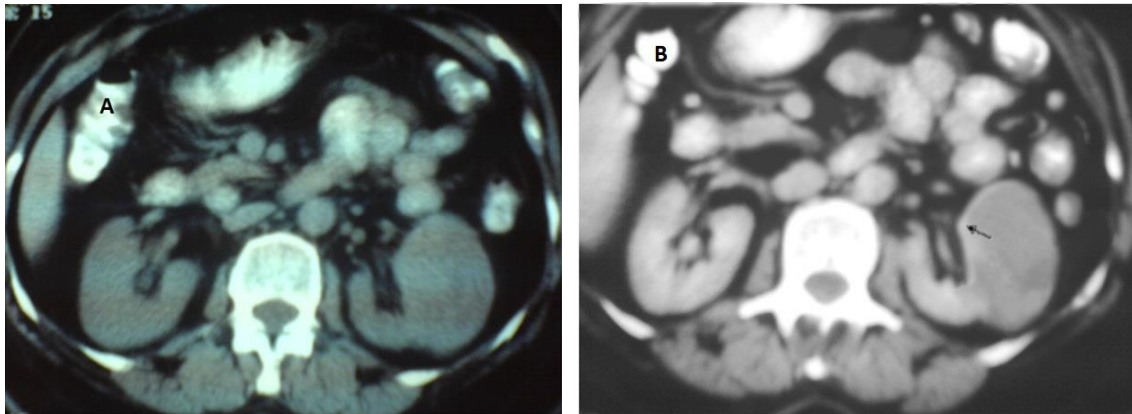
Mass resection or hemi-nephrectomy with possible diagnosis of cystic renal tumor was considered. On the base of history of patient and possible other mass, flank retroperitoneal incision performed instead of intraperitoneal surgery. Hard complex cystic mass with engorged vessels, renal hilum involvement and high peripheral adhesions were revealed at mid-lower portion of kidney. Hemi-nephrectomy or mass resection was not possible and inevitably nephrectomy was performed.

Macroscopic report of kidney measuring 3×9×7 cm with a hard mass measuring 8×7.5 cm was observed in the lower half of the kidney with ectopic vessels. In cutting the kidney, a cyst with a white wall with a thickness of 0.1 cm and the mentioned dimensions was observed. In the microscopic report (hematoxylin-eosin, ×40), a germinal layer wall consisting of smooth and flat cells as well as laminated layer cells and bleeding areas around the cyst were observed (Figure 3).

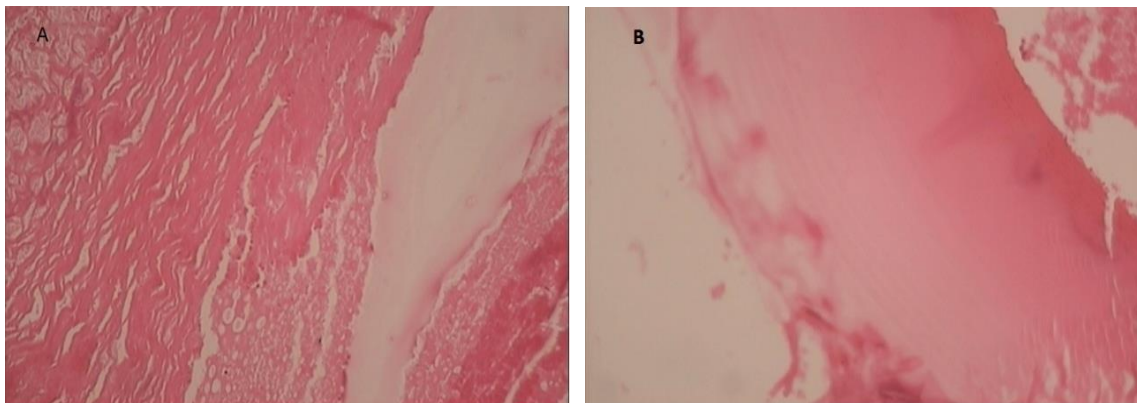
Albendazole 200 mg twice a day was started for 6 months with monthly full blood tests and liver tests. During the follow-up period of the patient, abdominal ultrasound, chest x-ray and laboratory tests of kidney, liver and IHA were performed and during the 1-year follow-up period of the patient, no evidence of recurrence or new infection was observed.



**Figure 1. Ultrasonography showed 7×8 cm heterogenic solid mass with clear wall and central necrosis at middle- lower pole of right kidney.**



**Figure 2. Computed tomography A) without contrast B) with contrast; complex cystic mass with thickened irregular walls, vascularity and relative enhancement (solid arrow) and attenuated fluid in the secretory phase without any organ involvement. Possible diagnosis was cystic renal tumor.**



**Figure 3. Microscopic study showed cyst wall consist of flat germinal cells and laminated layer (A) with peripheral hemorrhagic areas (B).**

## Discussion

A child with muscle hydatid involvement who was not evaluated for other organs and did not receive appropriate drug treatment was introduced. Renal hydatid cyst can be presented as complex cystic lesions and be misdiagnosed as renal cystic tumor. In children, the renal hydatid cystic symptoms are nonspecific (often asymptomatic) and are found incidentally (6). Ultrasound, CT scan, or MRI can help in diagnosis of lesions. A thick-walled unilocular cyst with calcification of cyst wall or a multilocular cystic lesion with brief heterogeneity on CT scan shows a hydatid cyst (7). However, the absence of calcification or daughter cysts within the main cyst does not rule out the diagnosis of hydatid cyst. The most important differential diagnoses include infected cysts, renal abscesses, and cystic kidney tumors (8). In liver lesions, the sensitivity and specificity of indirect hemagglutination test and enzyme-linked immunosorbent assay (ELISA) and *Casoni* test are 80-100% and 88-96%, respectively. However, in lung

lesions it has been reported 50-56% and in other lesions 25-26%. An increase in Eosinophil is seen in less than 50% of cases (9). Fine needle aspiration (FNA) can be helpful in suspected cases and in unusual organ infection, but the risk of anaphylactic shock and the spread of daughter cysts should be considered (10). In this reported patient, serologic tests were negative and no increase in Eosinophil counts was observed. It is important to mention that positive serological tests are valuable, but negative ones do not rule out hydatid disease. In endemic areas, the past history of hydatid disease in another organ in the patient and or the patient's relatives is very important and should be considered in differential diagnosis of the patient. Various methods have been reported for the treatment of kidney hydatid lesions. Kidney preserving surgery is possible in the majority of patients (75%) and nephrectomy is done in patients with complete renal destruction (25%) or commonly in cases with the possible cystic kidney tumor and indefinite diagnosis

hydatid cyst before surgery (11). In a rare case report, kidney cystic mass in a 54-year-old woman with possible kidney cancer underwent radical intraperitoneal nephrectomy. Final diagnosis was hydatid cyst (12). However, because of the possibility of hydatid cyst in the differential diagnosis of our patient, the retroperitoneal instead of intraperitoneal incision was considered to reduce the possibility of the lesion spillage in the abdominal cavity, if a rupture occurred. Kidney hydatid cyst is usually seen with synchronous or asynchronous liver or lung infection (13). But our case had a history of muscle infection 2 years ago, without liver or lung involvement that was not found in similar reports.

In 1950 patients undergoing hydatid cyst surgeries (a mean age of 25-35 years) in 38 medical centers in Iran, kidney and muscle involvements were observed in 2.56% and 1.02%, respectively. Synchronous or asynchronous kidney and muscle hydatid cyst were not reported (14). But the mentioned patient was an 11-year-old child with kidney and muscle involvement, which is very rare.

Hydatid cyst recurrence rate after treatment is about 6.5%. The duration of recurrence after soft tissue hydatid cyst surgery is about 3 months to 20 years (average of 2-10 years). In patients with positive serological tests, increase in antibody titers after excision of the primary lesion may persist for a long time, so it is better to detect new lesions by ultrasound or CT scan (15). Recurrence rate is higher in patients

with soft tissue involvement without liver and lung infection. Therefore, drug treatment is recommended before and after surgery. In endemic areas, it is better to examine other organs of body after discovering a lesion in one organ (16, 17). In the reported patient, drug treatment and evaluation of other organs was not performed after thigh lesion surgery. When a thigh hydatid cyst was discovered, other organs should have been examined for infection. As a result, possible diagnosis of kidney infection could occur in the early stages.

According to the introduced case, in endemic areas in patients with complex renal cysts, in addition to considering renal cystic tumors, renal hydatid cysts should be considered in differential diagnosis, even if serological and radiological evaluations are not confirmatory. Furthermore, if a patient has a history of hydatid cyst in any organ, other organs involvement should be considered. Furthermore, if surgery is required, it is better to perform extraperitoneal incision to prevent the possibility of abdominal cavity spillage.

### Acknowledgment

We would like to thank the Vice Chancellor for Research and Technology of AJA University of Medical Sciences for their support as well as the staff of the Department of Pediatrics and Pathology of Golestan Hospital, Dr. Jadidfard and Dr. Saberinejad who helped us in this research.

## References

1. Erol B, Tetik C, Altun E, Soysal A, Bakir M. Hydatid cyst presenting as a soft-tissue calf mass in a child. *Eur J Pediatr Surg.* 2007;17(1):55-8.
2. Qadri S, Sherwani RK, Ahmed M. Isolated cystic echinococcosis of kidney burlesquing as renal cell carcinoma: a diagnostic pitfall. *Ann Parasitol.* 2015;61(1):57-60.
3. Garg R, Nahar U, Mandal AK. A rare case of primary renal hydatid cyst. *Ann Parasitol.* 2015; 61(2):129-31.
4. Mudholkar VG, Suwarnkar SV, Deshpande SA, Kadam PN. Isolated renal hydatid disease with gross hydatiduria. *Indian J Pathol Microbiol.* 2011;54(3):640-1.
5. Tekin R, Avci A, Tekin RC, Gem M, Cevik R. Hydatid cysts in muscles: clinical manifestations, diagnosis, and management of this atypical presentation. *Rev Soc Bras Med Trop.* 2015;48(5):594-8.
6. Islami Parkoohi P, Jahani M, Hosseinzadeh F, Taghian S, Rostami F, Mousavi A, et al. Epidemiology and Clinical Features of Hydatid Cyst in Northern Iran from 2005 to 2015. *Iran J Parasitol.* 2018;13(2):310-6.
7. Kumar V, Misra V, Chaurasiya D, Verma N. Collecting duct carcinoma kidney masquerading as hydatid cyst: A rare case report and review of literature. *Indian J Pathol Microbiol.* 2018;61(3):410-3.
8. Bhat GS, Burude VA, Hegde SD, Tembadamani VS. Isolated renal hydatid cyst masquerading as cystic renal cell carcinoma: a case report. *J Clin Diagn Res.* 2015;9(3):PD07-8.
9. Gonlugur U, Ozcelik S, Gonlugur TE, Celiksoz A. The role of Casoni's skin test and indirect haemagglutination test in the diagnosis of hydatid disease. *Parasitol Res.* 2005;97(5):395-8.
10. Gupta R, Mathur SR, Agarwala S, Kaushal S, Srivastav A. Primary soft tissue hydatidosis: aspiration cytological diagnosis in two cases. *Diagn Cytopathol.* 2008;36(12):884-6.
11. Gadelkareem RA, Elqady AA, Abd-Elshafy SK, Imam H, Abolella HA. Isolated Renal Hydatid Cyst Misdiagnosed and Operated as a Cystic Renal Tumor. *Med Princ Pract.* 2018;27(3):297-300.
12. Dwivedi AN, Mourya C. Disseminated cystic nodal metastasis in renal cell carcinoma mimicking systemic hydatidosis on imaging. *J Cancer Res Ther.* 2018;14(2):441-3.
13. Morakote N, Thamprasert K, Lojanapiwat B, Muttarak M. Cystic echinococcosis in Thailand with a special note on detection by serology in one family. *Southeast Asian J Trop Med Public Health.* 2007;38(5):796-8.
14. Dalimi A, Motamedi Gh, Hosseini M, Mohammadian B, Malaki H, Ghamari Z, et al. Echinococcosis/hydatidosis in western Iran. *Vet Parasitol.* 2002;105(2):161-71.
15. Velasco-Tirado V, Romero-Alegria Á, Belhassen-García M, Alonso-Sardón M, Esteban-Velasco C, López-Bernús A, et al. Recurrence of cystic echinococcosis in an endemic area: a retrospective study. *BMC Infect Dis.* 2017;17(1):455.
16. Eyüboğlu TŞ, Gürsoy TR, Aslan AT, Pekcan S, Budakoğlu İİ. Ten-year follow-up of children with hydatid cysts. *Türk Pediatri Ars.* 2019;54(3):173-8.
17. Tartar T, Bakal U, Sarac M, Akdeniz I, Kazez A. Primary Urachal Hydatid Cyst in a Child: A Case Report. *Iran J Parasitol.* 2019;14(2):352-5.