

Evaluation of Sperm Quality and Serum Parameters in Sertraline-Exposed Mice and Protective Role of Vitamin E

F. Morshedi (MSc)¹, H. Morovvati (PhD)^{*1}, J. Sadeghinezhad (PhD)², M. Taheri (PhD)³, H. Anbara (MSc)¹

1.Department of Histology, Faculty of Veterinary Medicine, University of Tehran, Tehran, I.R.Iran

2.Department of Anatomy & Embryology, Faculty of Veterinary Medicine, University of Tehran, Tehran, I.R.Iran

3.Central Laboratory, Faculty of Veterinary Medicine, University of Tehran, Tehran, I.R.Iran

J Babol Univ Med Sci; 22; 2020; PP: 1-8

Received: Feb 16th 2019, Revised: Jun 3rd 2019, Accepted: Jun 23rd 2019.

ABSTRACT

BACKGROUND AND OBJECTIVE: Sertraline is one of the antidepressants whose effects on the reproductive system has faced controversial reports. This study was performed to evaluate the efficacy of vitamin E against sertraline-induced injuries on serum and sperm parameters.

METHODS: In this experimental study, 40 adult male mice were divided into eight groups of 5. Four groups of mice received vitamin E at 100 international units per kg body weight via gavage for 42 days. In three of the above groups, sertraline was administered orally at 5, 10 and 20 mg/kg body weight four hours after receiving vitamin E. One group was considered as the control group. Twenty-four hours after the final treatment, blood samples were collected from the heart and sperm quality parameters including count, motility, viability, chromatin density, abnormal forms, and sperm DNA damage were measured.

FINDINGS: Sertraline significantly increased abnormal sperm (25.8 ± 2.04) and significantly decreased the count (30.2 ± 2.77), motility (68.30 ± 2.94), viability (75.4 ± 3.20) and maturation (84.0 ± 1.58) of sperm compared to control group (10.4 ± 1.14 , 39.6 ± 2.07 , 89.37 ± 1.87 , 92.6 ± 3.71 , and 97.4 ± 1.14 , respectively) ($P < 0.05$). Vitamin E administration significantly improved abnormal sperm (17.8 ± 2.28), count (37.2 ± 1.92), motility (78.27 ± 2.10), viability (83.2 ± 2.38) and maturation (83.4 ± 1.81) of sperm ($p < 0.05$).

CONCLUSION: The results of this study showed that vitamin E decreases the reproductive toxicity of sertraline in mice by improving serum and sperm parameters.

KEY WORDS: Vitamin E, Sertraline, Sperm, Testosterone, Mice.

Please cite this article as follows:

Morshedi F, Morovvati H, Sadeghinezhad J, Taheri M, Anbara H. Evaluation of Sperm Quality and Serum Parameters in Sertraline-Exposed Mice and Protective Role of Vitamin E. J Babol Univ Med Sci. 2020; 22: 1-8.

*Corresponding Author: H. Morovvati (PhD)

Address: Department of Histology, Faculty of Veterinary Medicine, University of Tehran, Tehran, I.R.Iran

Tel: +98 21 61117117

E-mail: hmorovvati@ut.ac.ir

Introduction

Depression and taking antidepressants are constantly increasing (1). Selective serotonin reuptake inhibitors (SSRIs) are widely used in reproductive ages, i.e., between 15 and 50 years of age, to inhibit withdrawal of serotonin from the synapse (2). Sertraline is a class of SSRIs that is used to treat depression, mood and anxiety disorders of adults, post-traumatic stress disorder, etc., and like other SSRIs (3-5), it is metabolized primarily in the liver. Side effects of sertraline include impotence, decreased libido, delayed ejaculation, abnormal bleeding (red spots on the skin surface), feeling of breast enlargement or milk secretion in women, itching in the skin, etc. (6-9), and it has adverse effects on the reproductive system (10,11).

SSRIs have undesirable sexual effects such as anorgasmia, erectile dysfunction, and decreased libido (12,13). SSRIs decrease spermatogenesis, decrease sperm motility and count, testicular weight, testosterone levels, fertilization rate and number of live embryos (14). The rate of abnormal forms and sperm DNA damage in SSRIs-treated mice increases in a dose-dependent manner (15,16). Sertraline also damages testicular tissue and increases oxidative parameters in mice (17,18).

Vitamin E as a potent antioxidant prevents the damage caused by free radicals and plays a key role in delaying the pathogenesis of various degenerative diseases such as cardiovascular disease, cancer, inflammatory diseases and neurological disorders and is effective in protecting the immune system (19). The effect of this vitamin on inhibiting the deleterious effects of free radicals in testis and sperm has been reported (20,21).

Vitamin E can strengthen the antioxidant defense system of testicular and sperm cells (21). Since most antidepressants, including selective serotonin reuptake inhibitors, have been able to change the genitalia by increasing free radicals, sertraline may also alter the function of the male reproductive system and perhaps vitamin E can act as a potent antioxidant through the glutathione peroxidase pathway and have a positive effect in reducing the potential damage caused by sertraline. According to these points, and considering the antioxidant properties of vitamin E against oxidative stress, there has been no reports of the effects of vitamin E administration on sperm quality and serum parameters in sertraline-treated mice. The aim of

this study was to investigate the protective effects of vitamin E on sperm quality parameters, testosterone changes, and oxidative parameters such as total antioxidant capacity and malondialdehyde levels in mice treated with sertraline over a 42-day period.

Methods

This experimental study was performed in accordance with guidelines approved by the Ethics Committee of the Faculty of Veterinary Medicine, University of Tehran, based on ethics code 30029/6/11 on 40 adult male NMRI white mice (20-25 grams) obtained from Animal Breeding Center of Pasteur Institute of Iran. Animals were kept in standard mice cages with open access to pellets and tap water for 12 h light and 12 h dark at 23 ± 2 °C.

The mice were randomly divided into 8 groups of 5 and received oral sertraline and vitamin E orally (gavage) for 42 consecutive days: The first group received 0.3 ml of physiological saline as the control group. The second to fourth groups (S5-S20) received sertraline at 5, 10 and 20 mg/kg, respectively (17). The fifth group (E) received 100 international units per kg body weight (IU/kg body weight) vitamin E (21). The sixth to eighth groups received sertraline at 5, 10, and 20 mg along with 100 IU/kg body weight vitamin E.

The mice were anesthetized on the forty-third day with a mixture of ketamine and xylazine. Blood was collected from the heart and serum was isolated and they were sacrificed with CO₂. Serum testosterone levels were measured by ELISA and radioimmunoassay using a special kit (Diaplus Inc. USA). Total antioxidant capacity (TAC) (based on restorative power of trivalent iron) and the Malondialdehyde (MAD) level were measured.

Sperm were also examined after removal of the epididymal segment and placing it in the HTF medium. Ten slides were prepared from each sperm sample for each staining and mean sperm count per unit volume, constant dilution (using Neobar slide), sperm motility percentage, sperm viability (Eosin-Nigrosin staining), DNA fragmentation rate (using acridine orange staining), and nuclear maturation (using Aniline blue staining) were evaluated (22). Data were analyzed using SPSS version 19 and one-way ANOVA followed by Tukey post hoc tests. P value < 0.05 was considered significant.

Results

Sperm count: The use of sertraline significantly reduced the mean sperm count compared to control groups ($p<0.05$). Mean sperm count in S20 group (30.2 ± 2.77) decreased significantly ($p<0.05$) compared to control group (39.6 ± 2.07) and other groups (Figure 1).

Sperm motility: Sperm motility in S20 group (68.2 ± 30.94) decreased significantly ($p<0.05$) compared to control group (89.1 ± 37.87) and other groups, whereas the S20+vitamin E group (78.2 ± 27.10) showed a significant difference ($p<0.05$) with the S20 group (Figure 1).

Sperm viability: The mean percentage of sperm viability in the S20 group (75.3 ± 4.20) decreased significantly ($P<0.05$) compared with the control groups (92.3 ± 6.71) and other groups. The mean percentage of sperm viability in the S20+E group (83.2 ± 2.38) showed significant difference ($P<0.05$) with the S20 group (Figure 2, Figure 4 A).

Evaluation of mature sperm: The number of spermatozoa in the S20 group (72.1 ± 0.58) decreased significantly ($P<0.05$) compared with the control group (97.1 ± 4.14) and other groups. There was also a significant difference ($p<0.05$) in the number of sperm with mature nucleus between the S20+E group (83.1 ± 4.81) and the S20 group (Figure 2, Figure 4 B).

Evaluation of sperm DNA damage: The percentage of spermatozoa that had double strand DNA damage increased significantly in the S20 group (21.2 ± 8.38) compared to the control group (5.1 ± 6.51) and the other groups ($p<0.05$). Sperm DNA damage was significantly ($p<0.05$) reduced in the S20+E group (16.1 ± 8.92) compared to the S20 group (Figure 3, Figure 4 C).

Evaluation of abnormal sperm count: There was a significant increase in the mean abnormal sperm count in S10 (19.1 ± 0.58) and S20 (25.2 ± 8.04) groups compared to control group (10.1 ± 4.14) and other groups ($p<0.05$). The S20+E group (17.2 ± 8.28) also had a significant difference ($p<0.05$) with the S20 group (Figure 3).

Evaluation of testosterone test: Testosterone levels in the S20 group (34.1 ± 0.20) showed a significant decrease compared to the control group (20.3 ± 0.36) and the other groups ($P<0.05$). Testosterone levels in the S20+E groups (86.1 ± 0.25) also showed a significant difference ($P<0.05$) compared to the S20 groups (Table 1).

Evaluation of serum total antioxidant capacity (TAC): Total antioxidant capacity in S20 group (53.0 ± 0.04) showed a significant decrease compared to control group (90.0 ± 0.04) and other groups and there was a significant difference ($p<0.05$) in the S20+E group (71.0 ± 0.05) compared to the S20 group ($p<0.05$) (Table 1).

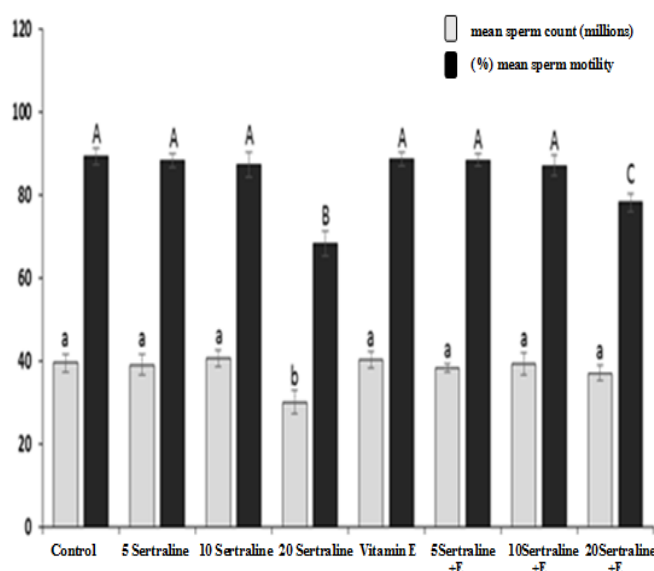


Figure 1. Comparison of sperm count and sperm motility in different experimental groups

Data are expressed as Mean \pm SD. Non-similar letters indicate significant differences in each column ($P<0.05$).

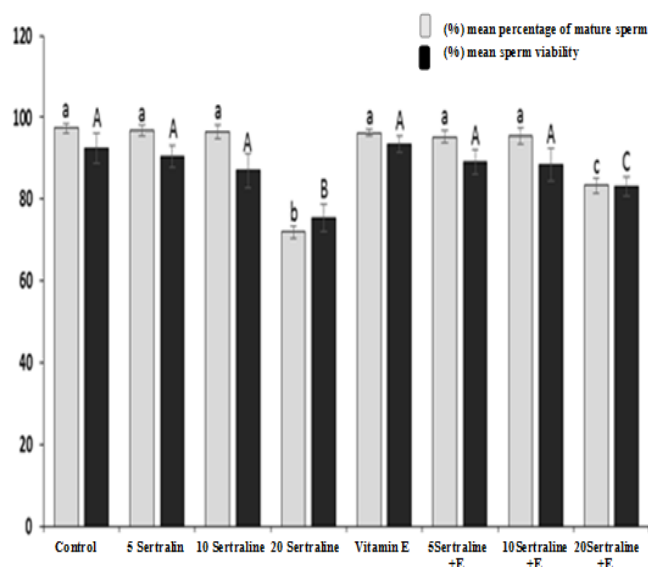


Figure 2. Comparison of mean sperm viability (percentage of viable sperm) and mean percentage of mature sperm in different experimental groups

Data are expressed as Mean \pm SD. Non-similar letters indicate significant differences in each column ($P<0.05$).

Evaluation of Malondialdehyde (MDA): Sertraline in the S20 group (99.5 ± 0.46) significantly increased the level of malondialdehyde compared to the control group (1.82 ± 0.29) and other groups ($P<0.05$). Moreover, the difference in S20+E group (13.4 ± 0.32) was significant ($p<0.05$) in comparison with S20 group (Table 1).

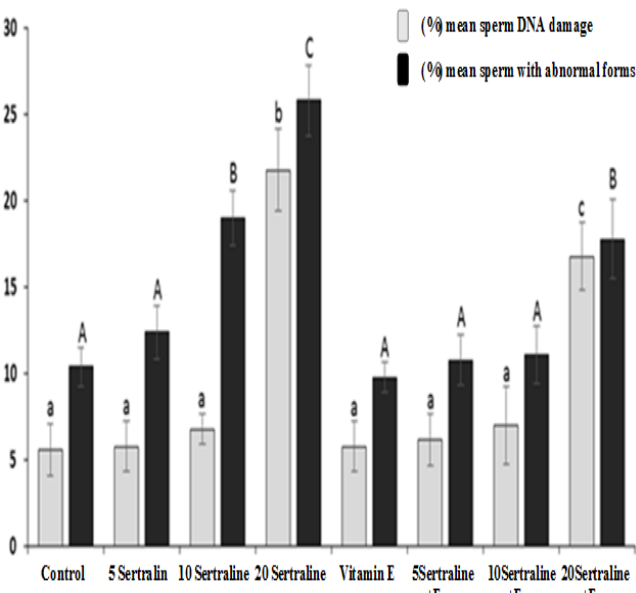


Figure 3. Comparison of mean percentage of sperm DNA damage and mean percentage of sperm with abnormal forms in different experimental groups
Data are shown as Mean \pm SD. Non-similar letters indicate significant differences in each column ($P<0.05$).

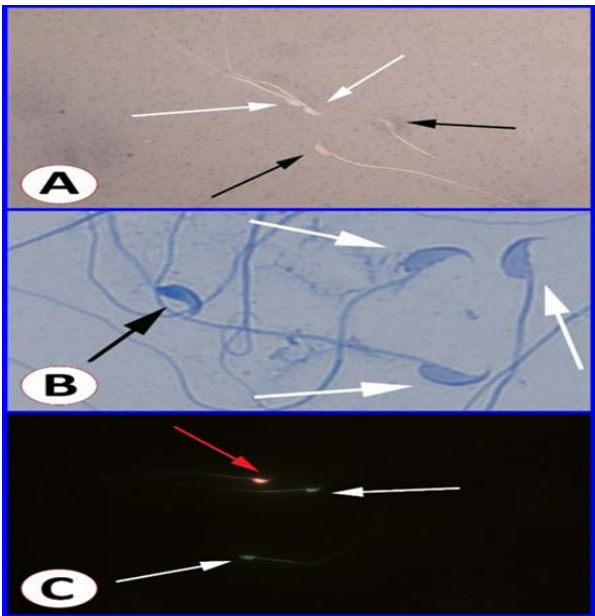


Figure 4. (A): Microscopic view of spermatozoa in Eosin-Nigrosin staining; viable spermatozoa (white arrows) can be viewed in unstained head, and dead spermatozoa (black arrows) in stained head. (B): Microscopic view of spermatozoa in aniline blue staining; sperm with mature nucleus can be viewed in light blue head (white arrows) and immature sperm in dark blue head (black arrow). (C): Microscopic view of sperm in acridine orange staining; sperm with healthy DNA can be viewed in green head (white arrows) and sperm DNA damage can be viewed in red head (red arrow).

Table 1. The results of biochemical tests of testosterone, total antioxidant capacity and serum malondialdehyde in different experimental groups

Group	Testosterone (ng/ml)	TAC (nmol/mg)	MDA (nmol/mg)
Variable	Mean \pm SD	Mean \pm SD	Mean \pm SD
Control	20.3 \pm 0.36 ^a	0.906 \pm 0.041 ^a	82.1 \pm 0.29 ^a
5 ml Sertraline	20.3 \pm 0.26 ^a	0.846 \pm 0.085 ^a	2.07 \pm 0.33 ^a
10 ml Sertraline	90.2 \pm 0.26 ^a	0.830 \pm 0.070 ^a	1.92 \pm 0.41 ^a
20 ml Sertraline	31.1 \pm 0.20 ^b	0.536 \pm 0.041 ^b	5.99 \pm 0.46 ^b
Vitamin E	33.3 \pm 0.40 ^a	0.903 \pm 0.055 ^a	1.70 \pm 0.25 ^a
5 ml Sertraline+Vitamin E	03.3 \pm 0.15 ^a	0.886 \pm 0.041 ^a	1.93 \pm 0.31 ^a
10 ml Sertraline+Vitamin E	96.2 \pm 0.25 ^a	0.863 \pm 0.040 ^a	1.95 \pm 0.28 ^a
20 ml Sertraline+Vitamin E	86.1 \pm 0.25 ^c	0.710 \pm 0.055 ^c	4.13 \pm 0.32 ^c

ng/ml: nanogram per milliliter. nmol/mg: nanomole per milligram. Non-similar letters indicate significant differences in each column ($P<0.05$).

Discussion

In this study, vitamin E improved sperm quality parameters, testosterone levels and sertraline-induced oxidative parameters. Sertraline at a dose of 20 mg caused damage to the aforementioned parameters, and vitamin E intake improved these parameters, which is consistent with previous studies (17,21). Infertility is a growing concern (22). Serotonin plays an important role in the process of spermatogenesis, and excessive serotonin leads to impaired sperm function and the negative effects of increased serum and urine serotonin levels on sperm parameters have been reported (8).

Sertraline causes significant structural changes in the male reproductive system by disrupting the function of the endocrine system and decreasing testosterone levels (23), which is consistent with the findings of the present study. The significant decrease in sperm quality parameters following sertraline administration may be justified by the role that sertraline plays in the formation of oxidative stress in testicular tissue and weakening of antioxidant defense (17,24) and the high sensitivity of sperms and germ cells in seminiferous tubules to damage caused by oxidative stress due to their unique cell membrane structure (25).

It has been clearly shown that the use of sertraline damages the mitochondrial membrane, which results in overproduction of reactive oxygen species (ROS) and causes oxidative stress (17,24). Evidence suggests that oxidative stress can induce sperm abnormalities through various mechanisms such as lipid peroxidation of the plasma membrane of sperm, impairment of sperm motility and morphology, and induction of sperm DNA damage (26). Studies have also shown that sperm DNA damage due to oxidative stress increases the apoptosis of immature reproductive cells, leading to a decrease in sperm concentration (26,27).

Similarly, our study also showed that the use of sertraline in the S20 group increased sperm DNA damage by mechanisms involved in oxidative stress. Another study has shown that the use of sertraline increases abnormal sperms (16,28), which is consistent with the results regarding the S10 and S20 groups but not with the S5 group. Sperm analysis experiments in 320 men aged 18-50 years have shown that SSRIs affect sperm parameters and decrease sperm viability and motility (28), which is in line with the results of this study regarding decreased sperm viability and motility in S20 group. In the present study, sertraline reduced the mean sperm count by 20 mg, which is consistent with

the results of previous studies on rats (17). In a clinical trial on patients with premature ejaculation, sertraline was found to have negative effects on sperm count and maturation (18), which is consistent with the results of the present study in the S20 group. (26). Vitamin E is one of the strong antioxidants that have been shown to have protective effect on the quality and quantity of sperm, fertilization and fertility rate in humans (19,20).

In this study, vitamin E resulted in a significant increase in sperm count, motility, viability and maturation and a significant decrease in the percentage of sperm DNA damage and abnormal spermatozoa, which is consistent with previous studies showing that Vitamin E reduces the damage to spermatozoa and spermatogenic cells against SSRIs and other oxidizing agents (29). Sertraline reduces testosterone levels (17,18). Testosterone, as the most important androgen hormone, plays a key role in the development and proliferation of germ cells and the differentiation of round spermatids into elongated spermatids and supports sexual function by affecting Leydig cells (22). The mechanism of action of sertraline may also be due to its effect on Leydig cells, which results in decreased testosterone levels (30).

Intraperitoneal injection of 10 mg/kg body weight sertraline caused negative feedback to the brain and hypothalamic–pituitary–gonadal axis of the rat and inhibited the activity of steroidogenic enzymes in the testicular tissue and thus, there was a decrease in the level of testosterone in the blood (17,30), which is consistent with the findings of this study that showed a significant decrease in serum testosterone levels in sertraline receiving groups. Decreased serum antioxidant capacity and increased levels of malondialdehyde in sertraline-treated rats were reported (31-33), which is consistent with the results of the S20 group in this study. Administration of 5, 10 and 20 mg/kg body weight sertraline for 28 days also increased the level of malondialdehyde in rats, which was consistent with the results regarding the S20 group (17). On the other hand, vitamin E significantly decreased the levels of malondialdehyde and significantly increased total antioxidant capacity compared to sertraline-treated groups. In confirmation of the above results, studies have also shown that vitamin E improves the oxidative parameters mentioned in SSRIs and other oxidative damage in rats (34,35). The present study showed that sertraline impaired sperm quality and testosterone levels probably through oxidative stress. Vitamin E, on the

other hand, reduces the antioxidant capacity of sertraline-induced side effects such as impaired sperm quality parameters, testosterone levels, and oxidative parameters in the male reproductive system.

Acknowledgment

Hereby, we would like to thank the Deputy of Research and Technology of the University of Tehran for their support.

References

1. Trivedi MH, Lin EH, Katon WJ. Consensus recommendations for improving adherence, self-management, and outcomes in patients with depression. *CNS Spectr*. 2007;12(8 Suppl 13):1-27.
2. Pirraglia PA, Stafford RS, Singer DE. Trends in Prescribing of Selective Serotonin Reuptake Inhibitors and Other Newer Antidepressant Agents in Adult Primary Care. *Prim Care Companion J Clin Psychiatry*. 2003;5(4):153-7.
3. Montgomery SA, Schatzberg AF, Guelfi JD, Kasper S, Nemeroff C, Swann A, et al. Pharmacotherapy of depression and mixed states in bipolar disorder. *J Affect Disord*. 2000;59(Suppl 1):S39-56.
4. Zayed MA, Hawash MF, Fahmey MA, El-Habeeb AA. Structure investigation of sertraline drug and its iodine product using mass spectrometry, thermal analyses and MO-calculations. *Spectrochim Acta A Mol Biomol Spectrosc*. 2007;68(3):970-8.
5. Cascade E, Kalali AH, Kennedy SH. Real-World Data on SSRI Antidepressant Side Effects. *Psychiatry (Edmont)*. 2009;6(2):16-8.
6. Ferguson JM. SSRI Antidepressant Medications: Adverse Effects and Tolerability. *Prim Care Companion J Clin Psychiatry*. 2001;3(1):22-7.
7. Pacher P, Kecskemeti V. Cardiovascular side effects of new antidepressants and antipsychotics: new drugs, old concerns?. *Curr Pharm Des*. 2004;10(20):2463-75.
8. Riggan L, Koren G. Effects of selective serotonin reuptake inhibitors on sperm and male fertility. *Can Fam Physician*. 2015;61(6):529-30.
9. Brambilla P, Cipriani A, Hotopf M, Barbui C. Side-effect profile of fluoxetine in comparison with other SSRIs, tricyclic and newer antidepressants: a meta-analysis of clinical trial data. *Pharmacopsychiatry*. 2005;38(2):69-77.
10. Montgomery SA, Kasper S. Comparison of compliance between serotonin reuptake inhibitors and tricyclic antidepressants: a meta-analysis. *Int Clin Psychopharmacol*. 1995;9(Suppl 4):33-40.
11. Montgomery SA. Efficacy in long-term treatment of depression. *J Clin Psychiatry*. 1996;57(Suppl 2):24-30.
12. Attia SM, Bakheet SA. Citalopram at the recommended human doses after long-term treatment is genotoxic for male germ cell. *Food Chem Toxicol*. 2013;53:281-5.
13. Csoka AB, Shipko S. Persistent sexual side effects after SSRI discontinuation. *Psychother Psychosom*. 2006;75(3):187-8.
14. Bataineh HN, Daradka T. Effects of long-term use of fluoxetine on fertility parameters in adult male rats. *Neuro Endocrinol Lett*. 2007;28(3):321-5.
15. Alzahrani HA. Sister chromatid exchanges and sperm abnormalities produced by antidepressant drug fluoxetine in mouse treated in vivo. *Eur Rev Med Pharmacol Sci*. 2012;16(15):2154-61.
16. Jahromy MH, Moghadam AA. Effects of Sertraline on Sperm Motility, Number and Viability and Its Relation to Blood Levels of Testosterone, FSH and LH in Adult Male Mice. *Advances in Sexual Medicine*. 2014;4(2):17-24.
17. Atli O, Baysal M, Aydogan-Kilic G, Kilic V, Ucarcan S, Karaduman B, et al. Sertraline-induced reproductive toxicity in male rats: evaluation of possible underlying mechanisms. *Asian J Androl*. 2017;19(6):672-9.
18. Akasheh G, Sirati L, Noshad Kamran AR, Sepehrmanesh Z. Comparison of the effect of sertraline with behavioral therapy on semen parameters in men with primary premature ejaculation. *Urology*. 2014;83(4):800-4.
19. Bramley PM, Elmadfa I, Kafatos A, Kelly FJ, Manios Y, Roxborough HE, et al. Vitamin E. *J Sci Food Agric*. 2000;80(7):913-38.
20. Chandra AK, Chatterjee A, Ghosh R, Sarkar M. Vitamin E-supplementation protect chromium (VI)-induced spermatogenic and steroidogenic disorders in testicular tissues of rats. *Food Chem Toxicol*. 2010;48(3):972-9.
21. Zarei L, Sadrkhanlou R, Shahrooz R, Malekinejad H, Eilkhani Zadeh B, Ahmadi A. Protective effects of vitamin E and Cornus mas fruit extract on methotrexate-induced cytotoxicity in sperms of adult mice. *Vet Res Forum*. 2014;5(1):21-7.
22. Sheibani MT, Anbara H, Morovvati H, Razi M, SalarAmoli J. Effect of Long Term-Administration of Aspartame on Sperm Quality, Testosterone and Oxidant Parameters in Mice. *SJIMU*. 2019;27(3):150-61. [In Persian]
23. Safarinejad MR. Evaluation of endocrine profile and hypothalamic-pituitary-testis axis in selective serotonin reuptake inhibitor-induced male sexual dysfunction. *J Clin Psychopharmacol*. 2008;28(4):418-23.

24. Erdemir F, Atilgan D, Firat F, Markoc F, Parlaktas BS, Sogut E. The effect of sertraline, paroxetine, fluoxetine and escitalopram on testicular tissue and oxidative stress parameters in rats. *Int Braz J Urol.* 2014;40(1):100-8.
25. Kasahara E, Sato EF, Miyoshi M, Konaka R, Hiramoto K, Sasaki J, et al. Role of oxidative stress in germ cell apoptosis induced by di(2-ethylhexyl)phthalate. *Biochem J.* 2002;365(Pt 3):849-56.
26. Anbara H, Shahrooz R, Razi M, Malekinejad H, Najafi G. The effect of vitamin C on mice hemolytic anemia induced by phenylhydrazine: an animal model study using histological changes in testis, pre-implantation embryo development, and biochemical changes. *Iran J Basic Med Sci.* 2018; 21(7): 668-77.
27. Safarinejad MR. Sperm DNA damage and semen quality impairment after treatment with selective serotonin reuptake inhibitors detected using semen analysis and sperm chromatin structure assay. *J Urol.* 2008;180(5):2124-8.
28. Relwani R, Berger D, Santoro N, Hickmon C, Nihsen M, Zapantis A, et al. Semen parameters are unrelated to BMI but vary with SSRI use and prior urological surgery. *Reprod Sci.* 2011;18(4):391-7.
29. Jalili T, Khaki A, Ghanbari Z, Imani AM, Hatefi F. A study of the therapeutic effects of vitamin E on testicular tissue damage caused by fluoxetine. *Crescent J Med & Biol Sci.* 2014;1(2):37-41.
30. Hedger MP, Khatab S, Gonzales G, de Kretser DM. Acute and short-term actions of serotonin administration on the pituitary-testicular axis in the adult rat. *Reprod Fertil Dev.* 1995;7(5):1101-9.
31. Chen S, Xuan J, Couch L, Iyer A, Wu Y, Li QZ, et al. Sertraline induces endoplasmic reticulum stress in hepatic cells. *Toxicology.* 2014;322:78-88.
32. Abdel-Salam OM, Youness ER, Khadrawy YA, Sleem AA. Brain and liver oxidative stress after sertraline and haloperidol treatment in mice. *J Basic Clin Physiol Pharmacol.* 2013;24(2):115-23.
33. Azimzadeh K, Jafarpour H, Adldoost S. Sertraline alters level of adenosine deaminase activity, oxidative stress markers and cardiac biomarkers (homocysteine cardiac troponin I) in rats. *Pharm Biomed Res.* 2017;3(3):17-22.
34. Pascoe GA, Fariss MW, Olafsdottir K, Reed DJ. A role of vitamin E in protection against cell injury. Maintenance of intracellular glutathione precursors and biosynthesis. *Eur J Biochem.* 1987;166(1):241-7.
35. Rezaie Agdam H, Razi M, Amniattalab A, Malekinejad H, Molavi M. Co-Administration of Vitamin E and Testosterone Attenuates The Atrazine-Induced Toxic Effects on Sperm Quality and Testes in Rats. *Cell J.* 2017;19(2):292-305.