

## A Case Report of Malignant Peripheral Nerve Sheath Tumor of the Breast

Kh. Abdal (DDS, MS), M. Darvishi (PhD), M.R. Hafezi Ahmadi (MD)<sup>\*3</sup>

1. Department of Oral and Maxillofacial Pathology, Faculty of Dentistry, Ilam University of Medical Sciences, Ilam, I.R.Iran

2. Department of Anatomy, Faculty of Medicine, Ilam University of Medical Sciences, Ilam, I.R.Iran

3. Department of Pathology, Ilam University of Medical Sciences, Ilam, I.R.Iran

---

J BabolUniv Med Sci; 21; 2019; PP: 1-5

Received: July 14<sup>th</sup> 2018, Revised: Oct 17<sup>th</sup> 2018, Accepted: Nov 3<sup>rd</sup> 2018.

### ABSTRACT

**BACKGROUND AND OBJECTIVE:** Breast sarcomas may be primary or secondary. Primary sarcoma of the breast is one of the extremely rare cases of breast malignancies whose possibility of occurrence is estimated to be 0.5% of all types of breast cancers and less than 5% of the all sarcomas. In this study, we present a woman with a malignant peripheral nerve sheath tumor in the breast.

**CASE REPORT:** A 40-year old woman with a painless palpable mass in the right breast referred to Imam Khomeini hospital of one year ago. According to mammography and cytology and with the possibility of breast cancer patient undergoing surgery and the mass was removed. Histopathology feature and positive immunohistochemical markers such as S100 and vimentin confirmed malignant peripheral nerve sheath tumor of the breast (Triton type). Patient after mastectomy, radiation and chemotherapy regimen received and now, after 12 months no recurrence or metastasis has been seen.

**CONCLUSION:** In breast cancer tumors, early diagnosis and appropriate therapeutic such as surgery, radiotherapy and chemotherapy are recommended to increase overall survival and improve their quality of life.

**KEY WORDS:** *Malignant Peripheral Nerve Sheath Tumor, Breast Sarcoma, Triton Type.*

---

#### Please cite this article as follows:

Abdal Kh, Darvishi M, Hafezi Ahmadi MR. A Case Report of Malignant Peripheral Nerve Sheath Tumor of the Breast. J Babol Univ Med Sci. 2019; 21:1-5.

---

\*Corresponding Author: M. Mashhadi Akbar Boojar (PhD)

Address: Department of Pharmacology and Toxicology, Faculty of Pharmacy, Baqiyatallah University of Medical Sciences, Mollasadra Avenue, Tehran, Iran.

Tel: +982182483414

E-mail: mahdimashhadi@yahoo.com

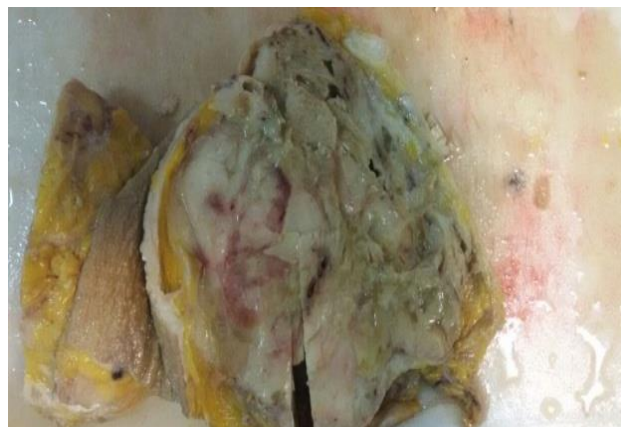## Introduction

For the first time in 1985, Callery et al. named sarcoma breast tumors (1). Breast sarcomas are very rare and occurrence is estimated to be 0.5% of all types of breast cancers and less than 5% of the all sarcomas (2). Breast sarcomas may be primary and secondary, the primary type is created at age 40 and secondarily at age 45-50 due to a history of radiation or chronic lymph adenoma (3). The most common sarcomas include fibroushistiocytoma, fibrosarcoma, leiomyosarcoma, angiosarcoma and some rare cases such as osteosarcoma and malignant peripheral nerve sheath tumor (MPNST)(4). Neurofibrosarcoma in breast is one of the most rare malignant tumors in the breast, and so few cases have been reported. Metastasis to lymph nodes accures rarely by sarcoma but unfortunately recurrence and prognosis of this lesion is poor and survival rate of these patients is about 38% (3-5). Regarding the rare occurrence of primary sarcomas in the breast with the diagnosis of a malignant tumor with a skeletal muscle differentiation (Triton type) which has been reported so far very rare, in this paper we are reporting a case of a 40-year-old woman with malignant peripheral nerve sheath tumor (Triton type) of the right breast.

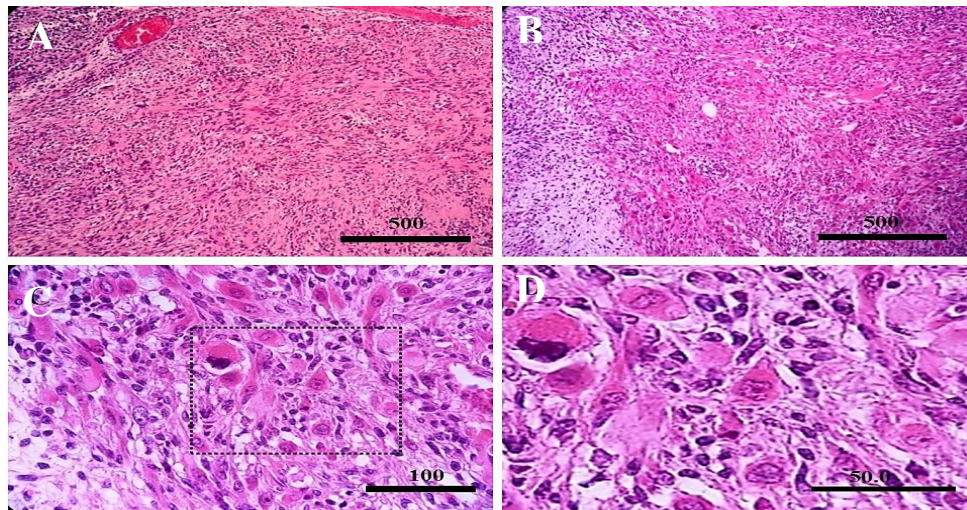
## Case Report

A 40-year-old woman was referred to Imam Hospital in Ilam, Iran with a painless palpable mass in the right breast. The patient had no history of trauma or family history of breast cancer. Her laboratory tests were normal. Clinical evaluation of the patient showed palpable mass in the right breast. No clinical changes

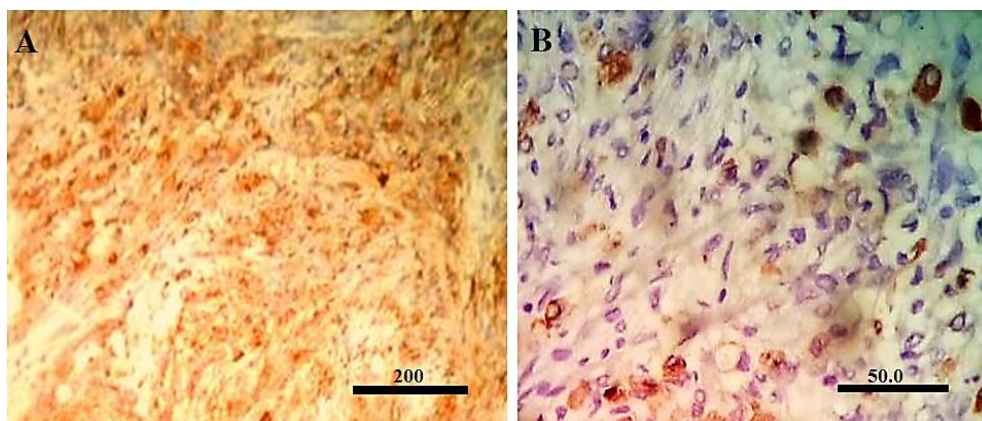
were seen in the skin of the breast and axillary nodes. Ultrasound, mammography and aspiration of the mass was requested. Mammography results suggested a mass with well-defined margins localized that appeared similar to breast fibroadenoma. Cytological evaluation also showed atypia and dysplastic cells in the patient's lesion. Based on the results of the assessment the probability of breast cancer was introduced. The patient underwent anesthesia and total mastectomy surgery. The gross lesion was a solid firm mass with gray color, measuring 2×4×5 Cm), surrounded by normal adipose breast parenchyma. Multiple foci of tissue necrosis were seen (Fig 1). Microscopic examination of the lesion showed malignant proliferation of spindle cells with scant eosinophilic cytoplasm, abundant mitotic figures (11 mitoses per 10 HPF), wave-like spindle cells in a fibrous stroma and some myxomatous areas. Muscle strips were seen in some areas (Fig 2). Considering the findings, the possibility of a MPNST was suggested and immunohistochemical staining was performed. Epithelial markers (CK, EMA) were negative and mesenchymal markers (vimentin, S100, SMA) were positive (Fig 3). Based on the evaluation of clinical, radiographic and microscopic results, malignant peripheral nerve sheath tumor of the breast (Triton type) was confirmed. Computed tomography (CT) and magnetic resonance imaging (MRI) scans were done on the thoracic region and abdomen and fortunately, there was no metastasis. She was then referred to the oncology ward and underwent a chemoradiotherapy regimen (doxorubicin and cisplatin). 12 months follow up after mastectomy surgery, the patient is still without tumor recurrence and metastasis. This report is prepared with the patient's consent.



**Figure 1. A surgical specimen of the breast with gray color and necrosis of areas with irregular margins that surrounded by normal fatty tissue**



**Figure 2.** Histological findings of the tumor specimen showing ( A,B,C&D) malignant proliferation of spindle cells with scant eosinophilic cytoplasm, abundant mitotic figures and wave-like spindle cells (wavy) in a fibrous stroma and some myxomatous areas. Muscle strips were seen in some areas ( hematoxylin and eosin, 200×)



**Figure 3.** Immunohistochemistry, Vimentin (A) and S100 (B) protein were consistently expressed by tumour cells (200×)

## Discussion

In our patient was observed a tangible mass without lymph node involvement. Clinically, breast sarcomas are firm–painless mass well defined marginal with rapid growth. It is in differential diagnosis with sarcomatoid carcinoma and carcinoma of the breast (3-5). The nature of these sarcomas' formation is unknown, but some researchers believe that it is due to the multipotentiality in breast stromal mesenchymal cells. Malignant peripheral nerve sheath tumor (MPNST) of the breast (Triton type) is one of the most rare malignant tumors of the breast of which few cases have been reported so far. The occurrence of MPNST in the breast has been reported to be less than 0.1% (4). Neurofibrosarcomas are 5% of all sarcomas in body, often occurring in the trunk and extremities.8 MPNST originate from a peripheral nerve sheath and schwann or

perineurial cell. MPNST is also named malignant schwannoma, malignant neurilemmoma, neurogenic sarcoma, and neurofibrosarcoma. MPNST prevalence is earlier than other sarcomas without gender predilection (6-9). MPNST are most common in young adults (20-50 years old) but the patients with neurofibromatosis is about one decade earlier, also MPNSTs have an association with previous radiation (9 to 36 yr after radiation therapy) (4,10). Half of MPNSTs occur in the neurofibromatosis (Von Recklinghausen's disease of the skin)(3). Our patient had no history of irradiation and features of neurofibromatosis, and she had been infected primary sarcoma of the breast. Findings of aspiration of breast cancer shown atypical cells with malignant morphology (nuclei hyperchrom, cell pleomorphism)(11). Histologically, MPNSTs composed of fascicles of atypical spindle-shaped cells



which often resemble the cells of fibrosarcoma but with differentiation toward elements of the nerve sheath, Schwann cell, and perineural cell (wavy or comma-shaped nuclei) (3,6). Frequent mitoses, focal necrosis, cellular myxoid areas and heterologous elements such as skeletal muscle differentiation (malignant Triton tumor), cartilage, bone and glandular structures are typical (8). In our case, microscopic examination (variable cellularities with wavy shaped nuclei, necrosis, pleomorphism, high mitotic activity and muscle differentiation) showed that the tumor can be a MPNST with skeletal muscle differentiation. MPNST have to be distinguished from malignant spindle cell sarcoma such as fibrosarcoma and leiomyosarcoma and malignant Fibrous histiocytoma thus a immunohistochemical analysis to be helpful in indistinguishable cases.

MPNST immunostaining markers including S-100, CD57, Leu-7 and myelin can be used to identify nerve sheath differentiation (7). In our case, IHC analysis showed a diffuse and strong positivity pattern for S100. So far the number of MPNSTS has been reported very rare and has been presented by Chalkoo, Panigrahi, Dhingra and Shuayb (5-7,9). other case of breast sarcomas included osteosarcoma, angiosarcoma and liposarcoma that it has been reported by Szajewss, Corde and Nuria (8,10,11). Mammography, computed tomography (CT) and magnetic resonance imaging (MRI) is useful for tumor diagnosis but is nonspecific and for the definitive diagnosis of the tumor requires the mass biopsy and microscopic evaluateion (10). Mammography finding is nonspecific and shown a well-defined density with or without calcifications that diagnosis of MPNST of the breast is difficult with other breast sarcomas and benign fibroadenomas because radiological findings is nonspecific (10,11). Sarcomas rarely spread by lymphatic routes, instead mostly being transmitted through the bloodstream to other parts of the body, thus causing metastases that mostly metastasize to bone and then to liver and lungs (7-8). The risk of breast sarcoma increases in patients with

neurofibromatosis syndrome, Gardner's syndrome, Werner's syndrome and Li-Fraumeni syndrome.<sup>2</sup> Since MPNST of breast is rare, there is no optimum targeted therapy but it seems the standard treatment and choice for these patients includes complete surgical resection (mastectomy with margins around), with high-dose radiotherapy and chemotherapy (9).

Margins are examined by frozen section technique to minimize the probability of recurrence and radiotherapy reduces the risk for recurrence as well. Chemotherapy regimens (doxorubicin, cisplatin) improves the chance of survival and quality of life (11, 12). Unfortunately, the prognosis of this lesion is poor despite the therapies mentioned and the 5-year survival rate for these patients is 38%.

28% of patients experience recurrence usually within the first two years and 41% of patients face distant metastases. Prognosis of breast sarcoma depends on primary tumor size, amount of mitosis, the cell atypia and removal of suspicious margin during surgery (8). In our study, mastectomy was performed and then patient received injectable chemotherapy regimen (doxorubicin and cisplatin) for 3 weeks and radiation therapy with a total dose of 50 Gy in 25 fractions. To date our patient has not showed local and metastatic recurrence after surgery for more than 1 year. Beacause breast sarcomas are rare and mostly spread through the bloodstream to other parts of the body, early diagnosis of lesions in early stages and using frozen section techniques, radiotherapy and chemotherapy are of great importance to the survival of these patients and to enhance their quality of life.

### Acknowledgment

Hereby, we thank of Ilam of university of medical sciences for their support of this research.

**Conflict of interest:** The authors declare that they have no conflict of interest.

## References

1. Al-Benna S, Poggemann K, Steinau HU, Steintraesser L. Diagnosis and management of primary breast sarcoma. *Breast Cancer Res Treat.* 2010 Aug;122(3):619-26.
2. Smith TB, Gilcrease MZ, Santiago L, Hunt KK, Yang WT. Imaging features of primary breast sarcoma. *Am J Roentgenol.* 2012; 198(4):386-93.
3. Surov G, Holzhausen HJ, Ruschke K, Spielmann R.P. Primary breast sarcoma: prevalence, clinical signs, and radiological features. *Acta Radiol.* 2011;52(6): 597-601.
4. Nizri E, Merimsky O, Lahat G. Optimal management of sarcomas of the breast: an update. *Expert Rev Anticancer Ther.* 2014; 14(6): 705-10.
5. Shuayb Md, Begum R. Unusual primary breast cancer – malignant peripheral nerve sheath tumor: a case report and review of the literature. *J Med Case Rep.* 2017; 11: 161.
6. Dhingra KK, Mandal S, Roy S, Khurana N. Malignant peripheral nerve sheath tumor of the breast: case report. *World J Surg Oncol.* 2007; 5: 142.
7. Panigrahi S, Mishra SS, Das S, Kumar Dhir M. Primary malignant peripheral nerve sheath tumor at unusual location. *J Neurosci Rural Pract.* 2013; 4( 1): S83–6.
8. Conde DM, Morais LC, Pacheco CF, Ferreira RB, Sousa-e-Silva ÉP, Nunes AR, et al. Primary osteosarcoma of the breast: pathological and imaging findings. *Rev Assoc Med Bras.* 2015 ;61(6):497-9.
9. Chalkoo M, Ahangar S, Laharwal A, Patloo AM, Mohd A, Ahmed Dar Sh. Primary malignant peripheral nerve sheath tumor of the breast, a case report. *Surg Sci.* 2011;2: 137-9.
10. Szajewski M, Kruszewski WJ, Ciesielski M, Smialek-Kusowska U, Czerepko M, Szeffel J. Primary osteosarcoma of the breast: A case report. *Oncol Lett.* 2014;7(6):1962-4.
11. Li N, Cusidó MT, Navarro B, Tresserra F, Baulies S, Ara C, et al. Breast sarcoma. A case report and review of literature. *Int J Surg Case Rep.* 2016;24:203-5.
12. Agrawal AS, Rao S, Gupta DO. Breast sarcoma: A rarity. *Clin Cancer Investig J.* 2014;3(4):338-40.