Original Article

J Babol Univ Med Sci
Vol 19, Issu 11; Nov 2017. P:50-57

The Protective Effect of Zinc against Hepatotoxicity Induced by Arsenic During Gestation and Lactation in Rat Neonate

F. Jafari (MSc)[1], F. Talebpour Amiri (PhD)[2], A. Esmaeilnejad Moghaddam (PhD)[2*]
M. Zargari (PhD)[2], H. Arab (MSc)[2]

1. Student Research Committee, Faculty of Medicine, Mazandaran University of Medical Sciences, Sari, I.R.Iran
2. Cellular and Molecular Biology Research Center, Mazandaran University of Medical Sciences, Sari, I.R.Iran

J Babol Univ Med Sci; 19(11); Nov 2017; PP: 50-7
Received: May 2nd 2017, Revised: Aug 15th 2017, Accepted: Oct 3rd 2017.

ABSTRACT

BACKGROUND AND OBJECTIVE: Arsenic (Ar) by induced oxidative stress in gestation and lactation period can cause teratogenicity properties in the neonate. On the other hand, the evidence suggests the antioxidant effect of zinc (Zn). So, the aim of present study was to evaluate protective effect of Zn against Ar-induced hepatotoxicity during gestation and lactation in rat neonate.

METHODS: In this experimental study, 24 adult wistar rats of the 35 mice that their pregnancy was confirmed, randomly divided into four groups including:I) Control group; II) Ar group, (20 mg/kg/day); III) Zn group; (5 mg/kg/day) and IV) Ar+Zn group. Ar and Zn administration was daily with intragasticaly method. At the end of the experimental period (42 days: 21 of gestation and 21 of lactation) after anesthesia hepatic samples were taken for biochemical assessment of malondialdehyde (MDA), glutathione (GSH) and histopathological assessment.

FINDINGS: The MDA and GSH mean±SD in Ar group was 41.56±7.2 and 7.05±1.36, respectively. Also, in Ar+Zn group assessed 26.26±1.84 and 13.79±1.34, respectively. This difference was significant between groups ($P<0.05$). Also, the histopathological finding by using scoring system in Ar+Zn in compare to Ar group was significant ($P<0.01$).

CONCLUSION: Our findings showed that administration of Zn as antioxidant can decreased the toxically and teratogenic effect of Ar during gestation and lactation.

KEY WORDS: *Arsenic, Zinc; Hepatotoxicity, Gestation, Lactation.*

Please cite this article as follows:

Jafari F, Talebpour Amiri F, Esmaeilnejad Moghaddam A, Zargari M, Arab H. The Protective Effect of Zinc against Hepatotoxicity Induced by Arsenic During Gestation and Lactation in Rat Neonate. J Babol Univ Med Sci. 2017; 19(11):50-7.

* **Corresponding author: A. Esmaeilnejad Moghaddam (PhD)**
Address: Faculty of Medicine, Payambar (PUH) Academic Department, Farahabad Street, 18 km, Sari, I.R.Iran
Tel:+98 11 33543764
E-mail: mog1339@gmail.com

[DOR: 20.1001.1.15614107.1396.19.11.7.8]
[DOI: 10.18869/acadpub.jbums.19.11.50]

Introduction

Arsenic (Ar) is one of the most dangerous environmental pollutants that can cause several lesions (1). Ar compounds in the environment and in the human body are inorganic (AS2O3, arsenate) and organic (AS2O5, arsenate). Groundwater, soil, infected rice and some marine foods are from Ar sources (2). In many countries, high concentrations of non-organic Ar in drinking water are a major health concern (3).

And in Asia's continent, chronic poisoning is becoming a serious epidemic, with more than 100 Millions of people are at risk of exposure to groundwater contaminated with high concentrations of this substance (4, 5). In Iran, the amount of Ar in drinking water in the city and villages of Hashtrood city and in Ibrahim Abad and Babanazar villages in Kurdistan province was higher than standard (6). Ar compounds result in DNA damage, lipid peroxidation, and reduction of antioxidant defense levels (7). Long-term exposure to it can also cause skin and internal cancers, including liver, lung, kidney and bladder, and increase mortality rates (8). In a study by Najafzadeh et al. exposure to sodium arsenic led to birth defects (9). Therefore, it causes anemia by reducing the amount of red blood cells and blood hemoglobin (10) and prolonged exposure to this substance in pregnant mothers also leads to a decrease in the growth rate, increased mortality and neural tube defects (9,10).

The main cause of teratogenicity and toxicity of organic Ar or its metabolites is induction of oxidative stress, changes in gene expression, and disturbance in cell signal exchange (11,12). A study by Vergil et al showed that exposure to high-dose arsenic (30 mg/kg) in pregnant mothers causes fetal death in the uterus, while a low dose (5 to 10 mg/kg) has a teratogenic effect which is one of the most important target organs, kidney and liver due to metabolism (13).

However, in pregnant mothers, the placenta as a protective barrier prevents the passage of some elements such as cadmium (Cd) to the fetus, but it is still unable to withstand other elements such as lead (Pb), mercury (Hg) and arsenic (Ar) protects the fetus (14). Therefore, considering the role of oxidative stress in lesions caused by arsenic poisoning, it has been suggested that the use of antioxidants should be considered in order to obtain better treatment results in the toxicity of Ar (15). Zinc (Zn), as a protective agent against oxidative stress, regulates many physiological functions (16). The two main mechanisms for protecting sulfohedril groups against oxidation and inhibiting the production of active oxygen (17) are by analyzing metals (18) for the antioxidant property of Zn. On the other hand, according to studies, evidence suggests the beneficial effects of this substance in confronting teratogenic events, and therefore its deficiency during pregnancy can lead to abnormalities in the central and skeletal nervous system of the fetus (19). Other benefits for Zn are diversification in the biological activity of the element (20). Zn supplementation has been shown to increase levels of glutathione (GSH) and glutathione transferase (GST) (21) and decrease in the production of oxidants such as malondialdehyde (MDA) and superoxide dismutase (SOD) (22).

Zn intake during pregnancy and lactation can reduce the toxicity of Ar and reduce the severity of the changes. The aim of this study was to investigate the protective effect of Zn on liver toxicity induced by Ar during embryonic and lactation period in rats.

Methods

Preparation of Animals: In this study, 35 female Wistar rats weighing 250-280g were obtained from laboratory animal's center of Mazandaran University of Medical Sciences. In all stages of the study, ethical principles were observed according to the ethical standards of the University of Mazandaran Medical Sciences (with ethical code: 2077). All animals were kept in standard temperature conditions (23±2°C), humidity, and easy access to food, and 12 hours of darkness and brightness in standard cages. Each female rat was placed in a cage with a male rat separately. The next day, all female rats were subjected to vaginal test, and 24 female rats of 35 rats that confirmed their pregnancy after mating, and negative rats were excluded from the study. The female rats with positive test each were kept in a special cage and the positive vaginal test day was considered as the zero day of pregnancy.

Designing and Grouping: Animals with positive vaginal test were divided into 4 groups of 6: I-control group that did not receive any substance; II-zinc group (ZnSO4) dissolved in distilled water, which daily received 20 mg/kg via gavage (23), III) Arsenic group

[DOR: 20.1001.1.15614107.1396.19.11.7.8]
[DOI: 10.18869/acadpub.jbums.19.11.50]

(Ar), that Sodium meta-arsenate (purchased from Merck®), was dissolved in distilled water and received a dose of 5mg/kg via gavage (24); IV. The group treated with Ar and Zn simultaneously with the above doses.

The treatment duration was 42 days (21 days during the pregnancy and 21 days in the lactation period), which were intervened to pregnant female rats and all the compounds were administered to the rats from the beginning of the study. At the end of the study, after registering the total number of births and the number of dead births, 2 to 4 infants of rats were randomly selected from each female rat in each group. The total weight of the newborns was recorded and then the rat kid's livers were removed under the anesthetic conditions with ketamine and xylene after measuring the weight, half of the liver was taken to biochemical study and the other half to histopathologic study and at the end, the rats were sacrificed using Medicinal overdose.

Biochemical study: The liver samples, after washing in a PBS solution were immediately frozen and kept at a temperature of -80 °C until biochemical analysis. Two enzymes were evaluated as indicators of oxidative stress including malondialdehyde (MDA) and glutathione (GSH). All enzymes were analyzed by standard spectrophotometry using a biochemical assay kit purchased from Pars Test Company.

Histopathologic study: The liver samples after clearing of blood were immediately placed in 10% formalin solution for 24 hours. After the passage from alcohol and xylol solutions, molded in paraffin, and sections of 5 micrometers thick was prepared from each paraffin mold by using Microtome, and placed on a slide. Histopathologically, the prepared lams were deparaffinized and put in xylol and alcohol, stained with Hematoxylin and Eosin (H & E). To study the slides the light microscope was used (DME; Leica Microsystems Inc., Buffalo, NY, USA).

A standard scoring system was also used to estimate the damage and comparison in different groups of liver tissues (25,26). In this method, from every section, five images were randomly drawn from different points. The changes were evaluated based on standard scoring so that the zero (for healthy tissue without any damage) (1) (for healthy tissue and only with minor damage, including partial distribution of hepatocytes with healthy central venous veins), 2 (moderate damage of the liver tissue including distribution of liver lobes, central venous damage, minor cell necrosis), and 3 (for liver tissue with severe damage, including no healthy lobes, central venous ruptures, widespread cell necrosis, departed triad, and lack of organized romak ropes).

Analysis: SPSS software version 20 was used for data analysis. The Kolmogorov-Smirnov test was used to determine the normal distribution of data. The data were normal. One-way ANOVA test was used for statistical analysis and Tukey test was used to analyze the difference between the two groups and $p < 0.05$ was considered significant.

Results

General condition: The total weight of neonates in all three control groups, Zn and Ar+Zn was significantly higher than the Ar group ($p<0.05$). Regarding the weight of the liver in the studied groups, the Ar group showed a significant decrease compared to other groups, but it was not statistically significant. Compared to control groups, Zn and Ar+Zn in the Ar group, the total number of births decreased and the dead birth increased, significantly ($p<0.05$) (table 1).

Biochemical analysis: The results of biochemical tests showed that the level of MDA in the Ar group was significantly higher than the control and Zn groups ($p<0.05$), whereas this change in Ar+Zn receiving group decreased and their difference was significant ($p<0.05$) (Fig 1).

Also, in the case of glutathione (GSH), there was a significant decrease in Ar group than other groups, while there was no significant difference between the Ar+Zn group compared to the control and Zn groups (Fig 2).

Table1. General status of newborns born in study groups

Group / Variable	Control	Zn	Ar	Ar+Zn
Total weight(g)	45.2±4.6	46.4±6.65	37.2±1.3*	42.2±2.38
Weight of liver tissue (mg)	218.2±34.67	237.2±34.35	180.2±6.82	205.2±35.62
Total birth	9.33±1.96	8.87±2.66	4.66±2.06*	7.16±1.83
Dead birth	0.0±0.0	0.0±0.0	1.16±1.1*	0.06±0.01

*p<0.05 compared with control, Zn, and Ar+Zn groups

[DOR: 20.1001.1.15614107.1396.19.11.7.8]
[DOI: 10.18869/acadpub.jbums.19.11.50]

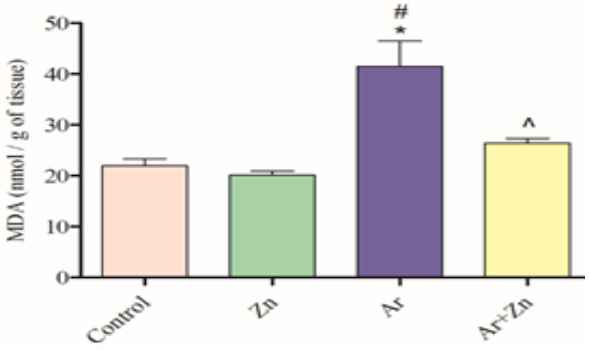

Figure 1. Evaluation the data obtained from the measurement of MDA level in the studied groups. *Indicates a significant level of p=0.001 into the control group and Zn. # Indicates a significant level of p<0.05 compared to the Ar+Zn group. ^Indicates a significant level of p>0.05 compared to the control group and Zn

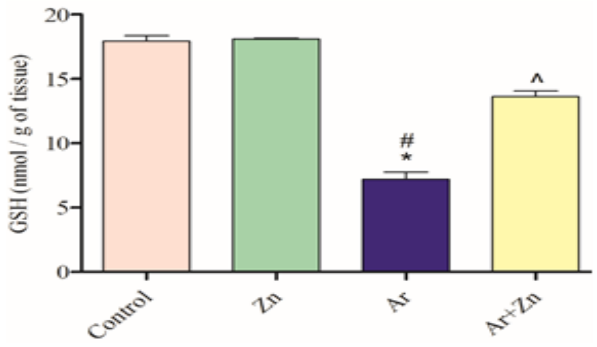

Figure 2. Evaluation of data from GSH level measurement in the studied groups. * Indicates a significant level of p <0.0001 compared to the control group and Zn. # Indicates a significant level of p <032/0 into the group Ar+Zn . ^ Indicates a significant level of p> 0.05 compared to the control group and Zn

Histopathological analysis: The results of histopathologic studies are shown in Fig. A3. The evaluation in the animal liver of the control and Zn groups showed a normal structure. Investigations in the tissue samples of the Ar receiving group showed folding of the cells, nucleotide pyknosis, lysation of the nucleus, especially in the precentral region and cytoplasmic dislocation.

Also, the decrease in sinusoidal space was due to cellular swelling, necrosis of the cells due to the presence of hyaline states and the deformation of the normal form of the hepatocytes lobes. The simultaneous consumption of Ar and Zn caused liver lobules to maintain their structure compared with the Ar receiving group. The results of the evaluation based on the scoring system at different points of the body showed significant changes in the Ar group compared to the control and Zn groups ($p<0.05$), but these changes in the Ar+Zn group were similar to those in the control and Zn groups were significant ($p<0.05$) (Fig B3).

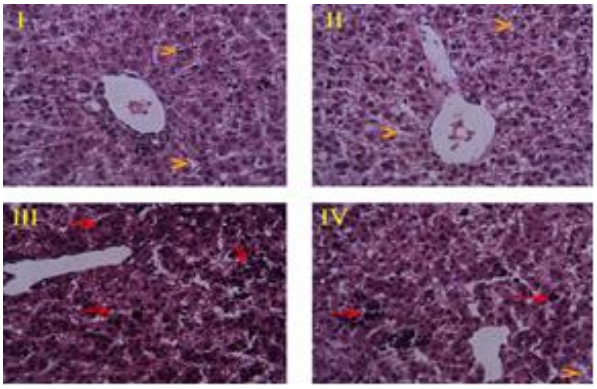

Figure A3. Coloring (H & E). With magnification of 400*. I) Neonatal rat liver, which received only normal saline. II) Neonatal rat liver received daily Zn at a dose of 20 mg/kg. III) Rat neonate liver receiving daily 5 mg/kg of arsenic indirectly through placenta during pregnancy and infancy. IV) Neonatal rat liver received daily arsenic with zinc in groups 2 and 3. Arrow: represents the pyknotic nuclei. Top of arrow: represents the sinusoids in the liver lobes.

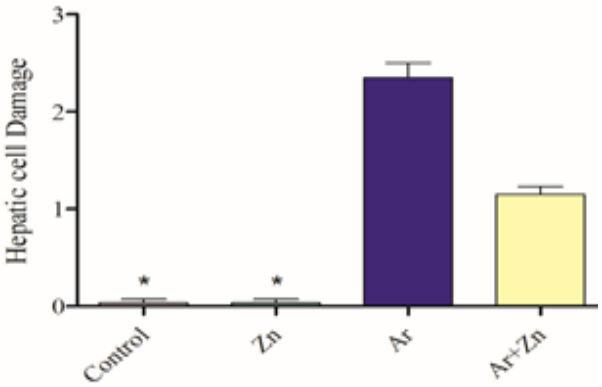

Figure B3. The results of the scoring based on the standard system for assessing liver damage based on severity of injury. *Indicates a significant level of p <0.05 into the Ar and Ar+Zn groups.

Discussion

The results of this study showed that administration of Zn during pregnancy and lactation to pregnant rats can prevent significant changes in histological and oxidative stress in newborns. Ar as a poison has

[DOR: 20.1001.1.15614107.1396.19.11.7.8]
[DOI: 10.18869/acadpub.jbums.19.11.50]

several effects on enzyme activity as well as body proteins (7). Ar inhibits mitochondrial energy activities by competing with phosphate when oxidative phosphorylation and NAD inhibition (27).

It also can affect mitochondrial enzymes and disturb membrane respiration in the cell. These events can in some way be related to the cytotoxicity of Ar (11,28). Arsenic crossing the placenta causes teratogenic damage and toxicity in the fetus, and during lactation, the mother's breast can only play a role as a protective barrier (29). Ar also inhibits the Succinic dehydrogenase enzyme and causes oxidation and phosphorylation processes (30).

Since oxidative stress and free radical production can play a significant role in embryonic anomalies, Ar seems to play a major role in these abnormalities. Zn, as an antioxidant agent (31), can inhibit oxidative stress by absorbing free radicals and reducing lipid peroxidation (18). Although the highest amount of Zn absorption is from the oral and initial intestinal segments (32), studies have shown that Zn can pass through the placenta via the microvillus in the syncytiotrophoblast (33).

We also showed in the previous study that zinc as exogenous antioxidant can reduce arsenic-induced renal toxicity during pregnancy and lactation (34). Therefore, it can be one of the most important benefits of prescribing this antioxidant during pregnancy. The results of this study showed that Ar administration during pregnancy and lactation reduces the growth of fetus and liver, which was consistent with the results of similar studies (30, 35). However, it was observed that this weight loss was significantly lower in the Ar+Zn recipient group, than the Ar group.

This level of prevention can be due to the features that are associated with Zn. Because Zn, in addition to the above, also plays a role in cell proliferation and affects the enzyme system that plays a role in cell division and proliferation. In addition, Zn has an effect on growth hormone, cell membrane, and secondary cell signaling responsible for cell proliferation (36). Therefore, in the present study, Zn showed that, in addition to overcoming the oxidant properties of Ar, it could be effective in preventing anthropometric changes of toxicity. The results also showed that the total infant birth and stillbirth rates were higher in the Ar group than in other groups, while in the Ar+Zn recipient group this amount was little had not significant relationship with the control and zinc groups,tThis finding was consistent with the results of similar studies (30, 37). This finding can also be due to antioxidant properties and inhibitory effects of Zn, as well as effects on fetal growth. Also, results from biochemical changes showed that Ar administration increases the lipid peroxidation (MDA) and reduces the antioxidant endogenous glutathione (GSH) (31, 38). However, these changes were not significant in the Ar+Zn recepient group, and were not significant in relation to control and Zn groups.

Lipid peroxidation, as a major pathologic agent, can cause creation of free radicals and inappropriate cellular function, and in the embryonic period it can lead to a teratogenic process and toxicity in various organs of the body (39). Our results showed that Ar administration significantly increased the MDA level, and subsequently administration of Zinc significantly reduced the amount of this destructive factor. As mentioned above, Zn acts as an antioxidant agent and passes through the placenta as a free radical scavenger and can reduce the risk of oxidative stress to a large extent. The findings were consistent with the results of similar studies on the antioxidant properties of Zn (18, 23,25,38). On the other hand, endogenous antioxidants which produced by the cell itself are able to prevent cell damage from free radicals (40).

Therefore, GSH has been considered as one of these important enzymes, reduced by the effect of toxins and eventually oxidative stress with high potency, in which case the cell is damaged and ultimately the organ is affected by functional impairment it also becomes disabled (41).

This case was shown in the present study in the Ar group that the GSH level was significantly reduced compared to other groups. While in the Ar+Zn recipient group, this antioxidant has largely prevented the occurrence of these events, which also highlights the anti-oxidant properties of Zn. This finding was also consistent with the results of similar studies (23, 42). Histopathologic findings also showed a slight change in the Ar+Zn recipient group compared to the Ar group. This finding was consistent with the results of the similar studies (43,44), which confirmed that Ar administration during pregnancy caused teratogenic changes and damage to the tissue structure, and the use

[DOR: 20.1001.1.15614107.1396.19.11.7.8]
[DOI: 10.18869/acadpub.jbums.19.11.50]

of an antioxidant to inhibit the effect of this poison can prevent these events. Therefore, it can be concluded that Ar causes tissue changes and changes in the concentration of liver tissue damage index in a newborn exposed to poison during pregnancy and infancy. Also, this study showed that Zn can be used in this situation, with respect to its antioxidant properties, by the mechanism of neutralizing free radicals caused by confrontation with Ar as an improved approach. However, this hypothesis requires more testing for practical and clinical use.

Acknowledgments

Hereby, we would like to thank the Head of the Cellular and Molecular Biology Research Center and Laboratory Animal Research Center of Mazandaran University of Medical Sciences.

[DOR: 20.1001.1.15614107.1396.19.11.7.8]
[DOI: 10.18869/acadpub.jbums.19.11.50]

References

1.Rodríguez-Lado L, Sun G, Berg M, Zhang Q, Xue H, Zheng Q, et al. Groundwater arsenic contamination throughout China. Sci. 2013;341(6148):866-8.

2.Fowler BA. Biological and environmental effects of arsenic. 1st ed: Elsevier; 2013.

3.Mandal BK, Suzuki KT. Arsenic round the world: a review. Talanta. 2002;58(1):201-35.

4.Charlet L, Polya DA. Arsenic in shallow, reducing groundwaters in southern Asia: an environmental health disaster. Element. 2006;2(2):91-6.

5.Meharg AA. Arsenic in rice–understanding a new disaster for south-east asia. Trend Plant Sci. 2004;9(9):415-7.

6.Mosaferi M, Yunesion M, Mesdaghinia A, Naidu A, Nasseri S, Mahvi A, et al. Arsenic occurrence in drinking water of IR of Iran: the case of Kurdistan Province. Fate of arsenic in the environment Dhaka: BUET-UNU International Symposium, International Training Network Centre, Bangladesh University of Engineering and Technology, United Nations University, Tokyo; 2003: CiteSeer.

7.Kumar S, Yedjou CG, Tchounwou PB. Arsenic trioxide induces oxidative stress, DNA damage, and mitochondrial pathway of apoptosis in human leukemia (HL-60) cells. J Experiment Clin Cancer Res. 2014;33(1):1.

8.Flanagan SV, Johnston RB, Zheng Y. Arsenic in tube well water in Bangladesh: health and economic impacts and implications for arsenic mitigation. Bull World Health Organiz. 2012;90(11):839-46.

9.DeSesso JM. Teratogen update: inorganic arsenic. Teratol. 2001;64(3):170-3.

10.Hood RD. Effects of sodium arsenite on fetal development. Bullet Environment Contaminat Toxicol. 1972;7(4):216-22.

11.Tyler CR, Allan AM. The effects of arsenic exposure on neurological and cognitive dysfunction in human and rodent studies: a review. Curr Environment Health Rep. 2014;1(2):132-47.

12.Wlodarczyk BJ, Palacios AM, Chapa CJ, Zhu H, George TM, Finnell RH, editors. Genetic basis of susceptibility to teratogen induced birth defects. Am J Med Gen Part C. 2011;157(3):215-26.

13.Ferm VH. Arsenic as a teratogenic agent. Environment Health Perspect. 1977;19:215.

14.Llanos MN, Ronco AM. Fetal growth restriction is related to placental levels of cadmium, lead and arsenic but not with antioxidant activities. Reproduc Toxicol. 2009;27(1):88-9.

15.Messarah M, Klibet F, Boumendjel A, Abdennour C, Bouzerna N, Boulakoud MS, et al. Hepatoprotective role and antioxidant capacity of selenium on arsenic-induced liver injury in rats. Experiment Toxicol Pathol. 2012;64(3):167-74.

16.Haase H, Rink L. Zinc signals and immune function. Biofactors. 2014;40(1):27-40.

17.Villeda-Hernandez J, Barroso-Moguel R, Mendez-Armenta M, Nava-Ruız C, Huerta-Romero R, Rıos C. Enhanced brain regional lipid peroxidation in developing rats exposed to low level lead acetate. Brain Res Bull. 2001;55(2):247-51.

18.Bray TM, Bettger WJ. The physiological role of zinc as an antioxidant. Free Radical Biol Med. 1990;8(3):281-91.

19.Brenton D, Jackson M, Young A. Two pregnancies in a patient with acrodermatitis enteropathica treated with zinc sulphate. Lancet. 1981;318(8245):500-2.

20.Irwin JJ, Sterling T, Mysinger MM, Bolstad ES, Coleman RG. ZINC: a free tool to discover chemistry for biology. J Chem Info Model. 2012;52(7):1757-68.

21.Goel A, Dani V, Dhawan D. Protective effects of zinc on lipid peroxidation, antioxidant enzymes and hepatic histoarchitecture in chlorpyrifos-induced toxicity. Chem-Biolog Interac. 2005;156(2):131-40.

22.Cabré M, Ferré N, Folch J, Paternain JL, Hernàndez M, del Castillo D, et al. Inhibition of hepatic cell nuclear DNA fragmentation by zinc in carbon tetrachloride-treated rats. J Hepatol. 1999;31(2):228-34.

23.Özcelik D, Nazıroglu M, Tunçdemir M, Çelik Ö ,Öztürk M, Flores-Arce M. Zinc supplementation attenuates metallothionein and oxidative stress changes in kidney of streptozotocin-induced diabetic rats. Biolog Trace Element Res. 2012;150(1-3):342-9.

24.Uygur R, Aktas C, Caglar V, Uygur E, Erdogan H, Ozen OA. Protective effects of melatonin against arsenic-induced apoptosis and oxidative stress in rat testes. Toxicol Indust Health. 2016;32(5):848-59.

[DOR: 20.1001.1.15614107.1396.19.11.7.8]
[DOI: 10.18869/acadpub.jbums.19.11.50]

25.Sankar P, Gopal Telang A, Kalaivanan R, Karunakaran V, Manikam K, Sarkar SN. Effects of nanoparticle-encapsulated curcumin on arsenic-induced liver toxicity in rats. Environment toxicol. 2015;30(6):628-37.
26.Ye X, Feng Y, Tong Y, Ng K-M, Tsao S, Lau GK, et al. Hepatoprotective effects of Coptidis rhizoma aqueous extract on carbon tetrachloride-induced acute liver hepatotoxicity in rats. J Ethnopharmacol. 2009;124(1):130-6.
27.Yen Y-P, Tsai K-S, Chen Y-W, Huang C-F, Yang R-S, Liu S-H. Arsenic induces apoptosis in myoblasts through a reactive oxygen species-induced endoplasmic reticulum stress and mitochondrial dysfunction pathway. Arch Toxicol. 2012;86(6):923-33.
28.Rozman KK, Klaassen CD. Casarett and Doull's Toxicology: The Basic Science of Poisons. McGraw-Hill, New York; 2007.
29.Vahter M. Effects of arsenic on maternal and fetal health. Annual review of nutrition. 2009;29:381-99.
30.Najafzadeh H, Khaksary Mahabady M, Haji A. A comparative study of the effects of sodium arsenite and nanoparticles of sodium arsenite on the apparent and skeletal malformations in rat embryos. J Babol Univ Med Sci. 2015;17(10):60-6. [In Persian]
31.Ahmad M, Wadaa MA, Farooq M, Daghestani MH, Sami AS. Effectiveness of zinc in modulating perinatal effects of arsenic on the teratological effects in mice offspring. Biolog Res. 2013;46(2):131-8.
32.Lubitz J, Cai L, Kramarow E, Lentzner H. Health, life expectancy, and health care spending among the elderly. England J Med. 2003;349(11):1048-55.
33.Donangelo CM, King JC. Maternal zinc intakes and homeostatic adjustments during pregnancy and lactation. Nutrients. 2012;4(7):782-98.
34.Ghabaee DNZ, Amiri FT, Moghaddam AE, Khalatbary AR, Zargari M. Administration of zinc against arsenic-induced nephrotoxicity during gestation and lactation in rat model. Journal of nephropathology. 2017;6(2):74.
35.Carpenter SJ. Developmental analysis of cephalic axial dysraphic disorders in arsenic-treated hamster embryos. Anatomy Embryol. 1987;176(3):345-65.
36.MacDonald RS. The role of zinc in growth and cell proliferation. J Nutrit. 2000;130(5):1500-8.
37.Ahmad SA, Sayed M, Barua S, Khan MH, Faruquee M, Jalil A, et al. Arsenic in drinking water and pregnancy outcomes. Environment Health Perspective. 2001;109(6):629.
38.Koudelova J, Mourek J. The lipid peroxidation in various parts of the rat brain: effect of age, hypoxia and hyperoxia. Physiolog Res Acad Scient Bohem. 1993;43(3):169-73.
39.Yagi K. Lipid peroxides in biology and medicine. 1st ed: Elsevier; 2012.
40.Ahmadvand H, Ghabaee DNZ, Malekshah AK, Navazesh A. Virgin olive oil ameliorates deltamethrin-induced nephrotoxicity in mice: A biochemical and immunohistochemical assessment. Toxicol Rep. 2016;3:584-90.
41.Sies H. Glutathione and its role in cellular functions. Free Radical Biolog Med. 1999;27(9):916-21.
42.Rostan EF, DeBuys HV, Madey DL, Pinnell SR. Evidence supporting zinc as an important antioxidant for skin. Int J Dermatol. 2002;41(9):606-11.
43.Bashir S, Sharma Y, Irshad M, Gupta SD, Dogra T. Arsenic-Induced Cell Death in Liver and Brain of Experimental Rats. Basic Clin Pharmacol Toxicol. 2006;98(1):38-43.
44.Roy S, Bhattacharya S. Arsenic-induced histopathology and synthesis of stress proteins in liver and kidney of Channa punctatus. Ecotoxicol Environment Safety. 2006;65(2):218-29.

[DOR: 20.1001.1.15614107.1396.19.11.7.8]
[DOI: 10.18869/acadpub.jbums.19.11.50]