

The Effect of Hydroalcoholic Extract of *Ziziphora Clinopodioides* Lam on Testicular Damage Caused by Diabetes Mellitus in Male Rats

N. Bolbol Haghighi (MSc)¹, S. Molzemi (MSc)*², Sh. Goli (PhD)³, H. Mohammad Sadeghi (MSc)⁴,
M. Aminian (MD)⁵

1.Department of Midwifery, Faculty of Nursing and Midwifery, Shahroud University of Medical Sciences, Shahroud, I.R.Iran

2.Department of Laboratory Sciences, Faculty of Medical Sciences, Islamic Azad University, Shahrood Branch, Shahroud, I.R.Iran

3.Research Center for Social and Behavioral Sciences in Health, Faculty of Public Health, Shahroud University of Medical Sciences, Shahroud, I.R.Iran

4.Department of Physiology, Faculty of Medicine, Shahid Sadoughi University of Medical Sciences, Yazd, I.R.Iran

5.Department of Internal Medicine, Faculty of Medicine, Aja University of Medical Sciences, Tehran, I.R.Iran

J Babol Univ Med Sci; 19(12); Dec 2017; PP: 43-9

Received: Jun 28th 2017, Revised: Apr 9th 2017, Accepted: Sep 21th 2017.

ABSTRACT

BACKGROUND AND OBJECTIVE: Considering that mellitus diabetes has adverse effects on spermatogenesis and male fertility and given the easy and safe access to herbal medicines to treat diabetes complications, this study investigated the preventive and therapeutic effects of *ziziphora clinopodioides* lam on testicular damage in male rats.

METHODS: In this experimental study, 32 male Wistar rats weighing 200 to 220 g were divided into four groups of eight. The control group, the group that became diabetic through intraperitoneal injection of 55 mg/kg streptozotocin, experimental group 1 (diabetic+100 mg/kg *ziziphora clinopodioides* lam by gavage) and experimental group 2 (diabetic +100 mg/kg *ziziphora clinopodioides* lam by gavage) that became diabetic after two months, and received *ziziphora clinopodioides* lam extract by gavage for five weeks. Blood samples were collected at the beginning of the fifth week, and the testes were examined macroscopically (right testis) (length, volume, weight and diameter of testes) and histologically (left testis) (spermatogenesis count).

FINDINGS: In the diabetic group, there was a significant decrease in spermatogonial cells (58.22 ± 6.11) compared with control (78.18 ± 10.20) ($p<0.001$) and significant decrease was observed in sertoli cells in diabetic group (5.55 ± 0.87), compared to the control group (17.33 ± 1.57) ($p<0.001$). In addition, a significant increase was observed in spermatid cells in the experimental group 2 (114.83 ± 4.80) compared with the experimental group 1 (100.33 ± 3.38) ($p<0.001$).

CONCLUSION: The results of the study showed that long-term administration of *ziziphora clinopodioides* lam is effective in the diameter and thickness of the spermatic ducts. Therefore, treatment with *ziziphora clinopodioides* lam can improve the spermatogenesis of diabetic men.

KEY WORDS: *Diabetes, Insulin, Testosterone.*

Please cite this article as follows:

Bolbol Haghighi N, Molzemi S, Goli Sh, Mohammad Sadeghi H, Aminian M. The Effect of Hydroalcoholic Extract of *Ziziphora Clinopodioides* Lam on Testicular Damage Caused by Diabetes Mellitus in Male Rats. J Babol Univ Med Sci. 2017;19(12):43-9.

* Corresponding author: S. Molzemi (MSc)

Address: Department of Laboratory Sciences, Shahrood Branch, Islamic Azad University, Shahrood, I.R.Iran

Tel: +98 23 32390380

E-mail: saharmlolzemi@yahoo.com

Introduction

Diabetes mellitus is a mode of chronic hyperglycemia, which is a major cause of microvascular and macrovascular diseases and affects almost all systems of the body. Increasing evidence indicates that oxidative stress increase in diabetic patients as a result of excessive production of reactive oxygen species (ROS= Reactive Oxygen Species) and reduced antioxidant defense; a process that begins initially and provides the condition for the disease. In diabetes, lipid oxidation, ANA and proteins increase over time. Reduced testosterone levels, damage to the reproductive glands, decreased libido and sexual behavior have been reported in diabetic patients. Diabetes also affects spermatogenesis.

The low quality of seminal fluid has also been reported in diabetic patients, which includes reduced sperm motility, reduced sperm count, and increased abnormal sperm (1). In India, about 92 million dollars is spent annually for treating diabetic patients with sexual dysfunction. Since sexual desire is highly significant for survival of the generation, overcoming this problem with the help of herbal medicines is important and universally accepted (2). In Iran, four to five million people suffer from diabetes (3).

Methods currently used to treat insulin-independent diabetes mellitus, such as changing the diet and oral hypoglycemic agents, have their specific limitations. The use of plants to treat diabetes mellitus is common worldwide, especially in the Middle East. The World Health Organization has also made recommendations regarding the use of these plants in these countries (3). Many plant species are used to treat diabetes mellitus in the traditional medicine of different nations due to their glucose-lowering properties (3).

Ziziphora clinopodioides lam is a plant belonging to *Ziziphora* species (Lamiaceae). The aerial parts of this plant are consumed as spice. This plant can be found in most regions of Iran and has nine native subspecies in Iran (4). All parts of this plant are used in traditional medicine. Many plant species are used for the treatment of diabetes mellitus in the traditional medicine of different nations due to their glucose-lowering properties (5). The effect of hydroalcoholic extract of *ziziphora clinopodioides lam* on the active pancreatic beta cells in streptozotocin (STZ)-induced type 1 diabetic rats has been shown to play an antioxidant and glucose-lowering role (5). Mahdavi et al. reported that intraperitoneal administration of *ziziphora clinopodioides lam* extract for 4 weeks

effectively increased the activity of antioxidant enzymes in the liver and kidney of STZ-induced diabetic rats. This extract significantly reduces malondialdehyde (a lipid marker) in diabetic rats, and increases the total antioxidant capacity in a dose-independent pattern (5). Therefore, *ziziphora clinopodioides lam* extract has a protective role against oxidative damage in STZ-induced diabetic rats, and can prevent the destructive effects of diabetes because of its antioxidant properties (6).

Konyalıoğlu et al. showed that treatment with aqueous *ziziphora clinopodioides lam* extract for 21 days induced a dose-dependent antihyperglycemic effect in STZ-induced diabetic rats. Their results showed the positive effects of *ziziphora clinopodioides lam* on rats that had STZ-induced abnormalities in lipoprotein profile, antioxidant status, and glucose tolerance. Hence, aqueous *ziziphora clinopodioides lam* extract is useful in controlling diabetes, lipid profile disorder and oxidative stress by activating pancreatic antioxidant enzymes (7). As a result, the aim of this study was to evaluate the effect of different doses of hydroalcoholic extract of *ziziphora clinopodioides lam* on insulin, serum glucose, testosterone and testicular damage caused by STZ-induced diabetes in rats.

Methods

Ziziphora clinopodioides lam In the spring of 2015, the plant was collected from the villages of Shahrood County and the scientific name of this plant was confirmed by professors of plant biosystematics of Islamic Azad University of Damghan with the code 15710040. After cleansing, the plant was dried in shade and then in the oven at 3 °C. Then, the dried leaves were powdered and about 80 g of them were placed in the Soxhlet extraction apparatus with 400 ml ethanol (80%) for 72 hours. The extract was then smoothed and dried by rotary device.

Animals: In this study, 32 male Wistar rats weighing 200-220 g were selected and divided into four groups of eight.

1.Control group: Including eight male rats that received citrate buffer peritoneally based on body weight in order to maintain a balance of body, as diabetes was induced in other groups.

2.Diabetic group: Animals became diabetic by receiving 55 mg/kg STZ (a product of the Sigma Company with the scientific code (S0130) through

intraperitoneal injection. Blood glucose measurement to induce diabetes mellitus was done 72 hours after a single injection of STZ (S0130) using the blood of the tail vein with the help of GLUCOCARD-01 device. Rats with blood glucose level higher than 250 mg / dl were considered diabetic (5).

3.Experimental group 1: Two months after becoming diabetic, they received 100 mg/kg *ziziphora clinopodioides lam* once a day by gavage.

4.Experimental group 2: Two months after becoming diabetic, they received 150 mg/kg *ziziphora clinopodioides lam* once a day by gavage.

The mice were kept in clean cages at a temperature of 22 – 24 °C, a light cycle of 12 hours of light and 12 hours of dark and relative humidity of 40 – 60%. At the beginning of the fifth week after anesthesia by ketamine and xylazine, samples were collected directly from the heart, and biochemical and hormonal factors of blood and macroscopic observations (such as weight, diameter, length, testicular volume) were evaluated. The testicular sections were placed in 10% formalin for histological experiments and were transferred to the lab.

Macroscopic examination: To test the weight of the testes, a scale with accuracy of 0.001 g was used. The length and diameter of the testes were also measured using Collis test tool and testicular volume was measured with the help of a graduated cylinders (1).

Seminiferous tubule diameter measurement: In order to fix the tissue, the prepared samples were placed in 10% formalin solution for 48 hours. After the tissue was fixed, it was passaged in paraffin for molding. Sections with a thickness of 5 μ were prepared sequentially using a microtome with fixed blade. The sections were transferred to bain-marie and placed on a slide impregnated with blood albumen glue. The samples were dried at room temperature and after 24 hours, the slides were ready for staining.

In this study, hematoxylin and eosin staining method was used. Seminiferous tubule diameter was also measured. 25 tubules were randomly selected in each transverse section of testis and the mean tubular diameter was calculated by measuring the small and big diameter of each tubule using a calibrated micrometer attached to the microscope. In addition, for evaluating spermatogenesis in the same number of tubules, the number of spermatocytes (1, 2), spermatid, the number of luminal spermatozoa and the thickness of the basement membrane were evaluated (2).

Sertoli cell count: 25 tubules were selected in each field and each transverse section of testis, and then the number of sertoli cells was counted under a microscope. The average of this number was calculated for each group (2). Tissue comparisons were performed in different groups by one-way ANOVA test via the following formula:

$$\sqrt{\text{Seminiferous tubule diameter}} = (\text{magnification} \times L) \times (\text{magnification} \times B)$$

L: Length (big diameter of each tubule), B: Width (small diameter of each tubule)

Testosterone analysis method: The testosterone analysis in serum and plasma is performed using the Gamma-B Testosterone kit (product of the Zist Chimi Company). Double antibody radioimmunoassay (RIA) method is the basis of this kit. In this kit, specified amounts of the sample, labeled testosterone (1-T125) and testosterone antiserum were added, respectively. After the samples were incubated at normal temperature, they were centrifuged to separate the precipitate. The number of occupied positions of antiserum by testosterone shows a negative correlation with the concentration of sample testosterone. Gamma counter and comparison of results with standard serum determines testosterone concentration.

Insulin hormone analysis method: After separating blood serum from the blood, the blood contents were measured by the Insulin Zist Chimi Kit (product of the Zist Chimi Company).

Blood glucose analysis method: After separating blood serum from the blood by Pars Azmoon kit, blood glucose was measured using the blood of the tail vein with the help of GLUCOCARD-01 device every other day to ensure that blood glucose levels in the study groups were high until the end of the experiment.

Statistical analysis: Statistical analysis was done using SPSS Ver. 21 statistical software. The compare the average values between the groups, one way ANOVA was used, and in cases where there was a significant response, post-hoc Tukey test was used to find the difference. $P < 0.05$ was considered significant.

Results

Diabetic animals suffered from multiple complications of diabetes, including overeating, overdrinking, and diarrhea. Testicular tissue was covered with albuginea layer in the control group and cell complexes of seminiferous tubule were observed.

Histological structures were found to be degraded in the diabetic group and significant reduction was observed in the cell complexes, and tissue structures significantly improved in the treatment group after administration of 150 mg/kg *ziziphora clinopodioides* lam (Table 1).

The number of spermatogenic cells decreased in the diabetic group compared to the control group and the number of spermatogenic cells in the experimental group 1 and 2 (depending on the dose of the medicine used) was significantly higher than that of the diabetic group ($p < 0.05$). In addition, significant increase was observed in the levels of spermatogenesis cells and the thickness of the basement membrane and sertoli cells in the experimental group 2, which received the drug at a higher concentration compared to the experimental group 1 (Fig 1).

An increase in the thickness of the basement membrane was observed in the diabetic group compared to the control group. It was also found that the atrophy of seminiferous tubules in diabetic rats

increased significantly, but this damage was reduced after administration of *ziziphora clinopodioides* lam. Significant decrease was observed in weight, diameter, length and volume of testicles in diabetic group in comparison with the control group. Furthermore, there was a significant increase in weight, diameter, length and volume of testicles in experimental group 2 in comparison with the diabetic group (Table 2).

After evaluating hormone and serum tests, the diabetic group showed a significant decrease in testosterone, and insulin levels compared to the control group and showed a significant increase in blood glucose levels compared to the control group.

In the experimental group 1 and 2, there was a significant increase in the level of insulin and testosterone compared to the diabetic group, and no significant increase was observed in the levels of insulin in experimental group 2 compared to experimental group 1. Significant decrease was observed in serum glucose level in experimental group 2 compared to the experimental group 1 (Table 3).

Table 1. Comparison of the number of testicular tissue cells in different groups

Study variables	Groups	Control Mean±SD	Diabetic Mean±SD	Experimental 1 Mean±SD	Experimental 2 Mean±SD
Spermatogony (number)		78.18±10.20 a	58.82±6.11 bc	65.52±2.16 cd	69.27±4.09 d
Spermatocyte (number)		63.33±3.29 a	48.33±5.46 b	54.83±4.04 c	57.63±2.66 d
Spermatoid (number)		125.85±2.94 a	78.32±5.39 b	100.33±3.38 c	114.83±4.80 d
Sertoli cells (number)		17.33±1.57acd	5.55±0.87 b	15.00±3.42 c	19.00±1.85 d
Basement membrane thickness (mm)		1.58±0.24 a	2.57±0.17 b	1.51±0.23 a	1.09±0.06 c
Seminiferous tubules (diameter) (mm)		267.64±7.41 a	196.36±7.35 b	236.10±9.46 c	241.93±6.46 c

Table 2. Comparison of morphological changes of testicular tissue in different groups, which were defined at ranges of $p < 0.05$, $p < 0.01$ and $p < 0.001$ in comparison with control group.

Study variables	Groups	Control Mean±SD	Diabetic Mean±SD	Experimental 1 Mean±SD	Experimental 2 Mean±SD
Testicular weight (gr)		2.53±0.45 a	1.15±0.21 b	1.71±0.21 c	1.78±0.55 c
Testicular diameter (mm)		1.18±0.18 a	0.67±0.12 b	0.88±0.14 b	1.22±0.21 a
Testicular length (mm)		2.04±0.03 a	1.41±0.25 b	1.70±0.14 ab	1.80±0.45 a
Testicular volume (cm ³)		2.05±0.16 a	1.04±0.10 b	1.27±0.21 b	1.55±0.20 c

Dissimilar letters represent a significant change ($p < 0.001$). Similar letters represent a non-significant change

Table 3. Comparison of hormones and blood serum in different groups

Study variables	Groups	Control Mean±SD	Diabetic Mean±SD	Experimental 1 Mean±SD	Experimental 2 Mean±SD
Testosterone		4.13±0.42 a	0.34±0.04 b	1.43±0.16 c	2.07±0.83 c
Insulin		4.69±0.37 a	0.10±0.07 b	2.65±0.36 c	3.11±0.45 c
Glucose		85.5±42.06 a	300.90±42.56 b	220.50±36.12 c	190.4±74.98 d

Dissimilar letters represent a significant change ($p < 0.05$). Similar letters represent a non-significant change

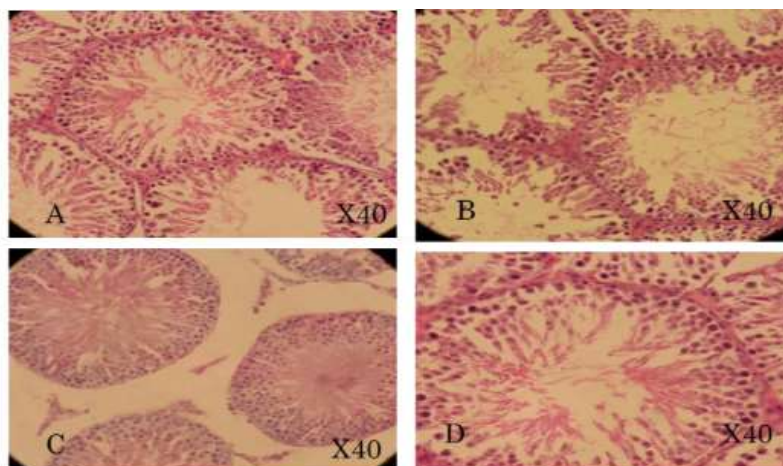


Figure 1. A, B, C, D letters represent the seminiferous tubules with 40X zoom. A shows the seminiferous tubules and sertoli cells in the control group. B shows seminiferous tubules shrink, increased interstitial space and decrease in spermatogonial cells and sertoli cells in the diabetic group. C shows the increase in the diameter of the seminiferous tubules and the increase in sertoli cells and a significant reduction in the interstitial space compared to diabetic in the experimental groups 1 and 2.

Discussion

In this study, the long-term treatment of diabetic animals with hydroalcoholic extract of *Ziziphora clinopodioides lam* improved testicular damage in macroscopic and microscopic examination of diabetes, compared with non-diabetic rats. In this study, there was a significant increase in testosterone and insulin levels in experimental groups compared to controls, which can be attributed to insulin secretion in the body that is stimulated by *Ziziphora clinopodioides lam* (8, 9). Diabetes mellitus increases oxidative stress and activates oxygen and leads to cellular damage through lipid peroxidation and oxidative damage to proteins and DNA (10).

The thickness of the basement membrane of seminiferous tubules plays an important role in spermatogenesis (11). During diabetes, the thickness of the basement membrane of the seminiferous tubules is increased. This increase leads to a decrease in the production of sperm and ultimately decreases the size of the seminiferous tubules. On the other hand, there is a positive correlation between tubular diameter and spermatogenesis activity (12).

Ziziphora clinopodioides lam inhibits the activation of protein kinase C, decreases the glycation of proteins, and lipids and, consequently, changes the activity of cell enzymes and increases antioxidants, and thereby reduces the devastating effects of diabetes on the testicular tissue. In this study, the medicine was given to rats by gavage for 35 days, which is the most appropriate period for gavage method because of the later bioavailability and can have a longer effect than subcutaneous or intraperitoneal injection. This study

has weaknesses and strengths; its weaknesses include the lack of examining and testing the anti-free radical activity of *Ziziphora clinopodioides lam* and not comparing this medicine with other alkaloids. The strengths include appropriate statistical population size and gavage method for administration, because the medicine affects the body over a longer period of time by gavage method. In the diabetic group, due to the damages caused by diabetes, including free radical production, it decreases the parameters of spermatogenesis cells and *Ziziphora clinopodioides lam* corrects these complications by stimulating spermatogenesis. The logical correlation between all the parameters suggests that as the concentration of medicine increased, the number of stem cells increased due to the presence of antioxidant substances, which indicates the positive effect of this medicine on the damage from diabetes. Ghafari et al. showed that treatment with hydroalcoholic extract of *Ziziphora clinopodioides lam* (50%) reduces serum glucose in alloxan-treated rats (4). A study reported the antihyperglycemic effect of *Ziziphora clinopodioides lam* fruit extract, a Greek medicine used by Greek physicians to treat diabetes, which was consistent with the results of the present study (13).

Ziziphora clinopodioides lam has an anti-diabetic action by activating the peroxisome proliferator-activated receptors (PPARs). The glycolic acid present in this part of the plant is an important and effective compound of this plant (14). Mammalian sperm cells have high levels of unsaturated fatty acids, plasmalogen and sphingomyelin, which are important substrates in oxidation action (15). Antioxidant

mechanisms are naturally present in reproductive tissues and prevent oxidative damage in gonadal cells and mature spermatozoa. The presence of antioxidants in *ziziphora clinopodioides lam* also eliminates the harmful effects of diabetes and improvement in tissue and macroscopy is observed in testis in experimental groups (16, 17).

In another study, the important effects of *ziziphora clinopodioides lam* were mentioned, which led to significant changes in tube diameter in seminiferous cells I and II, and inhibition of spermatogenesis in spermatocyte stages of small tubules of diabetic animals. According to our results, the decrease in the diameter of the seminiferous tubules and the increase in the diameter of the basement membrane in diabetic groups confirms this and is consistent with the results of this study. In addition, *ziziphora clinopodioides lam* seems to increase the diameter of the tubule, decrease the basement membrane and improve the spermatogenic cells using multiple mechanisms in treated diabetic groups (22).

In general, light microscopy evaluations in this study showed that in the testis of diabetic rats, the thickness of the basement membrane of the seminiferous tubules following diabetes reduced significantly during treatment with *ziziphora clinopodioides lam* for 5 weeks. In addition, according to the results of this study, the decrease in the number of sertoli cells results in a decrease in spermatogonia

count (because it is responsible for feeding the spermatogonial cells).

Sertoli cells play a vital role in spermatogenesis by providing physical, nutritional and hormonal signaling support for successful spermatogenesis. Therefore, when the number of sertoli cells is reduced, the number of spermatogonial cells is also severely reduced. In the present study, diabetes reduced the number of sertoli cells and subsequently reduced the number of spermatogonial cells.

This study indicated that diabetes in male rats caused testicular dysfunction, and treatment with *ziziphora clinopodioides lam* improved this dysfunction by improving the protection of seminiferous tubules and spermatogonial cells. In general, all diabetes-related damages in the experimental group 2 (diabetic±150 mg/kg *ziziphora clinopodioides lam*) improved better than the experimental group 1 (diabetic±100 mg/kg *ziziphora clinopodioides lam*), and it is recommended that men with diabetes mellitus consume 150 mg/kg hydroalcoholic extract of *ziziphora clinopodioides lam* daily.

Acknowledgments

Hereby, we express our deepest sense of gratitude and indebtedness to Yazd Medical School and all those who helped us with this research.

References

1. Anbarian F, Fatemi tabatabaei S, Kazeminezhad I, Mohammadian S. Effects of iron oxide nanoparticles and iron ions on reproductive indices of pregnant syrian rats and neuro-behavioral development of newborns. *J Babol Univ Med Sci.* 2016;18(3): 45-53 [In Persian]
2. Ghorbani Ranjbary A, Ghorbani Ranjbary N, Ghorbani Ranjbary Z, Jouibar N. Effects of intraperitoneal injection of extracts of *Origanum vulgare* on gonadotropin and testosterone hormones in male wistar rats. *J Babol Univ Med Sci.* 2014;16(4):57-63. [In Persian]
3. Ghorbani A, Farahani MA, Mohammadi N. Relationship between sleepiness, physical activity and functional outcomes in Iranian patients with type II diabetes. *Jundishapur J Chronic Dis Care.* 2014;3(1):54-60. [In Persian]
4. Ghafari H, Yasa N, Mohammadirad A, Dehghan G, Zamani MJ, Nikfar S, Khorasani R, et al. Protection by *Ziziphora clinopoides* of acetic acid-induced toxic bowel inflammation through reduction of cellular lipid peroxidation and myeloperoxidase activity. *Hum Exp Toxicol.* 2006;25(6):325-32.
5. Sadeghi H, Mansourabadi A, Moogooei M, Nahvinejad M. Antimicrobial effects of *Ziziphora clinopodioides* extracts on *Salmonella typhi* Vi+ in vitro, in vivo and amp; amp; cell culture. *Clinical Biochemistry.* 2011;44(13): 326-30.
6. Tian S, Shi Y, Zhou X, Ge L, Upur H. Total polyphenolic (flavonoids) content and antioxidant capacity of different *Ziziphora clinopodioides* Lam. extracts. *Pharmacognosy magazine.* 2011;7(25): 65-70.
7. Konyaltoglu S, Ozturk B, Meral G. Comparison of chemical compositions and antioxidant activities of the essential oils of two *Ziziphora* taxa from Anatolia. *Pharmaceutical Boil.* 2006;44(2):121-6.
8. Sadeghi H, Mansourabadi A, Emami S, Nahvinejad M, Moogooei M. The effect of *Ziziphora* ethanolic extract on active pancreatic beta cells on streptozotocin induced diabetic mice. *Iran J Diabete Metabol.* 2015;14(6):373-8. [In Persian].
9. International Diabetes Federation (IDF) Diabetes prevalence. Available From: <http://www.diabetesatlas.org>.
10. Saddichha S. Diagnosis and treatment of chronic insomnia. *Ann Indian Acad Neurol* 2010;13(2):94-102.
11. Vishnu A, Shankar A, Kalidindi S. Examination of the association between insufficient sleep and cardiovascular disease and diabetes by race/ethnicity. *Int J Endocrinol.* 2011;2011:789358.
12. Nagai M, Hoshida S, Kario K. Sleep duration as a risk factor for cardiovascular disease—a review of the recent literature. *Curr Cardiol Rev.* 2010 6(1):54-61.
13. Cho EH, Lee H, Ryu OH, Choi MG, Kim SW. Sleep Disturbances and Glucoregulation in Patients with Type 2 Diabetes. *J Korean Med Sci.* 2014;29(2):243-7.
14. Luyster FS, Dunbar-Jacob J. Sleep quality and quality of life in adults with type 2 diabetes. *Diabetes Educ.* 2011;37(3):347-55.
15. Maracy MR, Kheirabadi GR, Fakhari N, Zonnari R. Comparison of night time sleep quality in type 2 diabetics, impaired glucose tolerance cases and non-diabetics. *Iran J Endocrinol Metab.* 2011;13(2):165-72. [In Persian]
16. Ardani AR, Talaei A, Borhani Moghani M, Nejati R, Sabouri S, Solooti S, et al. Assessment the rules of demographic variables and body mass index in sleep quality among medical students. *J Fundamentals Mental Health.* 2012;14(2):132-9. [In Persian]
17. Kita T, Yoshioka E, Satoh H, Saijo Y, Kawaharada M, Okada E, et al. Short sleep duration and poor sleep quality increase the risk of diabetes in Japanese workers with no family history of diabetes. *Diabetes Care.* 2012;35(2):313-8.
18. Magee CA, Kritharides L, Attia J, McElduff P, Banks E. Short and long sleep duration are associated with prevalent cardiovascular disease in Australian adults. *J Sleep Res.* 2012;21(4):441-7.
19. Cappuccio FP, D'Elia L, Strazzullo P, Miller MA. Quantity and quality of sleep and incidence of type 2 diabetes a systematic review and metaanalysis. *Diabetes Care.* 2010;33(2): 414-20.
20. Altay B, Cetinkalp S, Doganavsargil B, Hekingil M, Semerci B. Streptozotocin-induced diabetic effects on spermatogenesis with proliferative cell nuclear antigen immunostaining of adult rat testis. *Fertil Steril.* 2003;5(50):20-5.
21. Ulmer CS, Bosworth HB, Germain A, ndquist J, Olsen M, Brancu M, et al. Associations between sleep difficulties and risk factors for cardiovascular disease in veterans and active duty military personnel of the Iraq and Afghanistan conflicts. *J Behav Med.* 2015;38(3):544-55.
22. Huang TH., HYang Q, Harada M, Li GQ, Yamahara J, Roufogalis BD, Li Y. Pomegranate flower extract diminishes cardiac fibrosis in Zucker diabetic fatty rats: modulation of cardiac endothelin-1 and nuclear factor-kappaB pathways. *J Cardiovascular Pharmacol.* 2015;46(6):856-62.