

The Effect Co2 Laser on Reducing Pain Associated with Aphthous Stomatitis

R.S. Rezvaninezhad (MSc)¹, N. Navabi (DDS,MS)*², Z. Atai (DDS,MS)², A. Shahravan (DDS,MS)²

1.Kerman Faculty of Dentistry, Kerman University of Medical Sciences, I.R.Iran

2.Social Determinants of Oral Health Research Center, Tehran University of Medical Sciences, I.R.Iran

J Babol Univ Med Sci; 18(10); Oct 2016; PP: 20-5

Received: May 9th 2016, Revised: Jun 1st 2016, Accepted: Jul 27th 2016.

ABSTRACT

BACKGROUND AND OBJECTIVE: Recurrent oral aphthous ulcers (Recurrent Aphthous Stomatitis = RAS) is a common mucosal lesions occur in 20% of the population and majority of the current treatments for recurrent aphthous stomatitis (ras) are aimed to minimizing pain. The aim of this study was to determine whether laser co2 has this analgesic effect.

METHODS: A randomized single blind trial was conducted in 43 patents with ras. The subjects were divided into 3 groups: namely, co2 laser group, group with conventional treatment and placebo group. The co2 laser device was operated 3 w power in continuous mode for 5-8 seconds. To measure the pain, VAS scale was used and patients were evaluated for pain and size of the ulcers within before treatment, and days of 1, 4, and 7.

FINDINGS: The average intensity of pain was 5.94 ± 2.41 , before the intervention and reached to 0.39 ± 1.28 on the seventh day. The pain reduction in co2 laser treatment group is more than the placebo group and conventional therapy group ($p=0.001$). The average size of the ulcers was 4.41 ± 2.21 mm before the intervention and decreased to 0.6 ± 1.19 on the seventh day, but there were no statistically significant differences in the size of ulcers between groups ($p>0.05$).

CONCLUSION: It seems that the use of laser CO2 has favorable results in reducing pain in patients with RAS.

KEY WORDS: *Aphthous, Pain Management, Laser Therapy.*

Please cite this article as follows:

Rezvaninezhad RS, Navabi N, Atai Z, Shahravan A. The Effect Co2 Laser on Reducing Pain Associated with Aphthous Stomatitis. J Babol Univ Med Sci. 2016;18(10):20-5.

*Corresponding author: N. Nabavi(DDS,MD)

Address: Research Center for Social Determinants of oral health, Kerman University of Medical Sciences, Crossroads healing, Kerman, I.R.Iran

Tel: +98 34 32118073

E-mail: N_navabi@kmu.ac.ir

Introduction

Recurrent oral aphthous ulcer (Recurrent Aphthous Stomatitis) (RAS) are most prevalent mucosal lesions occurs in 20% of the population (1, 2) and its pain in terms of recurrence make difficult daily activities of life such as eating, swallowing and speaking (3). The etiology of RAS is not yet definite known and there are no definite cure for the prevention of recurrence of these lesions (5, 4). Treatments were not 100% effective, and on the other hand sometimes have been associated with adverse events (17-6). The use of laser therapy to relieve pain in patients with RAS in recent decades has been of interest to researchers (21-18).

CO₂ lasers have excellent properties including minimal damage to surrounding tissue, reduced edema, helping to create a sterile environment and accelerate blood coagulation phenomenon (21). The active ingredient of CO₂ laser is gaseous carbon dioxide and its wavelength is nm10600. These wavelength is absorbed well in water, therefore on tissues with high water content is most effective and is absorbed a lot by all soft biological tissue (19).

Penetration Depth of CO₂ laser is low and they can be used to reduce oral mucosal lesions (19,18). Nowadays, few credible studies on the effects of CO₂ laser on the RAS lesions causes that they can not be definitively ruled on this field. The present study was conducted to examine the effect of CO₂ laser on pain relief in patients with recurrent aphthous stomatitis.

Methods

This single-blind randomized clinical trial study was done on patients referred to Oral disease unit, school of dentistry, Kerman after receiving permission from the ethics committee of Kerman University of Medical Sciences with registration number 1N2015091323992IRCT.

Patients with a history of RAS and the presence of a minor aphthous ulcers during study (aphthous ulcers smaller than one centimeter with a halo erythematous) were included and those aged less than 12 years or with a history of any known systemic disease, pregnancy and lactation, smoking or alcohol drinking, use of medication for two weeks before were excluded from the study (20). The sample size considering the pooled SD equivalent of 0.7 and clinical significance equivalent of 1 for changes in pain and 0.05 Type I error and 0.20 Type II error, 15 people in each group

and a total of 45 people was determined. All patients were enrolled in the study with written consent and awareness of the objectives and were empowered to leave it at every stage of research.

For this study, the clinical examination of the mouth was done by an oral diseases specialist in light unit and using disposable equipment and clinical characteristics of wounds were recorded in the form. Patients randomly (draw tab) were divided in three groups: Group 1 corticosteroid therapy, corticosteroid therapy and CO₂ laser therapy in Group 2 and Group 3 corticosteroid therapy and laser placebo. Corticosteroid therapy included the use of a half-mg tablets of betamethasone (Iran, Abu Rayhan) dissolved in 30 cc of water and four times a day was placed on the wound using sterile gauze.

Treatment with CO₂ laser was done by a resident of the oral diseases with a wavelength of 10600 nm and 3W with 7-5 mm distance from mucosa and continuous mode for 8-5 seconds at a time, (SLI laser device made in Italy). Passive laser was used as a placebo. For laser treatment, lidocaine 10% was used for local anesthesia (20). The patient and dentist used protective glasses during laser treatment. To measure the amount of pain experienced after surgery in patients, Visual Analogue Scale was used. leaves were delivered to the patient with four graduated line and a length of 100 mm with symbols at both ends: (two multiplication sign) characterizing the state (painless) and (worst possible pain), and patients were asked to determine their pain levels on these specified lines before the laser therapy and the first, fourth and seventh days after laser therapy in the early hours of the day.

The severity of the pain was read using this mark and standard ruler and was recorded. In addition, the size of wound was measured using a Williams probe one day before laser therapy and and the first, fourth and seventh days after laser therapy (21). General Linear Model analysis and repeated measurement was used to evaluate the severity of pain and ulcer size as well as the Generalized Estimated Equation (GEE) analysis was done to assess clinical improvement and $p < 0.05$ was considered significant.

Results

After leaving two patients during the study, 43 patients were evaluated in three groups including conventional therapy group (n=14), placebo group

(n=14) and CO2 laser therapy group (15 patients). The average age of the participants was 30.88 ± 10.92 with the range of 17-63 years and 53.5% of participants were men. Reduction of the wounds size in all patients during the four periods showed that the average size of the wounds decreased from 4.41 ± 2.21 mm, before the intervention to 0.6 ± 1.19 in the seventh day and there was no significant difference between three groups of patients (placebo, conventional treatment group ($p=0.83$, $OR=0.91$) and the group treated with laser CO2 ($p=1.09$, $OR=0.82$) (Fig 1). Reduction of pain in patients of three groups during four time periods showed that the mean VAS from 5.94 ± 2.41 before the intervention decreased to the 0.39 ± 1.28 on the seventh day and there was a significant relationship among the three groups of patients (Fig 2). In other words, pain reduction in CO2 laser treatment group was more compared to the placebo laser treatment group ($p=0.001$).

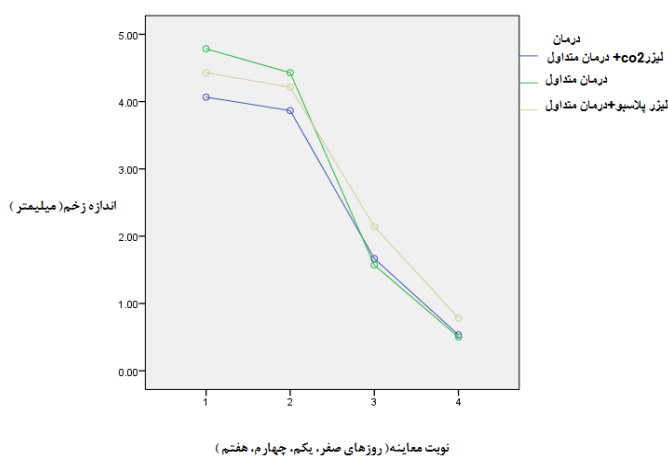


Figure 1. Comparison of aphthous ulcer size changes among the three groups in the 4th period.

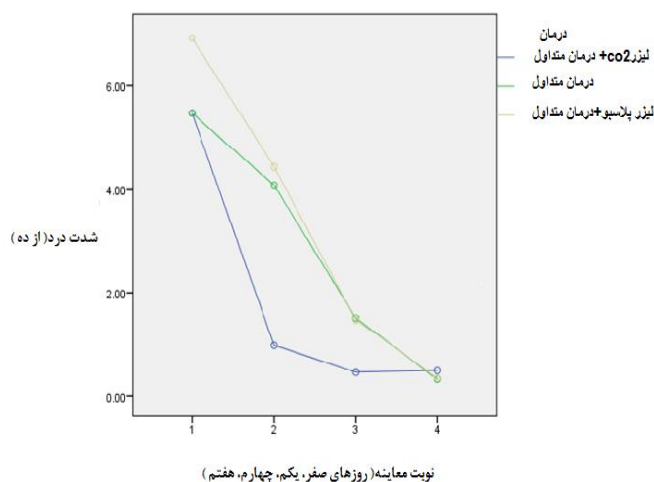


Figure 2. Comparison of changes in the intensity of pain in patients with RAS in the 4th period

Discussion

The results of this study confirmed the significant pain reduction in patients with RAS as a result of CO2 laser use compared with conventional therapy. Several studies have examined the effect of laser therapy on oral aphthous ulcers also used other types of lasers. The difference in type of used lasers is in the mechanism of action on biological tissues, portable and availability of laser, laser protocol properties (strength, dosage, wavelength, and time of examination after laser and follow-up of patients).

In this study, reduction of pain in patients with recurrent oral aphthous ulcers was observed immediately after laser therapy on the days 1, 4 and 7 in all patients. Sattayut and colleagues were measured the severity of the pain after laser therapy and on the days 1, 3, 5 and 7. Parasad and colleagues evaluated the pain immediately and 24 hours after doing laser treatment.

Zand and colleagues assessed the pain immediately after laser therapy and at 4,8,12,24,48,72 intervals and 96 hours later. The interval of pain assessment in the study of Colvard and colleagues was similar to our study (25-22). In this study, there was no significant difference in ulcer size change following the treatment on days 5, 3, 1 and 7 between three treatment groups. The study of Sattayut and colleagues is the only study similar to our study that examined the effect of laser therapy on the size of recurrent aphthous ulcer on days 3,1 and 5 and similar to results of present study no significant differences was observed (22).

As can be seen there is no consensus among researchers in the hourly intervals to assess the effects of laser irradiation, such as choosing the type of laser. In addition, mechanisms through which the laser can relief pain of patients was also not mentioned and only plausible mechanisms such as destruction of nerve endings, blocking the action potential, reducing painful compounds such as histamine and bradykinin and also increase the availability of oxygen to hypoxic cells have been mentioned in this regard (24).

Pavlic and colleagues in their systematic review reported that despite the fact that research in this area shows the benefits of laser application in symptomatic treatment of RAS, these findings should be interpreted with caution and factors such as study design and the type of laser used to be considered (21). Researchers reported a significant differences for an index as clinical improvement in the use of CO2 laser which is incompatible with the results of the present study (26,

25, 23). The essential issue in RAS therapy is to estimate which strategy of successful treatment should be selected among the criteria for the patients and clinical criteria.

The results of the study indicate the effects of laser therapy in changing the criteria related to the patient (or the same VAS) compared with its impact on clinical criteria (clinical improvement which considered as changes in ulcer size, recovery time and erythematous halo) is more pronounced which is incompatible with the results of several studies and in the results of investigations is more emphasis on clinical criteria of improved RAS in the use of laser (26, 25, 23). In all above-mentioned studies, pain measurement scale was VAS similar to the present

study, whereas in the study of Colvard et al, scale for pain assessment have not been declared. In addition, in the study of Zand and colleagues, pain assessment was not performed in recurrent aphthous ulcer (26, 25) which may be due to difficult understand of patients on the use of VAS. Based on the results of this study, it appears that the use of complementary therapy of CO2 laser have favorable clinical results in reducing pain in patients with recurrent oral aphthous ulcers.

Acknowledgments

Hereby, we would like to thank Vice Chancellor for Research and Technology of Kerman University of Medical Sciences for financial support of this research.

References

- 1.Scully C, Porter S. Oral mucosal disease: recurrent aphthous stomatitis. *Br J Oral Maxillofac Surg*. 2008;46(3): 198-206.
- 2.Ślebioda Z, Szponar E, Kowalska A. Recurrent aphthous stomatitis: genetic aspects of etiology. *Postep Derm Alergol*. 2013; 30(2): 96–102.
- 3.Vucicevic Boras V, Savage NW. Recurrent aphthous ulcerative disease: presentation and management. *Aust Dent J*. 2007;52(1):10-5; quiz 73.
- 4.Natah SS, Kontinen YT, Enattah NS, Ashammakhi N, Sharkey KA, Häyrynen-Immonen R. Recurrent aphthous ulcers today: a review of the growing knowledge. *Int J Oral Maxillofac Surg*. 2004;33(3):221-34.
- 5.Farhad-Mollashahi L, Pouramir M, Motalebnejad M, Honarmand M, Bijani A, Shirzad A. Comparison of salivary total antioxidant capacity and lipid peroxidation in patients with recurrent aphthous stomatitis and healthy persons. *J Babol Univ Med Sci*. 2013; 15(5):39-44. [In Persian]
- 6.Toche P, Salinas L, Guzmán MM, Afani S, Jadue A. Recurrent oral ulcer: clinical characteristic and differential diagnosis. *Rev Chilena Infectol*. 2007;24(3):215-9.
- 7.Scully C, Gorsky M, Lozada-Nur F. The diagnosis and management of recurrent aphthous stomatitis: a consensus approach. *J Am Dent Assoc*. 2003;134(2):200-7.
- 8.Navabi N, Zarei M, Falsafi F, Sadeghi B. Assessment the role of hematologic agent deficiencies in the etiology of recurrent aphthous stomatitis. *J Babol Univ Med Sci*. 2013;15(3):88-95. [In Persian]
- 9.Quijano D, Rodríguez M. Topical corticosteroids in recurrent aphthous stomatitis. Systematic review. *Acta Otorrinolaringol Esp*. 2008;59(6):298-307.
- 10.Shashy RG, Ridley MB. Aphthous ulcers: a difficult clinical entity. *Am J Otolaryngol*. 2000;21(6):389-93.
- 11.Stoopler E, Sollectio T. Recurrent aphthous stomatitis. Update for the general practitioner. *N Y State Dent J*. 2003; 69(2):27-9.
- 12.Hello M, Barbarot S, Bastuji-Garin S, Revuz J, Chosidow O. Use of thalidomide for severe recurrent aphthous stomatitis: a multicenter cohort analysis. *Medicine (Baltimore)*. 2010;89(3):176-82.
- 13.Barrons RW. Treatment strategies for recurrent oral aphthous ulcers. *Am J Health Sys Pharm*. 2001;58(1):41-53.
- 14.Rhee SH, Kim YB, Lee ES. Comparison of Behcet's disease and recurrent aphthous ulcer according to characteristics of gastrointestinal symptoms. *J Korean Med Sci*. 2005;20(6):971-6.
- 15.Gavanji S, Larki B, Doostmohammadi M, Mortezaeinezhad F. Production of a new mixed herbal medicine for minor Aphthous Ulcers. *J Med Plant*. 2012;4(1):49-51.
- 16.McBride DR. Management of aphthous ulcers. *Am Fam Physician*. 2000;62(1):149-54.
- 17.Motalebnejad M, Moghadamnia A, Mohammadi E. The effect of bioadhesive in reduction of pain and healing time of Aphtha. *J Babol Univ Med Sci*. 2003;5(1):12-6.[In Persian]
- 18.Nammour S. Chronology of the use of the laser beam in dentistry, and the state of postgraduate university education programs in this domain. *Photomed Laser Surg*. 2016 Jan;34(1):1-2.
- 19.Kotlow L. Lasers and soft tissue treatments for the pediatric dental patient. *Alpha Omegan*. 2008.101(3):140-51.
- 20.De Souza TO, Martins MA, Bussadori SK, Fernandes KP, Tanji EY, Mesquita-Ferrari RA, et al. Clinical evaluation of low-level laser treatment for recurring aphthous stomatitis. *Photomed Laser Surg*. 2010;28 Suppl 2:S85-8.
- 21.Pavlic V, vujic-Aleksic V, Aoki A, Nezc L. Treatment of recurrent aphthous stomatitis by laser therapy: A systematic review of the literature. *Vojnosanit Pregl*. 2015;72(8):722-8.
- 22.Sattayut S, Trivibulwanich J, Pipithirunkarn N, Danvirutai N. A clinical efficacy of using CO2 laser irradiating to transparent gel on aphthous stomatitis patients. *Laser Ther*. 2013;22(4):283-9.
- 23.Prasad RS, Pai A. Assessment of immediate pain relief with laser treatment in recurrent aphthous stomatitis. *Oral Surg Oral Med Oral Pathol Oral Radiol*. 2013;116(2):189-93.

24. Zand N, Ataie-Fashtami L, Djavid GE, Fateh M, Alinaghizadeh MR, Fatemi SM, et al. Relieving pain in minor aphthous stomatitis by a single session of non-thermal carbon dioxide laser irradiation. *Lasers Med Sci.* 2009; 24(4):515-20.
25. Colvard M, Kuo P. Managing aphthous ulcers: laser treatment applied. *J Am Dent Assoc.* 1991;122(6):51-3.
26. Zand N, Fateh M, Ataie-Fashtami L, Djavid GE, Fatemi SM, Shirkavand A. Promoting wound healing in minor recurrent aphthous stomatitis by non-thermal, non-ablative CO(2) laser therapy: a pilot study. *Photomed Laser Surg.* 2012;30(12):719-23.