

The Effect of Concurrent Administration of Metoclopramide, Bromocriptine and Cumin Essential Oils on Rat Ovary

F. Abbasi Hormozi (DVM)¹, H. Najafzade Varzi (PhD)^{*2}, B. Mohammadian (PhD)³, S.R. Fatemi Tabatabae(PhD)²

1.Faculty of Veterinary Medicine, Shahid Chamran University of Ahvaz, Ahvaz, I.R.Iran

2.Department of Basic Sciences, Faculty of Veterinary Medicine, Shahid Chamran University of Ahvaz, Ahvaz, I.R.Iran

3.Department of Pathology, Faculty of Veterinary Medicine, Shahid Chamran University of Ahvaz, Ahvaz, I.R.Iran

J Babol Univ Med Sci; 18(7); Jul 2016; PP: 55-61

Received: Jan 25th 2016, Revised: Apr 18th 2016, Accepted: Jun 1st 2016

ABSTRACT

BACKGROUND AND OBJECTIVE: Due to the use of medicinal plants in the treatment of endocrine diseases, including ovarian cyst and on the other hand, according to the estrogenic properties of cumin, the aim of this study was to evaluate the effect of cumin oil on histopathological changes in the rat ovary, in the presence or absence of dopaminergic agonists and antagonists.

METHODS: In this experimental animal models study, 35 female rats were divided into 7 groups, they received, saline, metoclopramide (90 mg/kg intraperitoneal), bromocriptine (4mg/kg subcutaneous), metoclopramide, bromocriptine, metoclopramide, cumin (4mg/kg oral), cumin, bromocriptine, cumin, for 10 days, respectively and then sacrificed by chloroform, then ovaries were removed and the number of ovarian cysts, follicular atresia and mature follicles were studied by histopathological methods.

FINDINGS: Metoclopramide significantly increased, the number of follicle atresia (1.4 ± 0.254) and the number of follicular cysts (2 ± 0) in four field microscopy ($p \leq 0.002$). Bromocriptine increased significantly, the number of mature follicles (1.4 ± 0.254). Cumin increased, the number of follicle atresia (0.5 ± 0.289) and follicular cysts but prevented the effect of metoclopramide in increasing the number of follicular cysts.

CONCLUSION: The results of this study showed that cumin can prevent ovarian cysts by dopaminergic antagonists. While in the presence of dopaminergic agonis has cyst-forming effect.

KEY WORDS: *Metoclopramide, Bromocriptine, Cumin, Histopathology, Ovary, Rat.*

Please cite this article as follows:

Abbasi Hormozi F, Najafzade Varzi H, Mohammadian B, Fatemi Tabatabae SR. The Effect of Concurrent Administration of Metoclopramide, Bromocriptine and Cumin Essential Oils on Rat Ovary. J Babol Univ Med Sci. 2016;18(7):55-61.

*Corresponding author: H. Najafzade Varzi (PhD)

Address: Department of Basic Sciences, Faculty of Veterinary Medicine, Shahid Chamran University of Ahvaz, Ahvaz, I.R.Iran.

Tel: +98 61 33330073

Email: najafzadeh@scu.ac.ir

Introduction

Since the cumin is one of the almost full consumption stuffing food in our country and it is used as a herbal supplement in the treatment of obesity and weight loss, understanding its mechanisms of action in formation of pharmacological effects and side effects and toxicity appears to be important, considering that adequate and comprehensive studies in this field is not available. In particular estrogenic properties of cumin is listed in references and in experimental studies in animal models anti-fertility effects in males have been reported. So Shariati and et al reported that alcoholic extract of cumin causes weakening of testicular function and reduction of testosterone and spermatogenesis (1).

Saxena and et al stated that cumin can be regarded as an anti-fertility in males (2). Gupta and et al stated that cumin inhibits spermatogenesis and fertility without occurring apparent toxic effects (3). On the other hand the study on the impact of cumin on reproductive performance in females is not available. Given the estrogenic effects of cumin and infertility effects in male, this study was designed to investigate firstly, the effect of cumin on ovarian tissue from pathological's view and secondly, in pursuit of its mechanism of action via dopaminergic system, ovarian tissue changes will be assessed in concomitant use with a dopaminergic agonist (bromocriptine) and a dopaminergic antagonist.

The dopaminergic system was chosen because, dopamine is known physiological inhibitor of prolactin secretion and binds to D2 mammatropes receptors of pituitary that finally causes reduction of produce and secretion of prolactin (4, 5). Increase in blood prolactin may be involved in the development of ovarian cysts and in most cases the treatment of hyperprolactinemia is performed with the use of dopaminergic agonist (6). Dopamine or Dopaminergic agonists not only is effective in reducing ovarian tumors, but also can inhibits the tumor-causing agents, such as protein kinases in ovary and decreases the tumor angiogenesis (7). Bromocriptine is dopaminergic agonist (D2 agonist) that is used in the treatment of galactorrhoea consequent hyperprolactinemia (8, 9). Metoclopramide is Dopaminergic D2 receptor antagonist and studies showed that in laboratory animals such as rats leads to an increase in blood prolactin (10). Cumin with the scientific name of *Cuminum, cyminum* is a grassy, annual plant that its leaf is dark green and it grows in different countries, including Iran, especially in

Khorasan, Isfahan and Kerman. Cumin has tannins, oils, resins and essential oils. Cuminaldehyde is the main and the most common compound in cumin that forms Up to 63 percent of the total oil. Cumin usage has different effects, such as it is used in the treatment of obesity. In addition, this drug is used in combination of increased milk production, to increase milk production in postpartum women (11).

Cumin essential oils has antibacterial, anti-obesity and anti-oxidant properties (12). In addition, laboratory animals' studies have shown that cumin has anti glycaemic activity and can reduce the complications of diabetes (13). In clinical studies it was shown that cumin in the prevention of digestive discomforts after emergent cesarean sections is the same and even more effective than milk of magnesia (14).

Cumin has antimicrobial properties So that cumin has a good inhibitory effect and fungicidal against *Aspergillus fumigatus* and *Aspergillus parasiticus* (15). According to the estrogenic properties of cumin, the aim of this study is to investigate the effect of cumin oil on the rat ovary histopathological changes in the presence and absence of dopaminergic agonists (bromocriptine) and dopaminergic antagonist (metoclopramide) to identify its more effect.

Methods

In this experimental animal models study, 35 mature female Wistar rats, Weight range of 200 ± 20 g (5rats in each group), was used. These rats were divided into 7 groups and they received respectively saline (control group), metoclopramide 90 mg/kg intraperitoneally for 10 days (10), bromocriptine 4mg/kg subcutaneously for 10 days (2), first metoclopramide for 10 days then bromocriptine for 10 days, first metoclopramide and then cumin essential oils 4mg/kg oral for 10 days (16, 17), cumin essential oils for 10 days, and the last group cumin essential oils and bromocriptine concomitantly, for 10 days. In the day 11, after receiving drugs, the rats were sacrificed and their ovary were removed. The ovaries were fixed by formalin buffer (10%). Then the tissue sections were prepared with the conventional method and they were stained with hematoxylin and eosin for pathological studies. The samples were analyzed by using optical microscopy and the number of mature follicles, Atresia and ovarian cysts were counted in four Microscopic field. The results of the experimental groups in terms of SPSS statistical software and

ANOVA and LSD test was examined and $p \leq 0.05$ was considered significant.

Results

In microscopic examination in the first to seventh group respectively 0.75 ± 0.25 , 0.8 ± 0.2 , 1.4 ± 0.245 , 0.6 ± 0.245 , 1 ± 0.258 , 0.25 ± 0.25 and 0.2 ± 0.2 number of mature follicles were counted. The number of follicles were counted in the third group (bromocriptine alone) than the control group (bromocriptine, metoclopramide) with $p=0.024$, sixth (cumin) with $p=0.003$ and seventh (cumin, bromocriptine) with $p=0.001$ was statistically significant. Also fifth group (cumin, metoclopramide) with the sixth group with $p=0.034$ and seventh group with $p=0.019$ was statistically significant. Metoclopramide significantly increased the number of follicles atresia while the control group and the third group (bromocriptine alone) and the fourth group (Bromocriptine, metoclopramide) no follicle atresia in 4 microscopic fields of each slide was observed (Fig1). In the second group (metoclopramide alone) the number of follicle atresia was 1.4 ± 0.254 , which was statistically significant in all groups ($p \leq 0.002$).

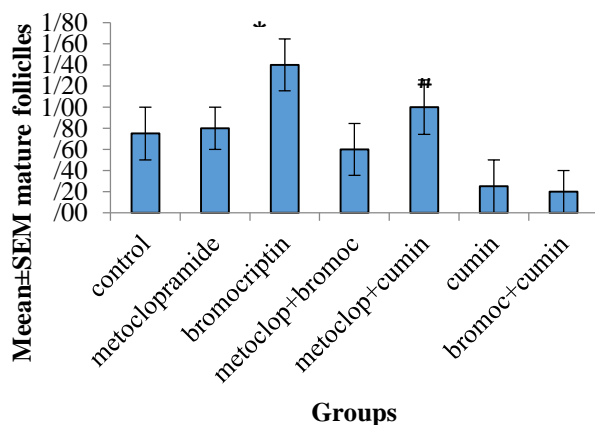


Figure 1. Compares the mean number of mature follicles in different groups

*Represents the significant difference between groups 3 and Group 4, 6 and 7 is ($p \leq 0.024$), #Represents the significant difference between groups 6 and 7 ($p \leq 0.034$).

In the fifth group (metoclopramide cumin) the number of follicle atresia was 0.33 ± 0.211 which was statistically significant just with second group. Also the mean number of follicle atresia in the sixth group (cumin) and seventh (cumin bromocriptine), respectively were 0.5 ± 0.289 and 0.2 ± 0.2 which were

statistically significant with metoclopramide received group (Fig 2).

No follicular cysts were observed in the control group (saline), third group (bromocriptine alone) and forth group (metoclopramide bromocriptine), while the largest number of follicular cysts were in the group that received metoclopramide with an mean number 0.2, that this mean in comparison to other groups was statistically significant ($p \leq 0.0001$). The mean number of cysts in the fifth group (metoclopramide cumin) was 1.33 ± 0.211 , that this mean was statistically significant with other groups ($p \leq 0.0001$). The mean of counted cysts in the receiving cumin group was 0.25 ± 0.25 and the mean of cysts in seventh group (cumin and bromocriptine) was 0.6 ± 0.254 that was statistically significant with all other groups except the cumin receiving group (Fig 3)

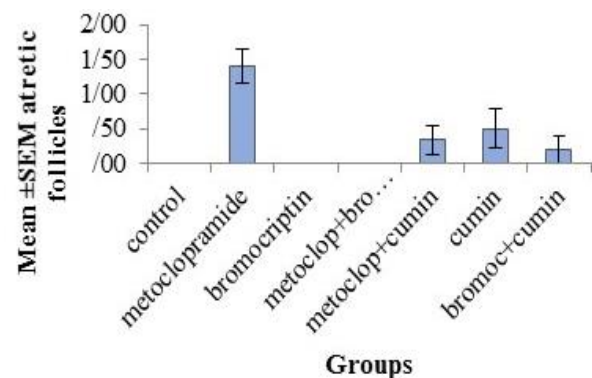


Figure 2. Compares the mean number of follicles atresia in different groups

* Represents a significant difference between the groups receiving metoclopramide with other groups ($p \leq 0.002$).

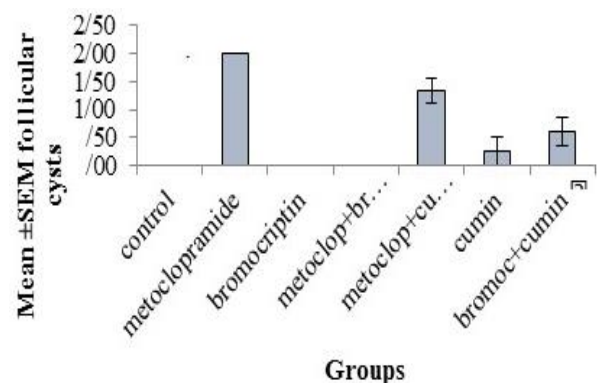


Figure3. Compare the mean number of follicular cysts in different groups

*Represents the difference between second groups and other groups ($p \leq 0.004$). #represents the difference between fifth groups and other groups ($p \leq 0.002$). β Represents the difference between seventh groups and other groups ($p \leq 0.016$).

In the microscopic examination of the ovaries of control group, natural structures was observed (Fig 4) mature follicle and a view of the primary follicle is well understood. The second group cyst and follicle atresia was observed (Fig 5). In the third group (bromocriptine alone) a large number of mature follicles and primary follicle was observed (Fig 6) but follicle atresia, or follicular cysts were not observed. In microscopic examination of the ovaries of forth group (metoclopramide bromocriptine) cyst and follicle atresia were not found and microscopic view of the ovaries appeared normal and some mature follicles were observed.

In the group receiving cumin metoclopramide (fifth group) in addition to the mature follicle, a considerable number of the follicle atresia and follicular cysts were observed (Fig 7). In cumin alone receiving group and also in cumin with bromocriptine receiving group, in addition to viewing mature follicles, follicle atresia and follicular cysts were observed.

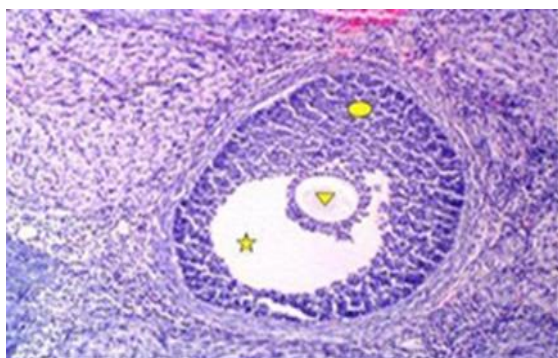


Figure 4. Structure of a mature follicle - Antrum space (star) ovule (triangle) and granulosa cells (circle). Staining (hematoxylin and eosin $\times 20$) in the control group.

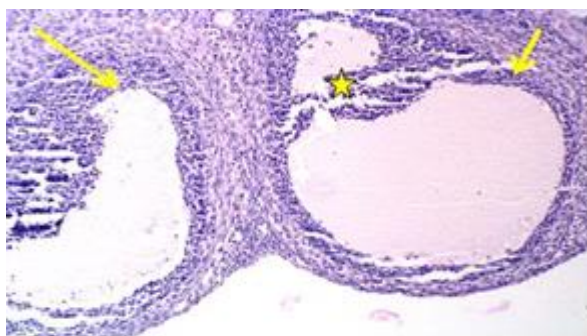


Figure 5. Structure of the cyst (arrow). In this image Granulosa cell degeneration (star) can be seen (hematoxylin staining eosin $\times 10$) in the group receiving metoclopramide.

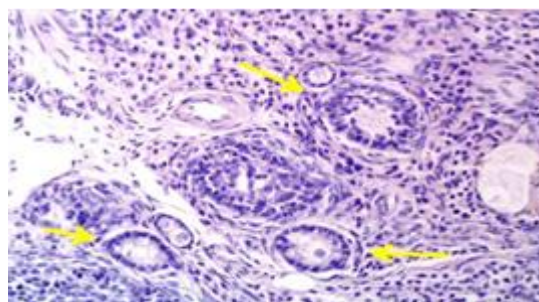


Figure 6. The structure of primary follicles (arrows). Existence simple cubic one layer epithelial tissue (hematoxylin, eosin $\times 20$) in the group receiving bromocriptine.

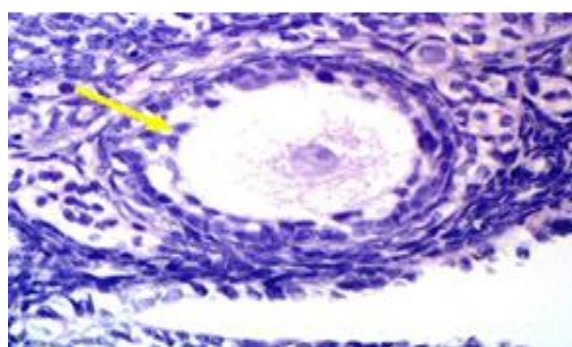


Figure 7. Structure of follicle atresia. In this image granulosa cells started to become picnotic (arrow), (hematoxylin staining eosin $\times 40$) in cumin receiving groups.

Discussion

In the present study it was observed that the use of metoclopramide, increased significantly the number of follicle atresia and the number of follicular cysts compared to the control group. Metoclopramide as a dopamine antagonist binds to different dopaminergic receptors such as D2 and inhibits the effect of dopamine. It appears that metoclopramide with changing in Hypothalamic-pituitary-ovarian, changes the function of ovarian cells. In the study, Li and et all stated that Metoclopramide consumption increased prolactin and decreases estrogen, progesterone, LH and FSH in rats. Metoclopramide can create the cyst by increasing in prolactin.

Sulpiride (dopaminergic antagonists) causes hyperprolactinemia by changing in Reproductive hormones, including prolactin, estrogen, LH and FSH (19). In this study, bromocriptine alone increased the mature follicles compared to other groups and even it was more than control group. While atresia follicles and follicular cysts were not observed in this group.

Since bromocriptine is a dopaminergic receptor agonist, reduces the secretion of prolactin like dopamine, and antagonized the effects of the prolactin in ovarian cysts. Bromocriptine maintained in female rats in the range of the control group but coped with the effect of metoclopramide which is increasing prolactin (18).

Bromocriptine alone or in combination with glipizide can treat hyperglycemia that this property can reduce endocrine disorders, including follicular cysts in obese or diabetic (20). The prevalence and severity of ovarian hyperactivity syndrome in humans are significantly reduced with the administration of bromocriptine (21). In patients with idiopathic galactorrhea taking bromocriptine can return Prolactin levels to normal levels and are useful in the treatment of this complication (22).

Hamid and colleagues demonstrated that bromocriptine effects on plasma levels of prolactin in male rats, causing changes in reproductive parameters in rats (23). Also dopaminergic agonist, and bromocriptine can prevent hyperprolactinemia in transgenic rats (24). In this study, administration of cumin alone increased significantly follicle atresia compared to control group. While concomitant use of metoclopramide with cumin could significantly reduce the effect of metoclopramide in follicle atresia. The effect of cumin in follicular cysts were similar to change follicle atresia. So that the consumption of cumin alone the number of follicular cysts was observed. Cumin could reduce significantly the drastic effect of metoclopramide on follicular cysts. The bromocriptine could not significantly influence the effects of cumin on the number of mature follicles, follicle atresia and follicular cyst. In the study it was shown that cumin has no effect on mice weight but

changes in spermatogenesis, including a significant reduction in the number of spermatids and primary and secondary spermatocytes.

Also the number of mature Leyding cells and Sertoli cells and testosterone levels decreased and infertility were caused by changes in sperm motility, concentration and morphology (2). In a similar study Gupta and et all observed that The methanol extract has no effect on weight of male rats but significantly reduced weight of testicles, epididymis and seminal vesicles and ventral prostate and fertility decline was about 70%. In addition, levels of sex hormones and testis cell numbers decreased (3). It seems that cumin estrogenic properties and possibly by increasing prolactin affects the reproductive system. Especially by causing ovarian cysts, reduces the fertility rate that probably acts through dopaminergic receptors or strengthen the action of dopamine. Similar effects have been reported with some other plants so that Wang and et al reported that that aqueous extract of *Fructus hordei* germinates has anti- hyperprolactinemia effect that these effects act through dopamine receptors (10). The study showed that cumin can prevent ovarian cysts by dopaminergic antagonists While in the presence of dopaminergic agonist, causes cyst formation Although further studies on the measurement of prolactin, estrogen, progesterone, LH and FSH are needed to state more precise about the mechanism of cumin effects on changing ovarian tissue.

Acknowledgments

Hereby, we would like to thank the Deputy of research and technology of Shahid Chamran University of Ahvaz for financial support of this research.

References

- 1.Shariaty M., Mokhtary M., Shahidian SH. Effect of alcoholic extract of Cuminum cyminum on testosterone and its anti infertility in adult male wistar rats. J Med Sci Zanzan University.2005; 13(50):8-13. [persian]
- 2.Saxena P., Gupta R., Gupta RS. Contraceptive studies of isolated fraction of cuminum cyminum in male albino rats. Nat Prod Res. 2015; 29(24):2328-31.
- 3.Gupta RS. Saxena P., Gupta R., Kachhawa JB. Evaluation of reversible contraceptive of Cuminum Cyminum in male albino rats. Contraception. 2011;84(1):98-107
- 4.Asa SL., Kelly MA., Grandy DK., Low ML. Pituitary lactotroph adenomas develop after prolonged lactotroph hyperplasia in dopamine D2 receptor-deficient mice. Endocrin; 1999; 140(11):5348–5355
- 5.Ben-Jonathan N., Hnasko R. Dopamine as a prolactin (PRL) inhibitor. Endocr Rev. 2001;22(6):724-63.
- 6.Sarkar DK., Chaturvedi K., Oomizu S , Boyadjieva NI., Chen CP. Dopamine, dopamine D2 receptor short isoform, transforming growth factor (TGF)- β 1, and TGF- β Type II receptor interact to inhibit the growth of pituitary lactotropes. Endocrin. 2005;. 146(10): 4179–4188.
- 7.Moreno-Smith M., Lee SJ., Lu C., Nagaraja AS ., He G., Rupaimoole R., et al. Biologic Effects of dopamine on tumor vasculature in ovarian carcinoma. Neoplasia. 2013;15(5): 502–510
- 8.Webster J., Piscitelli G., Polli A., Ferrari CI., Ismail I., Scanlon MF. A comparison of cabergoline and bromocriptine in the treatment of hyperprolactinemic amenorrhea. New England J Med. 1994;. 331(14):904–909
- 9.Doknic M., Pekic S., Zarkovic M., Medic-Stojanoska M., Dieguez C., Casanueva F., Popovic V. Dopaminergic tone and obesity: an insight from prolactinomas treated with bromocriptine. Eur J Endocrinol. 2002; 147(1):77-84
- 10.Wang X., Ma L., Zhang E., Zou JI., Guo H., Peng SW., Wu J. Water extract of fructus Hordei germinatus shows antihyperprolactinemia activity via dopamine D2 receptor. Evid Based Complement Alternat Med. 2014;. 2014: 579054
- 11.Shahraz S., Ghaziani T., Ansari Sh. A comprehensive textbook of drug information, 3th Ed, published by teimurzade. 2002; pp:771-772. [persian]
- 12.Hajlaoui H., Mighri H., Noumi E., Snoussi M., Trabelsi N., Ksouri R., Bakhrouf A. Chemical composition and biological activities of Tunisian Cuminum cyminum L. essential oil: A high effectiveness against Vibrio spp. strains. Food Chem Toxicol, 2010;48(8-9):2186-92
- 13.Jagtap AG., Patil PB. Antihyperglycemic activity and inhibition of advanced glycation end product formation by Cuminum cyminum in streptozotocin induced diabetic rats. Food Chem Toxicol. 2010; 48(8-9):2030-6.
- 14.Sakhavar N, Mirteimoori M. Comparison of cuminum cyminum with milk of magnesia in prevention of gastrointestinal discomforts after. JBUMS. 2009; 10 (6) :42-48
- 15.Minooeian Haghighi M, Khosravi A. inhibition and destruction effects of Cuminum cyminum, Ziziphora clinopodioides and Cigella sativa essences on Aspergillus cells. JBUMS. 2013; 15 (6) :25-35
- 16.Mohiti- Ardekani J., Akbarian Z., Nazarian A. Effects of Cumin (Cuminum cyminum) oil on serum glucose and lipid levels of rats. J Shahid Sadoughi Univ Med Sci;2012 19(3): 387-97.[persian]
- 17.Dhandapani S., Subramanian VR., Rajagopal S., Namasivayam N. Hypolipidemic effect of Cuminum cyminum L. on alloxan-induced diabetic rats. Pharmacol Res. 2002;. 46(3):251-5
- 18.Li Mx., Liu H., Li Y.,Wang F., Zhang p., Zang P. Anti-hyperprolactinemic effect of formula malt decoction, a Chinese herbal cocktail. Trop J Pharm Res, 2015; 14 (2): 263-269
- 19.Mostafapour S., Zare S., Sadrkhanlou RA., Ahmadi A., Razi M. Sulpiride-induced hyperprolactinemia in mature female rats: evidence for alterations in the reproductive system, pituitary and ovarian hormones. Int J Fertil Steril. 2014; 8(2):193-206.

- 20.Kumar VSH., M B V., AN P., Aithal S., Baleed SR., Patil UN. Bromocriptine, a dopamine (D2) receptor agonist, used alone and in combination with glipizide in sub-therapeutic doses to ameliorate hyperglycaemia. J Clin Diagn Res. 2013;7(9):1904-7.
- 21.Sherwal V., Malik S., Bhatia V. Effect of bromocriptine on the severity of ovarian hyperstimulation syndrome and outcome in high responders undergoing assisted reproduction. J Hum Reprod Sci. 2010;3(2):85-90.
- 22.Barooti S., Blash F., Mahmdy M., Valayi N. Comparison effect of gabergolin and bromocriptne on iodipatic threatment for 12 weeks. J Shahid Beheshti Med Sci University 2006(52). 241-251[persian]
- 23.Hamid Q., Hamid S., Minhas LA., Gul A. Influence of cimetidine and bromocriptine on prolactin levels in rat fertility. Int J Physiol Pathophysiol Pharmacol. 2009;1(1):33-40
- 24.Ratner LD., Gonzalez B., Ahtiainen P., Di Giorgio NP., Poutanen M., Calandra RS., Huhtaniemi IT., Rulli SB. Short-term pharmacological suppression of the hyperprolactinemia of infertile hCG-overproducing female mice persistently restores their fertility. Endocrin. 2012;153(12):5980-92.