

## An Evaluation of the Effects of *Cucurbita moschata* on Cerebrovascular Accident and Neurological Disorders in an Animal Model of Rats

E. Shiri (MSc)<sup>1</sup>, M. Rahnema (PhD)<sup>\*1</sup>, M.R. Bigdeli (PhD)<sup>2</sup>

1.Department of Physiology, Pardis Research and Sciences, Zanjan Branch, Islamic Azad University, Zanjan, I.R.Iran

2.Department of Physiology, Faculty of Biological Sciences, Shahid Beheshti University of Medical Sciences, Tehran, I.R.Iran

Received: Apr 19<sup>th</sup> 2015, Revised: Jul 29<sup>th</sup> 2015, Accepted: Sep 28<sup>th</sup> 2015

### ABSTRACT

**BACKGROUND AND OBJECTIVE:** Cerebral ischemia is a common cause of mortality, which can be described as a focal brain defect secondary to trauma. This study aimed to determine the relationship between consumption of *Cucurbita moschata* seed oil and stroke volume, as well as the neurological disorders in a cerebrovascular model of rats.

**METHODS:** In this empirical study, 28 mature male Wistar rats weighing between 250 and 350 gr were divided into four groups. The control group was gavaged with distilled water, and the other three groups received 0.25, 0.50, and 0.75 ml/kg *Cucurbita moschata* seed oil orally for 30 days. At the end of the thirty-day period, the animals underwent middle cerebral artery occlusion in order to induce stroke. Twenty-four hours after reperfusion, lesion volume and neurological disorders were evaluated.

**FINDINGS:** It was found that 0.50 and 0.75 ml/kg doses of *Cucurbita moschata* seed oil reduced neurological disorders ( $p<0.021$  and  $p<0.000$ , respectively). In addition, stroke volume decreased in the cortical area at doses 0.50 ( $55.02\pm7.6$ ) and 0.75 ( $30.05\pm9.06$ ) ml/kg, as compared to the control group ( $133.02\pm9.11$ ;  $p<0.000$  and  $p<0.000$ ).

**CONCLUSION:** Consumption of *Cucurbita moschata* seed oil can reduce symptoms of ischemic stroke.

**KEY WORDS:** Cerebral Ischemia, Neurological Disorders, *Cucurbita moschata* Seed Oil.

### Please cite this article as follows:

Shiri E, Rahnema M, Bigdeli MR. An Evaluation of the Effects of *Cucurbita moschata* on Cerebrovascular Accident and Neurological Disorders in an Animal Model of Rats. J Babol Univ Med Sci. 2015;17(12):19-25.

\*Corresponding Author: M. Rahnema (PhD)

Address: Department of Physiology, Biology Research Center, Zanjan Branch, Islamic Azad University, Zanjan, I.R.Iran

Tel: +98 24 33421001-7

E-mail: meh\_rahnema@yahoo.com

## Introduction

Cerebrovascular accident (CVA) is one of the main causes of mortality (1), and its annual treatment cost is estimated at 70 billion dollars in the United States (2). Moreover, 20-60% of survivors present with long-term neurophysiological symptoms such as mental retardation, paralysis, and behavioral disorders (3). There are various risk factors for CVA including age, gender, hypercholesterolemia, smoking, alcoholism, past history of cardiovascular diseases (especially atrial fibrillation), diabetes mellitus, and taking oral contraceptives or some particular therapeutics (4). Approximately 70-80% of deaths caused by CVA are secondary to ischemic brain lesions (5). Despite technological advancements and the importance of CVA, an effective clinical treatment for this disease has not been achieved yet. Therefore, use of neuroprotective agents for protecting the body against CVA has attracted considerable attention. Cerebral ischemia occurs with sudden neurological damage caused by interruption of blood flow to the brain (6). Oxidative stress has a major role in the pathogenesis of neurodegenerative diseases such as Alzheimer's, Parkinson, trauma, and CVA (7). Oxidative stress is the imbalance between the reactions producing free radicals and the processes neutralizing them. Free radicals are generally energetic, short-lived, and highly reactive molecules (8). Reactive oxygen species are highly active compounds causing oxidative damage to living tissues by rampaging some macromolecules such as lipids, carbohydrates, and nucleic acids. Oxidative stress is known as one of the molecular and cellular tissue degenerating mechanisms in a wide range of human diseases (9). Herbal drugs have been administered for treating diseases since the ancient times (10). *Cucurbita moschata*, a species from the *Cucurbitaceae* family, is a monoecious herbaceous vine with tendrils, yellow flowers, and berry-like fruits (11). *Cucurbita moschata* seed oil is dark green due to abundance of chlorophyll and carotenoids. In addition, this oil is enriched with oleic acid, essential fatty acid of linoleic acid, delta-7-sterol, and gamma-tocopherol that has antioxidant properties. This oil has a strong scent and high foaming ability, which makes it unsuitable for frying and that is why it is mostly used for salad dressing (12). Basaran et al. reported that the fatty acid composition of *Cucurbita moschata* seed oil is as follows: linoleic acid (42.6%), oleic acid (32.6%), palmitic acid (15.1%), and stearic acid (6.5%). Overall, 75% of this oil includes unsaturated fatty acids (13).

*Cucurbita moschata* has been used for disease treatment, and various health benefits have been accounted for this plant, e.g., destroying worms and gastrointestinal parasites, lowering cholesterol, resolving nephritis, cystitis, urethritis, and prostatitis, as well as preventing benign prostatic hyperplasia (14). In addition, these seeds have been considered as important therapeutic agents in the past few decades.

Previous studies showed that high percentage of phytosterols, omega-3 fatty acids, tocopherols, and oleic and linoleic acids, especially  $\alpha$ -linoleic acid in *Cucurbita moschata* seed oil can effectively treat intestinal parasites, prostatic hypertrophy, gastritis, and atherosclerosis. It is also effective in lowering the level of low-density lipoprotein and common blood clots, preventing irregular cardiac contractions, and decreasing the risk of vesical calculus and nephrolithiasis (15). Given the existence of antioxidants and unsaturated fatty acids in this plant, this study aimed to determine the relationship between consumption of *Cucurbita moschata* seed oil and CVA in rats.

## Methods

This empirical study was performed on 28 mature male Wistar rats weighing 250-350 gr that were bought from Pasteur Institute of Iran. The rats were kept in cyclic lighting (12 hours dark and 12 hours light) at 22°C, and were fed with standard rat food. *Cucurbita moschata* seeds were bought from a reliable apothecary shop, and then their oil was extracted by Iran Cold Pressing Company of Tehran using a cold-pressed oil extraction machine. The oil was kept in a sealed container at 10-15°C, and away from direct sunlight. The rats were randomly divided into four groups of seven as follows: one control group receiving distilled water by gavage and three empirical groups receiving 0.25, 0.5, and 0.75 ml/kg doses of *Cucurbita moschata* seed oil orally on a daily basis for 30 days. The doses were chosen according to the previous studies (16). Two hours after the last *Cucurbita moschata* seed oil consumption, the middle cerebral artery was blocked in order to evaluate stroke volume and the neurological disorders. In order to generate a CVA model (the occlusion of middle cerebral artery), the rats were anesthetized with 400 mg/kg of chloral hydrate (Merck, Germany) after weighing. Middle cerebral artery occlusion was performed based on Longa et al. instructions (17). Under microsurgery, a 0-3 nylon

suture was entered into the external carotid artery and penetrated into the anterior cerebral artery by passing through the internal carotid artery, while the pterygopalatine vein was obstructed. When a contact between the suture and anterior cerebral artery was made, blood flow was blocked from each side toward the middle cerebral artery. Obstruction was determined by entering about 20 mm of the suture into the external carotid artery and sensing resistance in advancing the suture any further. After 60 minutes of ischemia, blood flow was released again. The magnitude of the lesion was measured as follows: 24 hours after induction of ischemia, the animals were deeply anesthetized and then killed by 800 mg/kg of chloral hydrate. The brains were immediately removed and kept at 4°C for five minutes in cold normal saline. The brains, which were put into a brain matrix, were coronally cut into seven 2 mm pieces. The brains were incubated for 15 minutes in a 2% solution of 2,3,5-triphenyltetrazolium chloride (Merck, Germany) at 37°C. Some pictures were taken from the pieces using a digital camera.

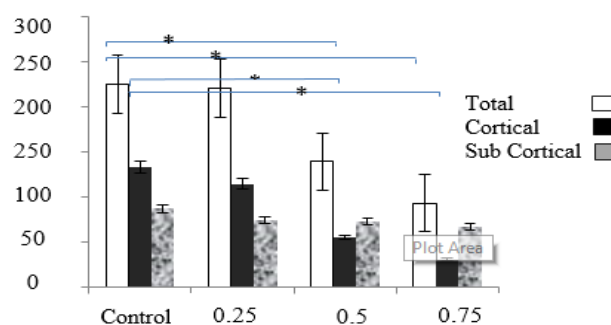
The lesion size (those areas that did not change colour) in each piece was measured by Image Tools software. The calculated values were multiplied by 2 mm thickness, and then the values of the seven pieces were added (18). The neurological examinations were done after 24 hours of reperfusion. Special care was provided from the initiation of the occlusion until killing the animals. The neurological findings were divided into five categories as follows: zero: no neurological complications; one: (complete failure at the end of the front paws) a mild focal neurologic deficit; two: (turning to left) medium focal neurologic deficit; three: (falling to the left side) severe focal; four: not able to walk spontaneously with a low level of consciousness; and five: died after 24 hours of surgery with a big part of their brain damaged after staining and their death was exclusively the result of cerebral ischemia (19). ANOVA and Mann-Whitney tests were performed to analyze the data using SPSS, version 16 and  $p < 0.05$  was considered statistically significant.

## Results

The rats were fed 0.5 and 0.75 ml/kg doses of *Cucurbita moschata* seed oil for 30 days, which reduced stroke volume in the right brain hemisphere of the rats undergoing middle cerebral artery occlusion surgery. The total stroke volume in the groups

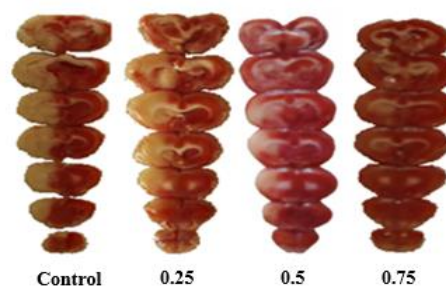
receiving 0.5 and 0.75 ml/kg doses had a significant difference with the control group, and the total percentage of infarction in the control group did not show any significant differences with the group receiving 0.25 ml/kg dose. The total stroke volume in the cortical area showed a significant difference between the groups receiving 0.5 and 0.75 ml/kg doses of *Cucurbita moschata* seed oil and the control group ( $p < 0.05$ ). However, the stroke volume in the cortical area of 0.25 ml/kg dose group was not significantly different from the control group (fig 1&2).

The effects of *Cucurbita moschata* seed oil on neurological disorders: the median score of neurological disorders decreased significantly using *Cucurbita moschata* seed oil. This reduction was significant in the groups receiving 0.5 and 0.75 ml/kg doses of *Cucurbita moschata* seed oil, as compared to the control group. The median score of neurological disorders in various groups is shown in table 1.



**Figure 1. The effect of *Cucurbita moschata* seed oil on stroke volume**

(the data are demonstrated in the form of the mean  $\pm$  standard deviation of the seven rats \* $p < 0.05$ )



**Figure 2. The brain pieces stained with 2, 3, 5-triphenyltetrazolium chloride in the studied groups (colorless areas are observed in the control and 0.25 ml/kg dose groups)**

**Table 1. Distribution of neurological scores in the experimental groups**

groups	Number						Median
	0	1	2	3	4	5	
Control	0	0	1	1	2	3	4
0.25 dose	1	0	2	0	3	1	4
0.5 dose	2	0	3	1	1	0	2
0.75 dose	2	0	4	0	1	0	2

## Discussion

The findings of this study showed a significant decrease in the development of cerebral lesions and neurological disorders in the groups receiving 0.5 and 0.75 ml/kg doses of *Cucurbita moschata* seed oil. Following the reduction or interruption of blood supply to the brain, the nerve cells within the blood flow blockage area were destroyed in the first few minutes after cerebral ischemia, which led to primary lesions. Although the nerve cells located in the margins of the blood flow blockage area (penumbra area) were alive, they did not have natural functionality and were gradually destroyed and caused secondary damage after cerebral ischemia. The nerve cells within the penumbra can be retrieved using natural medications and antioxidants (20).

It seems that *Cucurbita moschata* seed oil can diminish the extent of lesion caused by cerebral ischemia through antioxidant effects. In the present study, administration of *Cucurbita moschata* seed oil at the time of cerebral ischemia lowered the amount of motor neuron disorders on a large scale. Based on the recent studies, an increase in the amount of generated free radicals have an important role in causing motor neuron disorders following cerebral ischemia due to cell damage (21). Reduction in the level of activity of antioxidant enzymes during cerebral ischemia, and increase in production of free radicals and oxidants activate various harmful signaling paths such as increasing damage and programmed cellular death (21). In addition, it is reported that inflammatory reactions have an important role in development of infarction volume and the resulting neurological disorders (22). Due to the antioxidant properties of the compounds of this vplant, *Cucurbita moschata* seed oil decreases the volume of lesion and neurological disorders secondary to ischemia. Researchers have been able to reduce the amount of free radicals before the occurrence of cerebral ischemia. The results of this

study are not in agreement with those of Howida et al., which demonstrated that the compounds of *Cucurbita moschata* could prevent hepatotoxicity secondary to alcoholism and oxidative stress (23).

A study evaluated the preventive effects of *Cucurbita moschata* on cyclooxygenase I and cyclooxygenase II enzymes and lipid peroxidation on the growth of the cancer cells of human colon, breast, lung, and central nervous system, and compared these effects with those of ibuprofen, naproxen and vivax (commercial anti-inflammatory drugs). It was concluded that *Cucurbita moschata* has inhibitory activities (24).

Cardoso et al. suggested that vitamin E and phenolic compounds in *Cucurbita moschata* could be effective in the process of wound healing. Polyunsaturated fatty acids are pro-primers of lots of lipoic compounds that have an important role in inflammatory reactions, which can be found abundantly in *Cucurbita moschata* (25). Oliveira et al. found that *Cucurbita moschata* could cure lasting inflammatory skin lesions similar to dexamethasone, which was the first chronic and acute anti-inflammatory treatment report of *Cucurbita moschata* that can be attributed to omega-6 and omega-9 in *Cucurbita moschata* (26).

In this study, *Cucurbita moschata* seed oil reduced the damage resulting from cerebral ischemia in the rats. This result is in agreement with the findings of a study by Rashid Khan, which showed that *Cucurbita moschata* could significantly keep brain tissues from damages caused by carbon tetrachloride through reactivating antioxidant enzymes. Moreover, it was suggested that *Cucurbita moschata* could improve lipid peroxidation activities. This neuroprotective effect may be due to antioxidant activities in this plant (27).

Our findings are quite in line with the results of Jawaid et al., who found that *Cucurbita moschata* seed oil could lower the risk for dementia resulting from the inhibition of acetylcholinesterase, inflammation, and the antioxidant effects of this plant on the brain (28). These findings are in agreement with those of the present study. Considering the great amount of fatty acids, vitamins, and phenolic compounds in *Cucurbita moschata* seed, as well as the results of this study and the previous ones, it can be concluded that antioxidants in *Cucurbita moschata* seed oil can reduce the damages caused by ischemia and motor neuron disorders. Based on our findings, administration of *Cucurbita moschata* oil can decrease cellular death and consequently, reduce stroke volume and neurological disorders in rats

at risk of ischemia and reperfusion. In summary, *Cucurbita moschata* seed oil can be applied for decreasing the risk of cerebral ischemia.

### Acknowledgments

We would like to thank Dr. Javad Naserian, PhD candidate of Biostatistics, for contributing to this study.

## References

1. Allah Tavakkoli M, Shamsi Zadeh A, Jarrott B. Effect delayed sigma-1 receptor stimulating on embolic model of cerebral ischemia in rats. *J Babol Univ Med Sci*. 2011;13(4):40-7.[In Persian]
2. Lloyd-Jones D, Adams R, Carnethon M et al. Heart disease and stroke statistics--2009 update: a report from the american heart association statistics committee and stroke statistics subcommittee. *Circulation*. 2009; 119(3):e21-81.
3. Raju TN, Nelson KB, Ferriero D, Lynch JK. Ischemic perinatal stroke: summary of a workshop sponsored by the national institute of child health and human development and the national institute of neurological disorders and stroke. *Pediatrics*. 2007;120(3):609-16.
4. Bokura H, Robinson RG. Long term cognitive impairment associated with caudate stroke. *Stroke*. 1997;28(5):970-5.
5. Bogousslavsky J, Aarli J, Kimura J. Stroke: time for aglobal campaign ?. *Cerebrovasc Dis*. 2003 16(2):111-3.
6. Cho S, Park EM, Febbraio M, Anrather J, Park L, Racchumi G, et al. The class B scavenger receptor CD36 mediates free radical production and tissue injury in cerebral ischemia. *J Neurosci*. 2005;25(10):2504-12.
7. Tarawneh R, Galvin JE. Potential future neuroprotective therapies for neurodegenerative disorders and stroke. *Clin Geriatr Med*. 2010;26(1):125-47.
8. Okezie IA. Free radicals and antioxidants in health and disease. *J Am Oil Chemists' Society*. 1998;75(2):199-212.
9. Pasupathi P, Bakthavathsalam G, Saravanan G, Latha R. Evaluation of oxidative stress and antioxidant status in patients with diabetes mellitus. *J Medicine*. 2009; 5(7):770-5.
10. Xanthopoulou MN, Nomikos T, Fragopoulou E, Antonopoulou S. Antioxidant and lipoxygenase inhibitory activities of pumpkin seed extracts. *Food Res Int*. 2009;42:641-6.
11. Azaad Bakht M. Plants medicinal of classification. Tehran: Teimorzadeh Pub; 1999.[In Persian]
12. Siegmund B, Murkovic M. Change in chemical composition of pumpkin seed during the roasting process for production of pumpkin seed oil (Part 2: volatile compounds). *Food Chem*. 2004;84(3):367-79.
13. Gohari Ardabili A, Farhoosh R, Haddad Khodaparast MH. Chemical composition and physicochemical properties of pumpkin seeds (*cucurbita pepo* subsp. *pepo* var. *styriaca*) grown in Iran. *J Agr Sci Tech*. 2011;13:1053-63.
14. Ghahrae M, Khadiv- Parsi P, Kaffashi B, Momajjed A, Babaee J. Microemulsion preparation from pumpkin seed oil (*cucurbita pepo*) as an oral drug carrier. *J Med Plants*. 2009;2(30):44-53.[In Persian]
15. Fruhwirth GO, Hermetter A. Production technology and characteristics of Styrian pumpkin seed oil. *Eur J Lipid Sci Technol*. 2008;110:637-44.
16. Rabiei Z, Bigdeli MR, Rasoulia B. Neuroprotection of dietary virgin oil on brain lipidomics during stroke. *Curr Neurovasc Res*. 2013;10(3):231-7.
17. Longa EZ, Weinstein PR, Carlson S, Cummins R. Reversible middle cerebral artery occlusion without craniectomy in rats. *Stroke*. 1989;20(1):84-91.
18. Bigdeli MR, Hajizadeh S, Froozandeh M, Heidarianpour A, Rasoulia B, Asgari AR, et al. Normobarichyperoxia induces ischemic tolerance and upregulation of glutamate transporters in the rat brain and serum TNF- $\alpha$  level. *Exp Neurol*. 2008;212(2):298-306.
19. Bederson JB, Pitts LH, Tsuji M, Nishimura MC, Davis RL, Bartkowski H. Rat middle cerebral artery occlusion: evaluation of the model and development of a neurologic examination. *Stroke*. 1986; 17(3): 472-6.
20. Swanson RA, Ying W, Kauppinen TM. Astrocyte influences on ischemic neuronal death. *Curr Mol Med*. 2004; 4(2):193-205.
21. Zheng YQ, Liu JX, Wang JN, Xu L. Effects of crocin on reperfusion-induced oxidative/nitrative injury to cerebral microvessels after global cerebral ischemia. *Brain Res*. 2007;1138:86-94.
22. Allahtavakoli M, Shabanzadeh A, Roohbakhsh A, Pourshanazari A. Combination therapy of rosiglitazone, a peroxisome proliferator-activated receptor-gamma ligand, and NMDA receptor antagonist (MK-801) on experimental embolic stroke in rats. *Basic clin Pharmacol Toxicol*. 2007;101(5):309-14.



- 23.Seif HAS. Ameliorative effect of pumpkin oil (*Cucurbita pepo* L.) against alcohol-induced hepatotoxicity and oxidative stress in albino rats. *J Basic Appl Sci.* 2014;3(3):178-85.
- 24.Jayaprakasam B, Seeram NP, Nair MG. Anticancer and antiinflammatory activities of cucurbitacins from *Cucurbita andreana*. *Cancer Lett.* 2003; 189(1):11-6.
- 25.Cardoso CR, Favoreto S, Oliveir LL, Vancim JO, Barban GB, Ferraz DB, et al. Oleic acid modulation of the immune response in wound healing: A new approach for skin repair. *Immunobiology.* 2011;216(3):409-15.
- 26.Oliveira MLM, Nunes-Pinheiro DCS, Bezerra BMO, Leite LO, Tomé AR; Girão VCC. Topical anti-inflammatory potential of pumpkin (*Cucurbita pepo* L.) seed oil on acute and chronic skin inflammation in mice. *Acta Sci Veter.* 2013;41:1168.
- 27.Zaib S, Khan MR. Protective effect of cucurbita pepo fruit peel against CCl<sub>4</sub> induced neurotoxicity in rat. *Pak J Pharm Sci.* 2014; 27(6):1967-73.
- 28.Jawaid T, Shakya AK, Siddiqui HH, Kamal M. Evaluation of cucurbita maxima extract against scopolamine-induced amnesia in rats: implication of tumour necrosis factor alpha. *Z Naturforsch C.* 2014;69(9-10):407-17.