

# The Combined Effect of Caffeic Acid and Low-Power Laser on Wound Healing in Male Wistar Rats

N. Gheibi (PhD)<sup>1</sup>, A. Farzam (PhD)<sup>2</sup>, H. Azhdari-Zarmehri (PhD)<sup>\*3</sup>, F. Farsad (MSc)<sup>4</sup>

1. Incubator Center, Qazvin University of Medical Sciences, Qazvin, I.R.Iran

2. Department of Pathology, Qazvin University of Medical Sciences, Qazvin, I.R.Iran

3. Health Incubator Center, Torbat Heydariyeh University of Medical Sciences, Torbat Heydariyeh, I.R.Iran

4. Qazvin University of Medical Sciences, Qazvin, I.R.Iran

Received: Mar 6<sup>th</sup> 2014, Revised: May 14<sup>th</sup> 2014, Accepted: Sep 24<sup>th</sup> 2014.

## ABSTRACT

**BACKGROUND AND OBJECTIVE:** Wound healing is a complex, regular, and dynamic response to damage, involving interactions between different cell types, structural proteins, growth factors, and proteinase. Caffeic acid for years, and laser since the late 60s have been used for the treatment of skin conditions. This study aimed to review the combined effect of caffeic acid and laser on wound healing in male Wistar rats.

**METHODS:** In this experimental study, 36 male Wistar rats, weighing 200-250 g, were divided into four groups of 9 rats. The control group received no interventions, the second group was treated by laser, the third group received caffeic acid, and the fourth group was treated by both caffeic acid and laser. The laser-treated groups were locally treated by laser and caffeic acid after ulcer formation. On days 4, 7, and 10 after the intervention, the wound area was measured. For histological evaluation, tissue samples were obtained and the amount of hydroxyproline in urine samples was measured on day 10 via biochemical methods; afterwards, the groups were compared.

**FINDINGS:** The obtained results showed that the percentage of wound healing on days 7 and 10 in all treatment groups (groups 1, 2, and 3) was more significant than that reported in the control group. Measurement of hydroxyproline showed increased concentration in the second ( $8.9 \pm 0.4$ ), third ( $8.3 \pm 0.29$ ), and fourth ( $9.3 \pm 0.27$ ) groups, unlike the control group ( $7 \pm 0.36$ ) ( $p < 0.05$ ).

**CONCLUSION:** In this research, the wound healing effect of caffeic acid and laser, specifically their combination, was confirmed by histological studies and biochemical evaluations; moreover, hydroxyproline concentration increased in all treatment groups.

**KEY WORDS:** Wound healing, Caffeic Acid, Low-Power Laser, Hydroxyproline, Male Wistar Rat.

## Please cite this article as follows:

Gheibi N, Farzam A, Azhdari-Zarmehri H, Farsad F. The Combined Effect of Caffeic Acid and Low-Power Laser on Wound Healing in Male Wistar Rats. J Babol Univ Med Sci. 2015; 17(1):63-9.

\* Corresponding Author; H. Azhdari-Zarmehri (PhD)

Address: Department of Basic sciences, Torbat Heydariyeh University of Medical Sciences, Torbat Heydariyeh, I.R.Iran.

Tel: +98 531 2224397

E-mail: hasan.azhdari@gmail.com

## Introduction

Wound healing is a complex, regular, and dynamic response to damage, involving interactions between different cell types, structural proteins, growth factors, and proteinase (1). Extensive studies on the application of laser for tissue repair were performed in the late 60s and early 70s. Evaluation of the positive effect of low-power helium-neon laser on wound healing showed that this radiation leads to a 30-50% increase in connective cells and collagen fibers at the wound site (2,3).

Demir and colleagues evaluated the effect of low-power calcium-arsenide laser on skin ulcers of rats and reported a reduction in inflammation, a significant increase in the number of fibroblasts and hydroxyproline, increased collagen synthesis and organization, and increased tensile strength of wound (4). Helium-neon laser produces a visible red light with a wavelength of 632.8 nm. This laser is able to produce light at visible wavelengths of 544, 594, 604, and 611 nm with yellow, orange, and green colors. Moreover, it can be used with infrared wavelengths of 1523, 1152, and 3392 nm.

The penetration depth of helium-neon laser is about 6-8 mm, with an output of 7 mW (4). Moreover, as previous research has indicated, infrared rays accelerate wound healing in the skin (5). Caffeic acid, as an organic compound, is a yellow solid, composed of both acrylic and phenolic functional groups. This compound is present in all plants, since it is a key intermediate in the biosynthesis of lignin, as one of the principal components of plant biomass (6). Caffeic acid is biosynthesized by the hydroxylation of coumaroyl ester from quinic acid. This hydroxylation produces caffeic ester from shikimic acid, which converts to chlorogenic acid. Caffeic acid is a precursor to ferulic acid and these two acids are both involved in the composition of lignin components (7). So far, caffeic acid has been used as an edible compound for skin treatment. In this study, caffeic acid was used in form of injections and the combined effect of laser and caffeic acid on wound healing of rats was investigated.

## Methods

In this experimental study, 36 male Wistar rats, weighing 200-250 g, were divided into 4 groups (9 rats each). The control group received no interventions, the second group was treated by laser, the third group received caffeic acid, and the fourth group was treated by both caffeic acid and laser. The second and fourth groups were locally treated by laser and caffeic acid after ulcer formation during 5 sessions (every other day) with a wavelength of 632.8 nm, power of 10 mW, and energy of 3 J/cm<sup>2</sup>. In the third and fourth groups, caffeic acid was locally injected in 5 doses of 125 mg/kg around the ulcer under the skin.

For ulcer formation, after anesthesia induction with ketamine and xylazine (under sterile conditions), a coin-sized circular wound (diameter=1.96, area=3 cm<sup>2</sup>) with the thickness of epidermis and dermis was made by surgical scissors on top of the animals' thighs. On days 4, 7, and 10 after ulcer formation, the percentage of wound recovery was calculated, based on the wound area (in square millimeters). The measurements were performed at certain hours of the day by one individual.

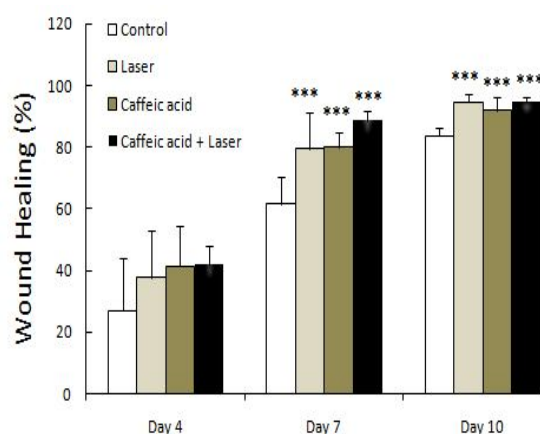
In order to measure the wound area, the animal was placed in a crocheting position and borders of skin sores were drawn on a transparent sheet. Then, AutoCAD software was used to determine the exact area of the wound. For calculating the percentage of wound healing, the following formula was applied: Wound healing percentage = (wound area on the first day - wound area on the x day) / wound area on the first day × 100. Pathological studies of tissues: On day 10, the wound was completely closed and the rats were anesthetized by ketamine and xylazine. Tissue samples of the wound and adjacent healthy skin were collected using sharp scissors and rinsed with normal saline; for stabilization, the samples were placed in formaline 10% for one week. After the preparation process, the samples were placed in paraffin formats. Slices, consisting of healthy skin and adjacent wound tissues (thickness=6 microns), were cut sequentially by Leitz microtome. The samples were stained by hematoxylin and eosin (H&E) to view the vessels, inflammatory

cells, and fibroblasts. The depth of granulation tissue was measured on the 10th day, using Motic software (40× magnification); afterwards, the mean values were calculated. Biochemical evaluation method: For many years, hydroxyproline has been used as an index for evaluating the presence of collagen in tissues. In fact, an increase in hydroxyproline is a marker of collagen formation and tissue recovery. In this study, hydroxyproline measurement was performed via biochemical methods. The amount of amino acid in the animal urine was investigated using a special kit and analyzed on the last day of the study (8). Statistical analysis: One-way ANOVA, Tukey's post-hoc test, and Dunnett test were performed, using SPSS. In order to ensure the significance level, non-parametric Kruskal-Wallis and Mann-Whitney tests were performed.  $p < 0.05$  was considered statistically significant.

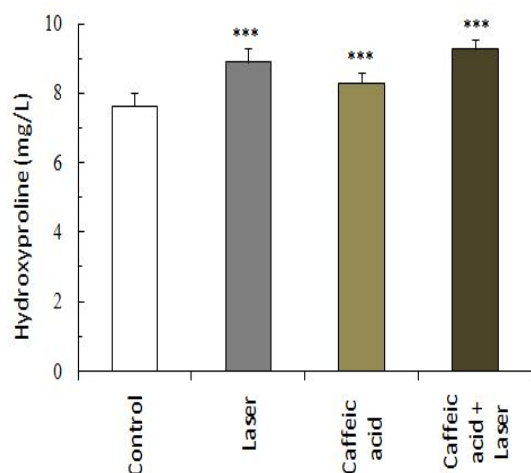
## Results

The measurement of wound area and the percentage of recovery in four groups showed that the percentage of recovery on days 7 and 10 in all three treatment groups was more significant than the control group ( $p < 0.001$ ). This significant difference was observed only between the control group, caffeic acid-treated group, and laser+acid group on day 4 of the study ( $p < 0.05$ ). Hydroxyproline measurement indicated increased concentration in three treatment groups (second, third, and fourth groups), in comparison with the control group ( $p < 0.001$ ). Moreover, histological evaluation showed a significant increase in the thickness of granulation tissue in the third group (caffeic acid-treated group), compared to the control group ( $p < 0.001$ ). Moreover, an increase was reported in the number of mast cells in the second group (laser-treated group), compared to the control group ( $p < 0.05$ ). As the measurement of wound area and percentage of recovery indicated, no significant difference was observed between the treatment and control groups in a span of four days (fig 1). The percentage of recovery on the 7th day was significantly different between the treatment and control groups

( $p < 0.001$ ). Percentage of recovery on the 10th day was significantly different between the three treatment groups and the control group ( $p < 0.001$ ). Hydroxyproline concentration, as an indicator of collagen formation, was as follows in the groups: control group ( $7.6 \pm 0.36$  mcg/L), laser-treated group ( $8.9 \pm 0.4$  mcg/L), caffeic acid-treated group ( $8.3 \pm 0.29$  mcg/L), and laser+caffeic acid group ( $9.3 \pm 0.27$  mcg/L). As the results indicated, the amount of hydroxyproline was significantly different between the control and three treatment groups ( $p < 0.001$ ) (fig 2). Also, there was a significant difference between the laser-treated and caffeic acid-treated groups ( $p < 0.01$ ). Similarly, a significant difference was observed between the caffeic acid-treated and laser+acid groups ( $p < 0.001$ ). The histological evaluation showed that the most important parameters, which were analyzable and comparable in the sliced tissues, included muscle involvement, mast cell population, and the thickness of granulation tissue; the first two parameters were evaluated non-parametrically. The obtained results showed a significant increase in the thickness of granulation tissue in the caffeic acid-treated group, compared to the control group ( $p < 0.01$ ) (fig 3-8). Also, the increase of mast cells in the laser-treated group was more significant than the control group ( $p < 0.05$ ).



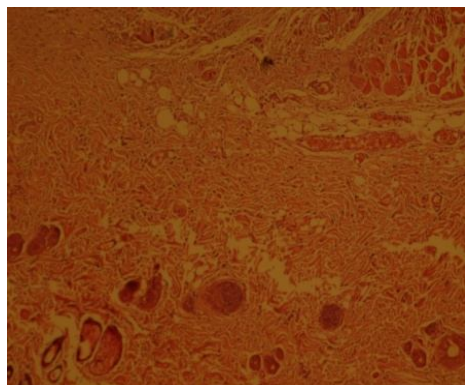
**Figure 1. Comparison of the percentage of wound recovery between the three treatment groups (laser-treated, caffeic acid-treated, and laser+acid groups) on days 4, 7, and 10 (9 rats per group) (\* $p < 0.05$ , \*\* $p < 0.01$ , \*\*\* $p < 0.001$ )**



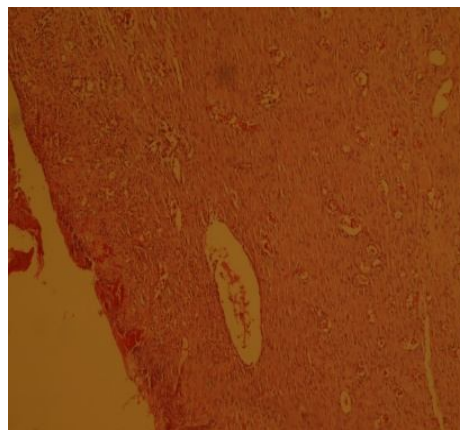
**Figure 2.** Comparison of hydroxyproline concentration (Mean±SD) in the control group and three treatment groups (laser-treated, caffeic acid-treated, and laser+caffeic acid groups) (9 rats per group) (\*\*\*)  $p < 0.001$



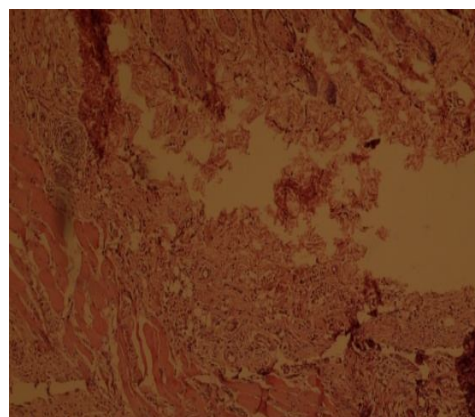
**Figure 3.** The stained image of the treated wound in the control group, using H&E technique with 40X magnification



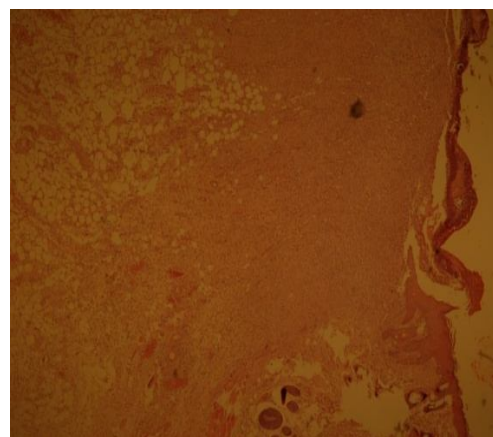
**Figure 4.** The stained image of the treated wound in the caffeic acid-treated group, using H&E technique with 40X magnification



**Figure 5.** The stained image of the treated wound in the laser-treated group (632 nm), using H&E technique with 40X magnification

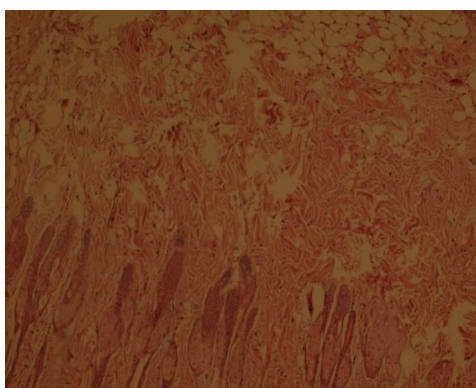


**Figure 6.** The stained image of the treated wound in the propolis-treated group, using H&E technique with 40X magnification



**Figure 7.** The stained image of the treated wound in the caffeic acid+laser group, using H&E technique with 40X magnification





**Figure 8. The stained image of the treated wound in the propolis+laser group, using H&E technique with 40 $\times$  magnification**

## Discussion

The results of this study showed the positive effect of caffeic acid and laser (with a wavelength of 632.8 nm, 10 mW power, and 3 j/cm<sup>2</sup> energy), used separately or synergistically, on wound healing. The percentage of wound recovery was more significant in the treatment groups during days 7-10, compared to the control group. Ribeiro and colleagues showed that laser polarization plays an important role in the process of wound healing, when using converged helium-neon laser (9). Initial reviews on low-power laser showed its impact on the acceleration of wound healing. Researchers showed the effectiveness of low-power helium-neon laser on the healing of open skin wounds and expressed that these rays cause a 30-50% increase in the number of connective cells and collagen fibers at the wound site (3,4).

According to previous studies, low-power lasers accelerate the wound healing process in healthy rats, increase the number of miofibroblasts, and elevate collagen deposition (10,11). Histological review results showed the significant increase of granulation tissue thickness in the caffeic acid-treated group, compared to the control group; moreover, the number of mast cells increased more significantly in the laser-treated group, compared to the control group. Laser has been applied for wound healing in biological studies. In this regard, Rabelo and colleagues showed that low-power laser is able to decrease wound

inflammation (12). In another study by Maiya et al., after ulcer formation, the rats received laser treatment by He-Me laser five days a week (with the wavelength of 632.8 nm and dose of 4.8 J/cm<sup>2</sup>). For the assessment of wound healing, biochemical analysis and histological evaluation were performed. As the results indicated, in the laser-treated group, wound healing happened earlier (18 days); however, in the control group, the average time of wound healing was 95 days (13). In this study, hydroxyproline was considered as a marker of collagen formation. In laser-treated, caffeic-treated, and acid+laser groups, hydroxyproline increased more significantly on day 10, in comparison with the control group. Moreover, Stadler and colleagues, with the use of low-power laser (with a wavelength of 830 nm), stated that laser application in rats causes an increase in the tensile strength of skin wounds (14).

In agreement with the results of laser-induced wound recovery in this study, Yamaguchi and colleagues used diabetic rats to evaluate the effect of low-power laser application on the growth of beta factor and hydroxyproline content. They used a wavelength of 660 nm and concluded that the wounds became significantly smaller with laser therapy (15). Wound healing consists of three main phases including early inflammation, proliferative phase, and maturation phase. Low-power lasers could affect most of these phases and activate wound healing (16). In fact, the selection of three time periods (days 4, 7, and 10) for wound healing in this study was in accordance with the mentioned phases; on day 12, wound healing was completed in all laser-treated groups.

With regard to the physiologic effects of laser on the reconstruction and increase of tissue blood supply and strengthening cell activity in advancing cell restoration and proliferation, not only laser resulted in faster wound healing, but also could lead to durable treatment effects. The more significant increase of hydroxyproline content in the laser+acid group, compared to the caffeic acid group, showed the superiority of laser+caffeic acid combination to caffeic acid alone. Moreover, Natarajan and colleagues

showed that caffeic acid phenethyl ester (CAPE) is a powerful combination and a specific inhibitor of NFkB activities, which may provide the molecular basis for multiple immunomodulatory and anti-inflammatory activities (17).

Additionally, Yamada and colleagues investigated the suppressive effect of caffeic acid and its derivatives on the production of reactive oxygen species (ROS), induced by ultraviolet (UV), in the skin of hairless mice and performed a pharmacokinetic analysis on organ distribution of caffeic acid in ddY mice. They showed that skin damage by UVC-induced ROS reduces the activity of free oxygen radicals (18). Similar to the previously mentioned research, in the present study, low-power laser application led to wound healing 4, 7, and 10 days after ulcer formation. Moreover, studies of tissue repair showed a significant difference in the thickness of granulation tissue between the control and caffeic acid-treated groups. Also, mast cell population increased more significantly in the laser-treated group, compared to the control group.

## Acknowledgments

We would like to thank the Research Deputy of Qazvin University of Medical Sciences for funding this study.

## References

1. Mussel RL, De Sá Silva E, Costa AM, Mandarim-De-Lacerda CA. Mast cell in tissue response to density materials: an adhesive resin, a calcium hydroxide and a glass ionomer cement. *J cell Mol Med*. 2003; 7(2): 171-8.
2. Mester E, Spiry T, Szende B, Tota JG. Effect of laser rays on wound healing. *Am J Surg*. 1971;122(4):532-5.
3. Mester E, Jaszszagi-Nagy E. The effect of laser radiation on wound healing and collagen synthesis. *Stud Biophys*. 1973;35(3):227-30.
4. Demir H, Balay H, Kirnap M. A comparative study of effects of electrical stimulation and laser treatment on experimental wound healing in rats. *J Rehabil Res Dev*. 2004;41(2):147-54.
5. Tavakoli R, Najafi Pour H, MR Hadian, Aliyaei GHR, Nabipour F, Talebian S. Comparison of the effect of infrared (IR) and Phenytoin cream on skin wound healing in rat. *J Babol Univ Med Sci*. 2004;6(2):7-11. [In Persian]
6. Boerjan W, Ralph G, Baucher M. Lignin Biosynthesis. *Ann Rev Plant Biol*. 2003;54:519-46.
7. Olthof MR, Hollman PC, Katan MB. Chlorogenic acid and caffeic acid are absorbed in humans. *J Nutr*. 2001;131(1):66-71.
8. Reddy GK, Enwemeka CS. A simplified method for the analysis of hydroxyprolin in biological tissue. *Clin Biochem*. 1996;29(3):225-9.
9. Ribeiro MS, Da Silva Dde F, De Araújo CE, De Oliveira SF, Pelegrini CM, Zorn TM, et al. Effects of low-intensity polarized visible laser radiation on skin burns: a light microscopy study. *J Clin Laser Med Surg*. 2004;22(1):59-66.
10. Lyons RF, Abergel RP, White RA, Dwyer RM, Castel JC, Uitto J. Biostimulation of Wound healing in vivo by a helium-neon laser. *Ann Plast Surg*. 1987;18(1):47-50.
11. Medrado AR, Pugliese LS, Reis SR, Andrade ZA. Influence of low – level laser therapy on wound healing and its biological action upon myofibroblasts. *Lasers Surg Med*. 2003;32(3):239-44.
12. Rabelo SB, Villaverde AB, Nicolau R, Salgado MC, Melo Mda S, Pacheco MT. Comparison between wound healing in induced diabetic and nondiabetic rats after low-level laser therapy. *Photomed Laser Surg*. 2006; 24(4):474-9.
13. Maiya GA, Kumar P, Rao L. Effect of low intensity helium–neon (He–Ne) Laser irradiation on diabetic wound healing dynamics. *Photomed Laser Surg*. 2005;23(2):187-90.
14. Stadler I, Lanzafame RJ, Evans R, Narayan V, Dailey B, Buehner N, et al. 830-nm irradiation increases the wound tensile strength in a diabetic murine model. *Lasers Sur Med*. 2001;28(3):220-6.
15. Yamaguchi Y, Yoshikawa K. Cutaneous wound healing: an update. *J Dermatol*. 2001;28(10):521-34.

16.Moyer KE, Davis A, Saggars GC, Mackay DR, Ehrlich HP. Wound healing: the role of gap junctional communication in rat granulation tissue maturation. *Exp Mol Pathol.* 2002;72(1):10-6.

17.Natarajan K, Singh S, Burke TR Jr, Grunberger D, Aggarwal BB. Caffeic acid phenethyl ester is a potent and specific inhibitor of activation of nuclear

transcription factor NF-Kappa B. *Proc Natl Acad Sci U S A.* 1996;93(17): 9090-5.

18.YamadaY, Yasui H, Sakurai H. Suppressive effect of caffeic acid and its derivatives on the generation of UVA-induced reactive oxygen species in the skin of hairless mice and pharmacokinetic analysis on organ distribution of caffeic acid in ddY mice. *Photochem Photobiol.* 2005;82(6):1668-76.