



Examination of Cuffed Catheter Tip Thrombosis in Hemodialysis Patients

P. Tayebi (MD)¹, A. Asri (MD)¹, A. Gholizadeh-Pasha (MD)^{*2}, R. Pourkia (MD)¹,
H. Shirafkan (PhD)³, F. Mahmoudlou (MD)¹, N. Ziaie (MD)¹

1.Clinical Research Development Unite of Rouhani Hospital, Babol University of Medical Sciences, Babol, I.R.Iran.

2.Clinical Research Development Unite of Shahid Beheshti Hospital, Babol University of Medical Sciences, Babol, I.R.Iran.

3.Social Determinants of Health Research Center, Health Research Institute, Babol University of Medical Sciences, Babol, I.R.Iran.

***Corresponding Author: A. Gholizadeh-Pasha (MD)**

Address: Department of Surgery, Shahid Beheshti Hospital, Babol University of Medical Sciences, Babol, I.R.Iran.

Tel: +98 (11) 32252071. **E-mail:** drgholizadehpasha@yahoo.com

Article Type

ABSTRACT

Research Paper

Background and Objective: The use of cuffed catheters for hemodialysis in patients with chronic kidney failure has increased. Thrombosis of cuffed catheter tip is a dangerous complication that can lead to catheter dysfunction and even threaten the patient's life. This study was conducted with the aim of determining the prevalence and causes of cuffed catheter tip thrombosis in order to maintain its function.

Methods: This cross-sectional study was conducted in 2020 on patients with chronic kidney failure in Babol who were referred by a nephrologist due to dysfunction of the cuffed catheter. After recording demographic information, all patients were candidates for echocardiography and then venography through the catheter in the angiography unit to determine the cause of cuffed catheter dysfunction. The presence of thrombosis in the catheter tip, the formation of fibrin sheath and the location of the catheter tip were investigated.

Findings: 91 patients, including 54 men (59.3%) and 37 women (40.7%) were included in the study due to lack of effective dialysis caused by cuffed catheter dysfunction. The average age of the patients was 62.01 ± 14.66 years with a minimum age of 29 and a maximum of 88 years. The most common location of catheter placement was the right internal jugular vein in 79 cases (86.8%). The incidence rate of thrombosis in cuffed catheter tips was 53 cases (59%), with inappropriate location of the catheter tip in 31 cases (58.49%) as the most common cause, while formation of fibrin sheath in the catheter tip in 12 patients (22.64%) and inappropriate catheter length in 10 patients (18.86%) were respectively the other common causes of thrombosis in the tips of cuffed catheters.

Conclusion: The results of the study showed that inappropriate location of the catheter tip was the most common cause of thrombosis in cuffed catheter tips. Therefore, it is recommended to use fluoroscopy during cuffed catheter insertion to ensure the correct placement of the catheter tip inside the right atrium.

Keywords: *Central Venous Catheter, Thrombosis, Catheter Obstruction.*

Received:

Apr 30th 2023

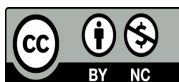
Revised:

May 23rd 2023

Accepted:

Jul 25th 2023

Cite this article: Tayebi P, Asri A, Gholizadeh-Pasha A, Pourkia R, Shirafkan H, Mahmoudlou F, et al. Examination of Cuffed Catheter Tip Thrombosis in Hemodialysis Patients. *Journal of Babol University of Medical Sciences*. 2024; 26: e15.



Introduction

Thrombosis associated with dialysis catheters can be divided into several types, including fibrin sheath formation along the length of the central vein catheter, intraluminal thrombosis of the catheter, catheter tip thrombosis, and central vein wall thrombosis leading to deep vein thrombosis (1). Thrombosis related to cuffed catheter tip is a common clinical scenario that is often a significant therapeutic problem in hemodialysis patients. The incidence of asymptomatic catheter tip-related thrombosis varies widely, but has been reported in 8% to 66% of patients (2). In the study of Li et al., 38 patients with transjugular dialysis catheters were examined, among which the causes of catheter dysfunction were the formation of fibrin sheath in 21 cases (55.2%), catheter tip thrombosis in 7 cases (18.4%), 3 cases (7.8%) of vein thrombosis and 4 cases (10.5%) of intracatheter thrombosis (3). Also, in the study of Dilek et al., the rate of thrombus formation at the tip of the catheter in the right atrium was 18% (4).

Catheter tip position is a controversial cause of catheter tip-related thrombus formation (5), but the Kidney Foundation-Kidney Disease Outcome Quality Initiative (NKF KDOQI) guidelines recommend that the hemodialysis cuffed catheter tip be placed in the right atrium (6). Catheter tip thrombosis-related occlusion of cuffed catheter may occur in early or late catheter dysfunction. Damage to the intima layer of vessels, turbulent blood flow and activation of coagulation cascades with the formation of fibrin sheath are the main factors of thrombus formation. Thrombosis can form inside the duct and cause direct obstruction of the blood flow, or it can form outside the duct. Extraluminal thrombosis, such as right atrial thrombosis or parietal thrombosis, may cause external pressure on the catheter, resulting in poor blood flow and inadequate dialysis (7). Thrombosis formation on catheters embedded in central veins can lead to serious complications including pulmonary embolism, septic embolism, long-term stenosis of the central vein and cardiac arrhythmias (8). Catheter tip thrombosis in the right atrium is a potentially serious complication of hemodialysis catheters associated with an overall mortality rate of 18% (9).

The selective treatment of catheter tip thrombosis is controversial due to lack of data. In a systematic review of 71 reported cases of catheter-related right atrial thrombosis in dialysis patients, investigators recommended that anticoagulation be initiated and the dialysis catheter removed if the thrombus was less than 6 cm. Surgical thrombectomy should be considered in patients who have contraindications to anticoagulation, thrombus greater than 6 cm, or heart abnormalities (10). Other treatment methods include changing the catheter on the guidewire, changing the location of the catheter tip in the superior vena cava instead of the right atrium, or thrombolysis. When catheter-related thrombosis is diagnosed, treatment usually begins with anticoagulants, but given the propensity for profuse bleeding in dialysis patients, it is unclear how long it should be continued. The duration of anticoagulation may vary depending on the degree of thrombosis, the risk of bleeding, and the need for continuous catheter use (7).

Considering the serious problems secondary to the thrombosis of cuffed catheter tips, such as the possibility of pulmonary embolism, catheter infection, occlusion of the superior vena cava and the occurrence of superior vena cava syndrome following it, determining the prevalence and related causes in hemodialysis patients is important. Therefore, in this study, the prevalence and causes of cuffed catheter tip thrombosis in hemodialysis patients of Babol in 2020 were investigated.

Methods

After being approved by the ethics committee of Babol University of Medical Sciences under the code IR.MUBABOL.REC.1400.089, this cross-sectional study was conducted in 2020 on 154 hemodialysis patients in Babol who were undergoing dialysis with a jugular cuffed catheter. Of these, 91 patients were referred to the Vascular Surgery Clinic of Ayatollah Rouhani Hospital in Babol due to catheter dysfunction and the resulting lack of effective dialysis. All patients over 20 years of age with chronic kidney failure who were treated through a catheterized central vein catheter (BD Bard, HemoStar™ Long-Term Hemodialysis Catheter) were included in the study. According to the National Kidney Foundation's Kidney Disease Outcomes Quality Initiative (NKF-KDOQI) guidelines, a blood flow rate of less than 300 ml per minute through the dialysis catheter or the inability to perform hemodialysis in one session was considered as catheter dysfunction (11).

After registering the demographic information to determine the cause of cuffed catheter dysfunction, the patients became candidates for transesophageal echocardiography and venography through the catheter in the angiography unit. Patient information was collected, which included the length and location of the cuffed catheter, the cause of catheter malfunction, medication-based locking of catheter, the formation of thrombosis at the tip of the catheter, medications effective in the coagulation process and blood pressure, underlying diseases, and whether the side of the jugular catheter insertion site was in the same direction as the organ with arteriovenous fistula, using a predesigned questionnaire. Central indices (mean, median, mode), dispersion indices (variance, standard deviation, range of changes, coefficient of variation) as well as frequency and frequency percentage were used for statistical analysis of data. All data analysis was done using SPSS version 25.

Results

91 patients, including 54 men (59.3%) and 37 women (40.7%) were included in the study due to the lack of effective dialysis caused by cuffed catheter dysfunction. The mean age of the patients was 62.01 ± 14.66 years with a minimum age of 29 and a maximum of 88 years. The most common location of catheter placement was the right internal jugular vein in 79 cases (86.8%). Heparin locking of catheter was performed in 82 patients (90.1%). Other information related to the length and placement of cuffed catheters, medications effective in the coagulation process and blood pressure, underlying diseases, and whether the side of the jugular catheter insertion site was in the same direction as the organ with arteriovenous fistula, are shown in Table No. 1.

In the echocardiography performed for the patients, the frequency of thrombosis of cuffed catheter tip was 53 cases (59%). The results of venography of the patients showed that the inappropriate location of the catheter tip with a frequency of 46 cases (50.5%), intraluminal thrombosis with 26 cases (28.6%), fibrin sheath with 16 cases (17.6%) and inappropriate catheter length with 3 cases (3.3%) were respectively in the next ranks of the etiology of dysfunction of cuffed catheters. In 53 patients with catheter tip thrombosis, the most common cause of thrombosis was the inappropriate location of the catheter tip in 31 cases (58.49%). The formation of fibrin sheath in the tip of the catheter in 12 patients (22.64%) and the inappropriate length of the catheter in 10 patients (18.86%) were respectively among the other causes of thrombosis in the tip of cuffed catheters.

Table 1. The frequency and percentage of factors affecting the dysfunction of cuffed jugular catheters in hemodialysis patients in Babol in 2020

Factors affecting the performance of jugular cuffed catheters	Number(%)
Catheter insertion site	
Right internal jugular vein	83(91.2)
Left internal jugular vein	8(8.8)
Cuffed catheter length (tip to cuff)	
19 cm	84(92.3)
23 cm	7(7.7)
Catheter locking	
Without medication	9(9.9)
Heparin locking	82(90.1)
Consumable drugs affecting the coagulation process	
Without medication	37(40.7)
Aspirin	29(31.9)
Heparin	17(18.7)
Warfarin	8(8.8)
Medications that affect blood pressure	
Without medication	16(17.6)
Diuretics	36(39.6)
Vasodilators	5(5.5)
Beta blockers	14(15.4)
Calcium channel blockers	11(12.1)
ACE inhibitors	5(5.5)
Angiotensin II receptor blockers	4(4.4)
catheter insertion site being in the same direction as the organ with arteriovenous fistula	
No simultaneous arteriovenous fistula	75(82.4)
Same direction as fistula	0(0)
Opposite direction with fistula	16(17.6)

Discussion

According to the results of this study, the most common cause of cuffed catheter tip thrombosis in hemodialysis patients was the inappropriate location of the catheter tip, while the creation of a fibrin sheath in the catheter tip and inappropriate length of the catheter, respectively, were the most common causes of thrombosis in cuffed catheter tips. In other studies, the importance of placing the tip of cuffed catheters in the right place to prevent dysfunction of cuffed catheters has been mentioned, which is consistent with the results of the present study (12-14). The appropriate location of the cuffed catheter tip has been debated for a long time, and there are conflicting recommendations in published articles over the past years (15, 16).

According to the 2020 guidelines of the National Kidney Foundation's Kidney Disease Outcomes Quality Initiative (NKF-KDOQI), it is recommended to place the cuffed catheter tip in the middle of the right atrium to provide the maximum blood flow for hemodialysis (11). These findings indicate that the inappropriate location of the catheter tip is one of the most common causes of dysfunction and thrombosis in cuffed catheters.

Also, the results of our study showed that the prevalence of thrombosis in cuffed catheter is high. Most of the studies conducted on the rate of thrombosis in cuffed catheters showed similar findings. In their study, Beigi et al. and Shrestha et al. stated that the prevalence of thrombosis was relatively high (17, 18). The long-term remaining of cuffed catheters, manipulation, venous trauma, vein dilatation after venoplasty during the placement of catheters, as well as the larger diameter of the dilator and catheter are the causes of the higher prevalence of thrombosis, and the difference of each of these factors in studies can cause changes in the incidence of thrombosis. The findings of our study indicated that thrombosis was less frequent in catheters that were locked with anticoagulant drugs. Catheter thrombosis is resolved by using thrombolytic drugs, and this finding shows that locking catheter with anticoagulant drugs in patients reduces the incidence of thrombosis, which is consistent with the findings of Yildiz et al.'s research (19).

On the other hand, there are also studies that had different findings compared to our study. In a study conducted by Dunea et al., they observed that the use of anticoagulants did not have significant results in reducing the amount of thrombosis (20). Of course, the difference in the results could be due to the difference in the time of investigation of thrombosis, because the incidence of thrombosis in the first month decreases to 1.3% and after 3 months of catheter insertion to 0.8% (17). Also, previous studies have shown that catheter placement in the left internal jugular vein is associated with a higher risk of thrombosis compared to the right side. Of course, the higher prevalence of thrombosis in the right jugular vein is due to the fact that the right jugular vein is the first chosen site for cuffed catheters (21, 22).

Thrombosis associated with cuffed catheter tip is a serious challenge in hemodialysis patients. Inappropriate location of the catheter tip has been the most common cause of thrombosis in cuffed catheter tips, so it is recommended to use fluoroscopy during cuffed catheter insertion to ensure correct positioning of the catheter tip inside the right atrium. Also, timely treatment of cuffed catheter tip thrombosis can prevent serious problems in hemodialysis patients and its dysfunction.

Conflict of interest: The authors declare that there is no conflict of interest.

Acknowledgment

Hereby, the Deputy of Research and Technology of Babol University of Medical Sciences for supporting this research and colleagues of Vascular Surgery Department of Ayatollah Rouhani Hospital of Babol are gratefully acknowledged.

References

1. Baumann Kreuziger L, Jaffray J, Carrier M. Epidemiology, diagnosis, prevention and treatment of catheter-related thrombosis in children and adults. *Thromb Res*. 2017;157:64-71.
2. Chick JF, Reddy SN, Bhatt RD, Shin BJ, Kirkpatrick JN, Trerotola SO. Significance of Echocardiographically Detected Central Venous Catheter Tip-Associated Thrombi. *J Vasc Interv Radiol*. 2016;27(12):1872-7.
3. Li W, Li F, Wang H, Long X, Ghimire O, Pei Y, et al. Thrombotic complications and tip position of transjugular chronic dialysis catheter scheduled into superior vena cava: Findings on HR-MRCP and HR-T2WI. *Medicine (Baltimore)*. 2017;96(26):e7135.
4. Dilek M, Kaya C, Karatas A, Ozer I, Arık N, Gulel O. Catheter-related atrial thrombus: tip of the iceberg?. *Ren Fail*. 2015;37(4):567-71
5. Chopra V, Flanders SA, Saint S, Woller SC, O'Grady NP, Safdar N, et al. The Michigan Appropriateness Guide for Intravenous Catheters (MAGIC): Results From a Multispecialty Panel Using the RAND/UCLA Appropriateness Method. *Ann Intern Med*. 2015;163(6 Suppl):S1-40.
6. National Kidney Foundation. K/DOQI clinical practice guidelines for chronic kidney disease: evaluation, classification, and stratification. *Am J Kidney Dis*. 2002;39(2 Suppl 1):S1-266.
7. Miller LM, MacRae JM, Kiaii M, Clark E, Dipchand C, Kappel J, et al. Hemodialysis Tunneled Catheter Noninfectious Complications. *Can J Kidney Health Dis*. 2016;3:2054358116669130.
8. Geerts W. Central venous catheter-related thrombosis. *Hematology Am Soc Hematol Educ Program*. 2014;2014(1):306-11.
9. Stavroulopoulos A, Aresti V, Zounis C. Right atrial thrombi complicating haemodialysis catheters. A meta-analysis of reported cases and a proposal of a management algorithm. *Nephrol Dial Transplant*. 2012;27(7):2936-44.
10. Field M, Pugh J, Asquith J, Davies S, Pherwani AD. A stuck hemodialysis central venous catheter. *J Vasc Access*. 2008;9(4):301-3.
11. Lok CE, Huber TS, Lee T, Shenoy S, Yevzlin AS, Abreo K, et al. KDOQI Clinical Practice Guideline for Vascular Access: 2019 Update. *Am J Kidney Dis*. 2020;75(4 Suppl 2):S1-S164.
12. Agarwal AK, Haddad N, Boubes K. Avoiding problems in tunneled dialysis catheter placement. *Semin Dial*. 2019;32(6):535-40.
13. Auer J, Braun J, Lenk J, Gollrad J, Ro SR, Hamm B, et al. Tunneled hemodialysis catheter insertion: Above, within, or below the right atrium-Where is the tip?. *Acta Radiol Open*. 2022;11(9):20584601221122421.
14. Smith T, Kaufman C, Quencer K. Internal Jugular Central Venous Catheter Tip Migration: Patient and Procedural Factors. *Tomography*. 2022;8(2):1033-40.
15. Scott WL. Central venous catheters. An overview of Food and Drug Administration activities. *Surg Oncol Clin N Am*. 1995;4(3):377-93.
16. Vesely TM. Central venous catheter tip position: a continuing controversy. *J Vasc Interv Radiol*. 2003;14(5):527-34.
17. Beigi AA, Ghaheri H, Davarpanah Jazi AH, Alavi L. The Efficacy and Complications of Temporary and Permanent Central Venous Catheters in Patients with Renal Failure. *J Isfahan Med Sch*. 2012;29(163):2011-7. [In Persian]
18. Shrestha KR, Gurung D, Shrestha UK. Outcome of Cuffed Tunneled Dialysis Catheters for Hemodialysis Patients at a Tertiary Care Hospital: A Descriptive Cross-sectional Study. *JNMA J Nepal Med Assoc*. 2020;58(226):390-5.
19. Yildiz I. Risk Factors Associated with Dysfunction of Permanent Tunneled Cuffed Hemodialysis Catheters; Single Center Experience. *Acibadem Univ Sağlık Bilim Derg*. 2021;12(3):558-63.

- 20.Dunea G, Domenico L, Gunnerson P, Winston-Willis F. A survey of permanent double lumen catheters in hemodialysis patients. ASAIO Trans. 1991;37(3):M276-7.
- 21.Oliver MJ, Edwards LJ, Treleaven DJ, Lambert K, Margetts PJ. Randomized study of temporary hemodialysis catheters. Int J Artif Organs. 2002;25(1):40-4.
- 22.Salik E, Daftary A, Tal MG. Three-dimensional anatomy of the left central veins: implications for dialysis catheter placement. J Vasc Interv Radiol. 2007;18(3):361-4.