Journal of
Babol University of Medical Sciences
JBUMS
e-ISSN: 2251-7170 p-ISSN: 1561-4107

Xanthogranulomatous Reaction Mimicking Recurrence of Papillary Thyroid Carcinoma after Lobectomy: A Case Report

H. Hemmati (MD)[1], Y. Ashoorian (MD)[2], P. Karimian (MD)[*2]

1.Department of Surgery, School of Medicine, Guilan University of Medical Sciences, Rasht, I.R.Iran.

2.Department of Pathology, School of Medicine, Guilan University of Medical Sciences, Rasht, I.R.Iran.

Article Type

Case Report

Received:
Dec 7th 2022
Revised:
Mar 5th 2023
Accepted:
May 7th 2023

ABSTRACT

Background and Objective: Xanthogranuloma is an uncommon and chronic inflammatory reaction characterized by the accumulation of foamy macrophages in various body tissues such as the skin, gallbladder, and kidney, and is often mistaken for malignancy. The aim of this report is to introduce a case of severe xanthogranulomatous reaction in the thyroid bed following previous lobectomy treatment of papillary thyroid carcinoma, which has now been re-operated with a clinical diagnosis of tumor recurrence.

Case Report: The patient is a 42-year-old woman who underwent subtotal thyroidectomy (lobectomy) two years ago due to a neck mass and was diagnosed with papillary thyroid carcinoma. Now, the patient referred with a sore throat. During the examination, the mass was felt at the previous thyroidectomy site, which was re-operated after ultrasound and CT scan with the diagnosis of recurrence of the previous tumor. In the evaluation of the pathology of the thyroid tissue along with the surrounding adhesive tissues, and in the initial sections of the cell plates, abundant clear and granular cytoplasm between the muscles and CD connective tissue as well as extensive infiltration of fat were observed. After the examination and performing immunohistochemistry for CD_{68}, S_{100} and CK markers, all negative cases, except the marker CD_{68}, which is specific for macrophages, were positive, suggesting the diagnosis of xanthogranuloma. Then, all tissues were checked for recurrence of papillary carcinoma, and the result was negative.

Conclusion: Based on the results of this reported case, xanthogranuloma should be considered in patients undergoing thyroid lobectomy with recurrence of papillary thyroid carcinoma.

Keywords: *Xanthogranuloma, Papillary Thyroid Carcinoma, Recurrence, Thyroidectomy.*

Cite this article: Hemmati H, Ashoorian Y, Karimian P. Xanthogranulomatous Reaction Mimicking Recurrence of Papillary Thyroid Carcinoma after Lobectomy: A Case Report. *Journal of Babol University of Medical Sciences*. 2023; 25(1): 334-9.

© The Author(S).
Publisher: Babol University of Medical Sciences

[*]Corresponding Author: P. Karimian (MD)
Address: Department of Pathology, Razi hospital, Shohada-e-Salamat St, Rasht, I.R.Iran.
Tel: +98 (13) 33550028. **E-mail:** paridokhtkarimian@yahoo.com

[DOI: 10.22088/jbums.25.1.334]

Introduction

Xanthogranuloma (XG) is a chronic and benign inflammatory reaction that often involves the skin and subcutaneous tissue, characterized by the accumulation of foamy macrophages. It is often seen in the skin of infants as Juvenile Xanthogranuloma in the upper half of the body and sometimes in multiple forms. Xanthogranulomatous reaction can be one of the causes of chronic and uncommon inflammation in various organs of the body, such as the gallbladder, kidney, appendix, breast, bone, female reproductive system, salivary glands, and pituitary gland (1, 2).

Papillary thyroid carcinoma (PTC) is the most common malignancy of the thyroid gland and the overall survival of this disease is excellent and only 6.6% have local recurrence and is often seen in patients who undergo unilateral and subtotal thyroidectomy without removal of regional lymph nodes. However, recurrence is rare in patients who undergo total thyroidectomy along with radioactive iodine treatment (3).

Xanthogranuloma is rare in the head and neck region, and few cases have been reported in thyroglossal duct cysts. In some cases, due to the nature of infiltration in adjacent tissues, it is clinically and radiologically included in the differential diagnosis of malignant tumors (4, 5).

The aim of this case report was the creation of a mass at the site of a previous subtotal thyroidectomy due to papillary thyroid carcinoma, which was re-operated as a recurrence, but there was no sign of recurrence in the pathology examination, and only the extensive inflammatory reaction of xanthogranuloma was raised.

Case Report

This study was approved by the ethics committee of Guilan University of Medical Sciences with code IR.GUMS.REC.1401.433. The patient is a 42-year-old woman who was examined two years ago with the feeling of a lump in her neck. In laboratory tests, the thyroid function results were normal, and in the ultrasound, multiple hypoechoic nodules with calcification with cystic changes were observed in the left lobe of the thyroid. After fine needle aspiration (FNA) from the thyroid, a diagnosis of papillary thyroid carcinoma (Bethesda V) was made for the patient, who underwent subtotal thyroidectomy on the right side and part of the left lobe, and was due to the strong adhesion of the left lobe to the trachea, which could not be removed completely. In the pathology of the thyroid gland, multifocal papillary thyroid carcinoma was detected in both lobes without sent lymph nodes, which was considered as stage I. In the next step, the patient was treated with radioactive iodine. After two years (current reference), the patient returned with a neck mass that was not detected in the ultrasound of the thyroid gland and instead, three hypoechoic foci without vascularity were found in the previous thyroidectomy site with the diagnosis of recurrence and involved lymph nodes, and a CT scan was suggested for supplementary diagnosis. In the performed CT scan, a mass in the anterior external region of the trachea was detected, suggesting tumor recurrence along with the remaining left lobe with nodular appearance of three lymph nodes in the 4th cervical region (Figure 1).

With the diagnosis of recurrence of papillary thyroid carcinoma, the patient was a candidate for re-operation, and the mass of the thyroid bed with extensive adhesions was removed and a few light brown segments with a homogenous surface were sent for pathology examination. In the initial examination, which was done by routine hematoxylin and eosin (H&E) staining, there was intense proliferation of epithelioid cells with light granular cytoplasm in the form of plates between fibrous-connective tissue and skeletal muscles. The nature of these cells after immunohistochemical staining for CD_{68}, S_{100} and CK markers showed that they are macrophages, and the only marker expressed in these cells was CD_{68} (Figure 2).

[DOI: 10.22088/jbums.25.1.334]

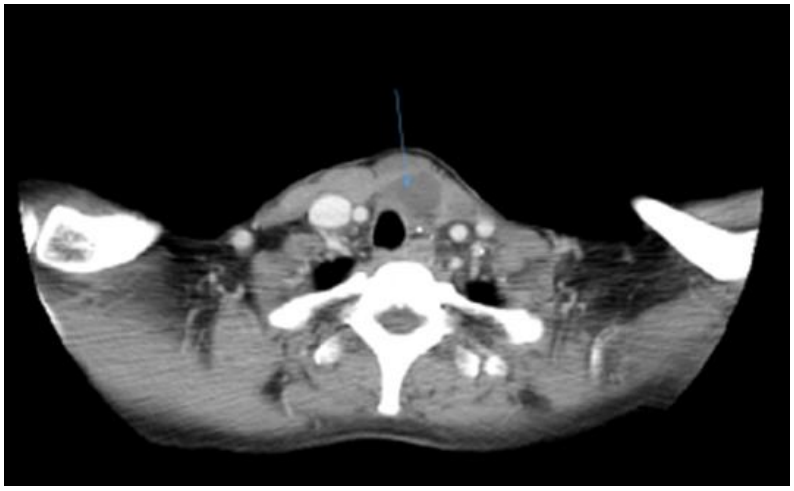

Figure 1. The mass in the anterior external region of the trachea suggesting the recurrence of the thyroid mass along with three lymph nodes in the 4th cervical region

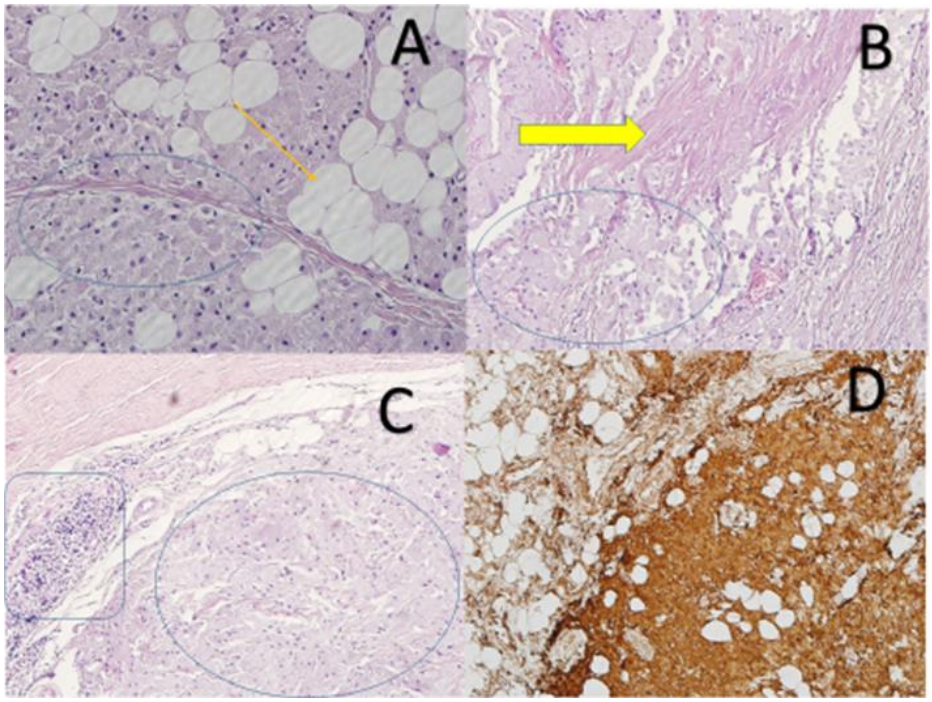

Figure 2. Proliferation of light cells with granular cytoplasm (oval). A: fat (narrow arrow), B: muscles (wide arrow), C: infiltration of inflammatory cells, D: CD_{68} in immunohistochemical marker staining

The important differential diagnosis of the pathology of this type of cells is Malakoplakia, in which Michaelis Gutmann bodies are observed, and Von Kossa and Pearls are respectively determined by specific staining of calcium and iron in these cell sediments; both types of staining were negative in our sample. To rule out intracellular mycobacterium, which is another differential diagnosis of the existence of these types of cells, Ziehl Neelsen staining was also performed, and did not show any type of acid-fast bacteria. Then, to ensure the absence of recurrence of PTC, all the tissue caused by surgery was examined, and there was no evidence of carcinoma, and only severe xanthogranulomatous reaction was seen in all the sent tissue. It

[DOI: 10.22088/jbums.25.1.334]

is worth noting that xanthogranuloma is a benign condition and complete removal of the tissue can be its treatment and it usually does not recur. Now that 6 months have passed since the patient's surgery, the patient has no symptoms of recurrence and has been treated with a dose of radioactive iodine and then levothyroxine tablets, and the patient only reports a brief dryness of the neck.

Discussion

In our study, following previous thyroid lobectomy surgery and then radioactive iodine treatment in the neck region, the patient had a severe xanthogranulomatous reaction in the thyroid bed, which, along with adhesion to the surrounding tissues, created a mass that clinically and radiologically resembled PTC tumor recurrence. It seems that xanthogranuloma reaction is rare in the head and neck region, especially in the thyroid, and only a limited number of thyroglossal cysts have been observed in the neck region. Other cases that have been reported in the head and neck occurred after sinus endoscopy and creation of a mass in the orbital cavity (6). Xanthogranuloma is an uncommon, chronic and benign inflammation that can be seen in different tissues of the body. An important differential diagnosis in pathology is malakoplakia, which is usually seen in the genitourinary system and causes a more limited reaction (7).

Sometimes, this reaction can be very intense and even by infiltrating the surrounding connective tissues, fibroblasts, muscles and surrounding fat, it mimics the state of malignant and invasive tumors (8-10). In some cases, this reaction in the digestive tract is initially created in the form of a mass in the large intestine, or it is clinically considered to be accompanied by primary gastric carcinoma with a tumor with large expansion (11, 12).

Some cases have also been reported in parotid salivary gland, limbus, pituitary gland, or as a primary neck tumor or after chemoradiotherapy of head and neck cancer (13-15). It seems that the rupture of cysts such as thyroglossal in the neck, Rathke in the pituitary gland and Rokitansky-Aschoff in the gallbladder and also the appendix can cause xanthogranuloma (16, 17). The cause of this reaction is not clear, but it can be caused by infection, trauma, obstruction, foreign body, and chemoradiation, or it may be accompanied by a tumor due to an immune system disorder such as chemotaxis, a disorder in lipid transfer, or an overreaction to microorganisms such as Escherichia coli or Proteus, which depends on the genetic predisposition and nutrition of the person (10). In addition, trauma caused by surgery, foreign body, and chemoradiotherapy can cause xanthogranuloma, and this reaction should be considered as a complication in these cases (6, 7, 15).

In the study of Krishna et al. in India, the most common organ involved was the gallbladder, followed by the kidney. The mean age was 44-63 years and the ratio of women to men was 3.2 to 1. This reaction is completely benign, sometimes it regresses by itself, sometimes it responds to antibiotics, but it does not recur after complete removal, and its prognosis is good (10). In the case of our study, there was a 42-year-old woman who developed a large xanthogranulomatous reaction after surgery, which is almost consistent with the mentioned study in terms of gender and age.

It seems that xanthogranulomatous reaction should be considered in clinical and radiological diagnoses as a mimic of invasive tumors in common organs such as gallbladder and kidney. One can also consider this reaction in masses that are created after surgery, chemoradiotherapy, and especially in pathology samples during surgery in frozen sections as a differential diagnosis to avoid unnecessary extensive surgeries.

[DOI: 10.22088/jbums.25.1.334]

Acknowledgment

We hereby express our gratitude to Dr. Alireza Mesbah and the staff of the Pathology Department of Razi Hospital in Rasht who helped in preparing the diagnostic slides.

[DOI: 10.22088/jbums.25.1.334]

References

1.Goldblum JR, Lamps LW, Mckenney JK, Myers JL. Rosai and Ackerman's Surgical Pathology, 11st ed. Philadelphia: Elsevier; 2017. p. 95-6.

2.Cozzutto C, Carbone A. The xanthogranulomatous process. Xanthogranulomatous inflammation. Pathol Res Pract. 1988;183(4):395-402.

3.Goldblum JR, Lamps LW, Mckenney JK, Myers JL. Rosai and Ackerman's Surgical Pathology, 11st ed. Philadelphia: Elsevier; 2017. p. 297-309.

4.Nomura T, Momose S, Takashima M, Kikuchi S. A case of neck xanthogranulomatous inflammation-suspected malignant tumor. Clin Case Rep. 2019;7(7):1323-6.

5.Taskin OC, Gucer H, Winer D, Meter O. Thyroglossal Duct Cyst Associated with Xanthogranulomatous Inflammation. Head Neck Pathol. 2015;9(4):530-3.

6.Gu JH, Lee GH. Xanthogranuloma formation after endoscopic sinus surgery A case report. Int J Surg Case Rep. 2020;76:263-5.

7.Singer L, Calkins SM, Horvai AE, Ryan WR, Yom SS. Xanthogranuloma in the heavily irradiated low neck in a patient with head and neck cancer. J Otolaryngol Head Neck Surg. 2016;45:20.

8.Zahid IG, Kummarapurugu S, Alrefai S. Xanthogranulomatous Breast Mass: An Unusual Presentation. Cureus. 2021;13(9):e17973.

9.Kudra Danial A, Klaho A, Abou Redn A, Al-Najjari Z, Tarabishi J, Chabarek S, et al. A rare case of peritoneal Xanthogranuloma in a 23-year-old woman. J Surg Case Rep. 2021;2021(2):rjaa533.

10.Krishna M, Dayal S. Xanthogranulomatus inflammatory lesion mimicker of malignancy: A clinicopathological study from rural India. North Clin Istanb. 2021;8(5):485-92.

11.Lo CY, Lorentz TG, Poon CS. Xanthogranulomatous inflammation of the sigmoid colon: a case report. Aust N Z J Surg. 1996;66(9):643-4.

12.Kinoshita H, Yamaguchi S, Sakata Y, Arii K, Mori K, Kodama R. A rare case of xanthogranuloma of the stomach masquerading as an advanced stage tumor. World J Surg Oncol. 2011;9:67.

13.Cocco AE, MacLennan GT, Lavertu P, Wasman JK. Xanthogranulomatous sialadenitis: a case report and literature review. Ear Nose Throat J. 2005;84(6):369-74.

14.Collum LM, Mullaney J. Adult limbal xanthogranuloma. Br J Ophthalmol. 1984;68(5):360-3.

15.Cho SM, Cho HR, Park YS, Chang HG. Giant Sellar Xanthogranuloma after Surgical Treatment of Symptomatic Rathke's Cleft Cyst. Brain Tumor Res Treat. 2018;6(2):82-5.

16.Kwon AH, Matsui Y, Uemura Y. Surgical procedures and histopathologic findings for patients with xanthogranulomatous cholecystitis. J Am Coll Surg. 2004;199(2):204-10.

17.Singh V, John KM, Malik A, Pareek T, Dutta V. Xanthogranulomatous appendicitis: Uncommon histological variant of a common entity. Med J Armed Forces India. 2015;71(Suppl 1):S19-21.

[DOI: 10.22088/jbums.25.1.334]