Journal of
Babol University of Medical Sciences
JBUMS
e-ISSN: 2251-7170 p-ISSN: 1561-4107

A Rare Case Report of Saddle Embolism in the Abdominal Aorta Following Acute Myocardial Infarction

A. Sardari (MD)[1], M. Mehrpooya (MD)[*1], P. Tayebi (MD)[2], V. Laleh Far (MD)[1], M. Rahmanian (MD)[1]

1.Imam Khomeini Hospital, Tehran University of Medical Sciences, Tehran, I.R.Iran.
2.Rouhani Hospital, Babol University of Medical Sciences, Babol, I.R.Iran.

Article Type
Case Report

Received:
Oct 22nd 2022
Revised:
Dec 19th 2022
Accepted:
Feb 6th 2023

ABSTRACT

Background and Objective: Systemic embolism can be one of the unfortunate side effects of left ventricular thrombus following acute heart infarction, and its timely diagnosis and treatment is very important. In this report, a patient with saddle embolism in the abdominal aorta due to the complete separation of the left ventricular thrombus following acute anterior infarction is presented.

Case Report: The patient is a 60-year-old man who referred to the emergency room complaining of severe retrosternal chest pain, nausea and cold sweats. In the ECG, he had ST segment elevation in leads V_1-V_5, and with the diagnosis of acute anterior infarction with ST segment elevation (acute anterior STEMI), he underwent primary angioplasty with stent placement (Primary PCI) on the left anterior descending artery. In transthoracic echocardiography three days later, a large thrombus was seen in the apex of the left ventricle. Seven days after stent implantation, the patient experienced severe pain and paraplegia of the lower limbs. In Doppler ultrasound, bilateral iliac artery occlusion was seen. Despite treatment with aspirin, clopidogrel, and anticoagulants, the left ventricular thrombus was embolized to the bifurcation of the abdominal aorta and caused bilateral acute ischemia of the lower limbs. The patient underwent emergency embolectomy and was discharged one week later with a stable condition and two antiplatelets and warfarin. Three months later, warfarin was discontinued.

Conclusion: According to this case report, abdominal aortic saddle embolism following acute myocardial infarction may rarely be seen. Paying attention to clinical symptoms, careful examination and quick diagnosis and treatment can improve the prognosis. In any patient with a left ventricular thrombus following an acute myocardial infarction, the possibility of systemic embolism should be considered.

Keywords: *Left Ventricular Thrombus, Acute Myocardial Infarction, Saddle Embolism, Systemic Embolism, Lower Limb Ischemia*.

Cite this article: Sardari A, Mehrpooya M, Tayebi P, Laleh Far V, Rahmanian M. A Rare Case Report of Saddle Embolism in the Abdominal Aorta Following Acute Myocardial Infarction. *Journal of Babol University of Medical Sciences*. 2023; 25(1): 188-94.

© The Author(S).
Publisher: Babol University of Medical Sciences

[*]Corresponding Author: M. Mehrpooya (MD)
Address: Imam Khomeini Hospital, Tehran University of Medical Sciences, Tehran, I.R.Iran.
Tel: +98 (21) 66939537. **E-mail:** maryammehrpooya1@gmail.com

[DOI: 10.22088/jbums.25.1.188]

Introduction

Endocardial inflammation and relative blood stasis in the acute phase of myocardial infarction probably provide a thrombogenic surface for thrombus formation in the left ventricle (1). Although the incidence of thrombus formation has decreased to a great extent with primary PCI and thrombolytic treatment, there is still a risk of thrombus formation in high-risk patients (presence of large anterior infarction with significant wall motion abnormalities and left ventricular ejection fraction), and it can cause systemic embolism (2, 3). The incidence of left ventricular wall thrombus is higher in the first two weeks after infarction, and imaging is very important in its early diagnosis and rapid treatment (4). Diagnostic methods include two-dimensional echocardiography with or without contrast and cardiac magnetic resonance imaging (CMR). The treatment of this thrombus is associated with the use of anticoagulants (5, 6). Abdominal Aortic Saddle Embolism is not common after acute myocardial infarction.

In this rare case report, a complete left ventricular thrombus embolism following an acute myocardial infarction and a large saddle embolism of the abdominal aorta, with symptoms of pain and paraplegia of the lower limbs, are presented.

Case Report

This study was approved by the ethics committee of Tehran University of Medical Sciences with code IR.TUMS.IKHC.REC.1401.331. A 60-year-old male patient with severe retrosternal chest pain radiating to the left shoulder, which started an hour before the visit, was brought to the emergency department of Imam Khomeini Hospital in Tehran. The patient's pain was accompanied by cold sweat, nausea and vomiting. The patient mentioned a history of smoking within the last 30 years. In the physical examination, heart rate was 100 beats per minute, blood pressure was 105.72 mm Hg, and respiratory rate was 16 cycles per minute. In auscultation of the heart S4 was heard and auscultation of the lungs was normal. Peripheral pulses were full and consistent. In the ECG, ST segment elevation of 4 to 5 mm was present in leads V_1 to V_5 (Figure 1).

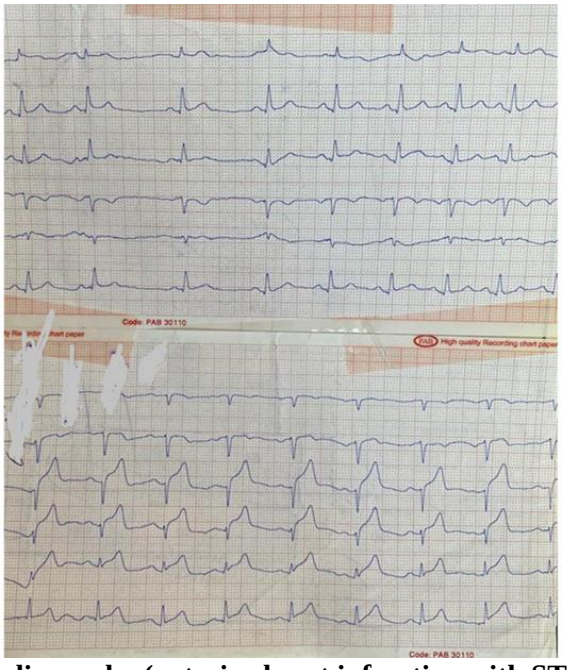

Figure 1. Electrocardiography (anterior heart infarction with ST segment elevation)

[DOI: 10.22088/jbums.25.1.188]

With the diagnosis of anterior STEMI, the patient was transferred to the catheterization department and underwent coronary angiography. Significant stenosis was seen in the proximal LAD and there was no significant stenosis in other vessels (Figure 2).

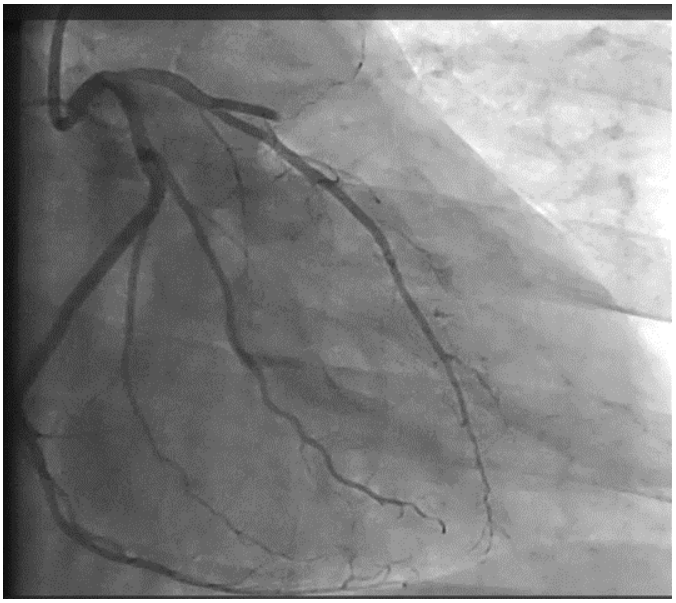

Figure 2. Angiography image

For this patient, primary PCI was performed on LAD (Firehawk stent; 3×29 and Foxtrot NC balloon 2×10), which was associated with TIMI flow III establishment with a successful outcome. The patient was treated with two antiplatelets (aspirin 80 mg and clopidogrel 75 mg daily). In the transthoracic echocardiography, which was performed on the patient's bed, the ejection fraction was 25% EF and there was no thrombus in the left ventricle. After 3 days, due to tachycardia, in order to investigate the complications of MI, the patient again underwent transthoracic echocardiography, and a fresh, semi-mobile thrombus with a size of 2×3 cm was seen in the apex of the left ventricle (Figure 3).



Figure 3. Left ventricular thrombus

[DOI: 10.22088/jbums.25.1.188]

Anticoagulant (heparin infusion at a dose of 12 units per kilogram of body weight with the aim of maintaining PTT between 50 and 70 and warfarin tablets 5 mg daily) was started. The patient was transferred to the ward with stable hemodynamics. On the seventh day of hospitalization, the patient developed severe back and lower limb pain. He was fully awake. In the examination, blood pressure was 96.55 and heart rate was 130 beats per minute. During the examination, heart sounds were heard well and there was no clear murmur. Auscultation of the lungs was clear. The lower limbs were cold and paraplegic. In the examination of the peripheral pulses, the pulses of dorsalis pedis, posterior tibial, popliteal and femoral arteries on both sides were not palpated. ECG had no dynamic changes. Considering the presence of paraplegia, neurological causes were suggested for the patient at first.

INR was equal to 1.9 in the tests, and the patient was still receiving heparin. In transthoracic echocardiography at the patient's bedside, EF=25% and there was no thrombus in the left ventricle, and therefore the possibility of complete embolization of the thrombus was raised. Doppler ultrasound of the lower limbs confirmed complete and bilateral occlusion of the common iliac and femoral arteries. Therefore, among the differential diagnoses, vascular causes were the most likely diagnosis. Emergency vascular surgery consultation was requested.

Due to the critical condition of the patient and the possibility of the loss of life of both organs, the patient did not undergo CT angiography and was transferred to the operating room with the diagnosis of acute ischemia of both organs due to the embolization of the left ventricular thrombus to the aorta. The presence of a large thrombus in the bifurcation of the abdominal aorta, which caused the complete blockage of the aorta and restricted the blood flow of the common iliac arteries on both sides, was confirmed. Transfemoral embolectomy (via Fogarty catheter) was successfully performed (Figure 4) and femoral and distal pulses of both lower limbs were palpable, and limbs were warmed. The patient was transferred to CCU and treated with heparin infusion (UFH). After adequate hemostasis, warfarin was started. After one week, the patient was discharged with a good general condition and therapeutic INR (INR=2.5) and continued use of warfarin. In the following outpatient visits, the patient had a completely stable clinical condition, and after three months, the patient's warfarin was discontinued, and aspirin and clopidogrel were continued.



Figure 4. Thrombus removed during surgery from the abdominal aorta

[DOI: 10.22088/jbums.25.1.188]

Discussion

In this report, the patient was a man who suffered from extensive immobilization of the anterior wall of the heart and thrombus formation in the left ventricle following an acute myocardial infarction, and saddle embolism of the abdominal aorta occurred after the complete detachment of the thrombus. An interesting point in this patient is the occurrence of saddle embolism of the abdominal aorta following myocardial infarction and complete embolization of the left ventricular thrombus, which is a rare complication; no evidence of a thrombus in the left ventricle was seen in the patient's echocardiography at the time of the incident. In epidemiological studies, the incidence of left ventricular thrombosis is 15% in patients with STEMI and up to 25% in patients with anterior infarction (1). Our patient also had a left ventricular thrombus following an anterior infarction. Transthoracic echocardiography is routinely used for screening, but due to its low sensitivity, the use of contrast echocardiography or CMR is mandatory in cases with high suspicion (1). Contrast echocardiography of the left ventricle has recently been recommended within 24 hours after the diagnosis of myocardial infarction (7).

Acute paraplegia can be one of the manifestations of acute aortic occlusion (8), which may initially be considered as the main finding of stroke and cause a delay in the diagnosis of vascular causes. The symptoms in our patient were also associated with paraplegia, which caused stroke to be proposed as the primary diagnosis, but after careful examination of the pulses of the lower limbs and the absence of thrombus in the left ventricle, vascular occlusion was proposed as the final diagnosis. In only one case report in 1967, saddle embolism of the aorta following acute myocardial infarction was reported, which was finally treated with a Fogarty catheter (9).

In a review article published by Ding et al. in 18 patients with abdominal aortic saddle embolism, the most common cardiac causes were atrial fibrillation and atrial flutter, followed by rheumatic and valvular diseases and congestive heart failure (10). Acute myocardial infarction is rare. In our patient, saddle embolism occurred from left ventricular thrombus following acute anterior infarction.

Heparin with a therapeutic dose and vitamin K antagonists (warfarin) are the treatment of choice for left ventricular thrombus by keeping the INR between 2 and 3. Of course, in patients who undergo primary angioplasty, the simultaneous use of aspirin and P2Y12 receptor inhibitors, along with oral anticoagulants, is mandatory. In these cases, the duration of triple therapy should be determined for each patient individually based on his/her ischemia and bleeding risk, usually between three and six months (11, 12). Recently, the use of direct oral anticoagulants (DOAC), off-label, has been used safely and effectively in patients who cannot tolerate warfarin or cannot monitor INR (7). Our patient received triple antiplatelet and anticoagulant therapy with warfarin for three months.

The interesting thing to note in this case report is the complete detachment of the thrombus and saddle embolism of the abdominal aorta, and the thrombus was not seen inside the left ventricle in the echocardiography before the patient's surgery. In the aforementioned patient, despite the use of aspirin, clopidogrel, heparin infusion and also warfarin (INR=1.8), extensive systemic embolism occurred inside the aorta. According to this study, if possible, serial transthoracic echocardiography should be performed with shorter intervals in patients with a high risk of thrombus formation (13). In addition, in any case where we see the formation of a fresh thrombus in the left ventricle after an acute heart attack, it is necessary to consider the possibility of systemic embolism, although it is not common.

[DOI: 10.22088/jbums.25.1.188]

Acknowledgment

We would like to thank the colleagues and assistants of intervention Fellowship of Cardiac Angiography and Vascular Surgery Departments of Imam Khomeini Hospital, Tehran University of Medical Sciences.

[DOI: 10.22088/jbums.25.1.188]

References

1.Ram P, Shah M, Sirinvaravong N, Lo KB, Patil S, Patel B, et al. Left ventricular thrombosis in acute anterior myocardial infarction: Evaluation of hospital mortality, thromboembolism, and bleeding. Clin Cardiol. 2018;41(10):1289-96.

2.Massussi M, Scotti A, Lip GYH, Proietti R. Left ventricular thrombosis: new perspectives on an old problem. Eur Heart J Cardiovasc Pharmacother. 2021;7(2):158-67.

3.McCarthy CP, Vaduganathan M, McCarthy KJ, Januzzi JL, Bhatt DL, McEvoy JW. Left Ventricular Thrombus After Acute Myocardial Infarction: Screening, Prevention, and Treatment. JAMA Cardiol. 2018;3(7):642-9.

4.Levine GN, McEvoy JW, Fang JC, Ibeh C, McCarthy CP, Misra A, et al. Management of Patients at Risk for and With Left Ventricular Thrombus: A Scientific Statement From the American Heart Association. Circulation. 2022;146(15):e205-e23.

5.Solheim S, Seljeflot I, Lunde K, Bjørnerheim R, Aakhus S, Forfang K, et al. Frequency of left ventricular thrombus in patients with anterior wall acute myocardial infarction treated with percutaneous coronary intervention and dual antiplatelet therapy. Am J Cardiol. 2010;106(9):1197-200.

6.Vallabhajosyula S, Kanwar S, Aung H, Cheungpasitporn W, Raphael CE, Gulati R, et al. Temporal Trends and Outcomes of Left Ventricular Aneurysm After Acute Myocardial Infarction. Am J Cardiol. 2020;133:32-8.

7.Camaj A, Fuster V, Giustino G, Bienstock SW, Sternheim D, Mehran R, et al. Left Ventricular Thrombus Following Acute Myocardial Infarction: JACC State-of-the-Art Review. J Am Coll Cardiol. 2022;79(10):1010-22.

8.Irizarry L, Wray A, Guishard K. Acute paraplegia as a presentation of aortic saddle embolism. Case Rep Emerg Med. 2016;2016:1250153.

9.Gould L, Migliorelli F. Aortic saddle embolus in acute myocardial infarction. Successful removal by a fogarty catheter technic. Am J Cardiol. 1967;19(2):231-3.

10.Ding X, Liu Y, Su Q, Hu S, Jiang J. Diagnosis and Treatment of Aortic Saddle Embolism. Ann Vasc Surg. 2019;56:124-31.

11.Lawton JS, Tamis-Holland JE, Bangalore S, Bates ER, Beckie TM, Bischoff JM, et al. 2021 ACC/AHA/SCAI guideline for coronary artery revascularization: a report of the American College of Cardiology/American Heart Association Joint Committee on Clinical Practice Guidelines. J Am Coll Cardiol. 2022;79(2):e21-e129. Available from: https://www.jacc.org/doi/10.1016/j.jacc.2021.09.006

12.Collet JP, Thiele H, Barbato E, Barthélémy O, Bauersachs J, Bhatt DL, et al. 2020 ESC Guidelines for the management of acute coronary syndromes in patients presenting without persistent ST-segment elevation. Eur Heart J. 2021;42(14):1289-367.

13.Lattuca B, Bouziri N, Kerneis M, Portal J-J, Zhou J, Hauguel-Moreau M, et al. Antithrombotic Therapy for Patients With Left Ventricular Mural Thrombus. J Am Coll Cardiol. 2020;75(14):1676-85.

[DOI: 10.22088/jbums.25.1.188]