



Reporting a Rare Case of an Ovarian Dermoid Cyst Containing Intestine

A. Mansouri (MD)¹ , M. Sadeghi (MSc)² , F. Kianifar (BSc)³ , K. Momeni (MSc)⁴ ,
M. Mahdavi Zafarghandi (MD)^{*5}

1.Department of Obstetrics and Gynecology, Faculty of Medicine, Mashhad University of Medical Sciences, Mashhad, I.R.Iran.

2.Montaserieh Dialysis and Transplant Center, Mashhad University of Medical Sciences, Mashhad, I.R.Iran.

3.Taleghani Hospital, Mashhad University of Medical Sciences, Mashhad, I.R.Iran.

4.Department of Operating Room, School of Allied Medical Sciences, Bushehr University of Medical Sciences, Bushehr, I.R.Iran.

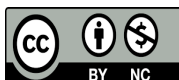
5.Imam Reza Hospital, Mashhad University of Medical Sciences, Mashhad, I.R.Iran.

***Corresponding Author: M. Mahdavi Zafarghandi (MD)**

Address: Department of Urology and Renal Transplantation, Imam Reza Hospital, Mashhad University of Medical Sciences, Mashhad, I.R.Iran.

Tel: +98 (51) 38458780. **E-mail:** drmahdavimm37@gmail.com

| Article Type | ABSTRACT |
|---|--|
| Case Report | <p>Background and Objective: Dermoid cysts or mature cystic teratoma are one of the most common benign ovarian tumors. In this study, a case of rare ovarian dermoid cyst containing hair, teeth, bone and intestine is reported.</p> <p>Case Report: The patient is a 36-year-old woman who referred with abdominal pain, nausea and change in menstruation since 2 months ago. The pain was not related to menstruation and there was no tenderness in the abdomen. Diagnosis of the mass was performed with ultrasound and MRI, and a cystic mass was detected in the right and left ovary. The patient underwent laparoscopic surgery. During the operation, the right ovary and the left ovarian cyst were removed completely and without damage. The dermoid cyst of the right ovary contained hair, teeth, bones and nails. The patient was discharged 1 day after the operation, and no complications from the surgery were reported in the follow-up. In the pathological examinations, intestinal tissue was seen in the cyst, which is important, so this case was reported.</p> <p>Conclusion: According to the results of this reported case, intestinal tissue may be present in dermoid cyst. Complete resection is recommended in these patients.</p> <p>Keywords: <i>Dermoid Cyst, Teratoma, Ovary.</i></p> |
| Received: Oct 11 st 2022 | |
| Revised: Dec 28 th 2022 | |
| Accepted: May 7 th 2023 | |
| <p>Cite this article: Mansouri A, Sadeghi M, Kianifar F, Momeni K, Mahdavi Zafarghandi M. Reporting a Rare Case of an Ovarian Dermoid Cyst Containing Intestine. <i>Journal of Babol University of Medical Sciences</i>. 2024; 26: e2.</p> | |



Introduction

Ovarian diseases and problems cause concern and apprehension in patients because these problems may affect their fertility. One of the most common ovarian problems is the presence of ovarian cysts (1). Ovarian cysts are diverse and dermoid cyst is one of the ovarian cysts (2), which is among the most common ovarian cysts in the second and third decades of life (3). A dermoid cyst is usually called a teratoma. Teratoma has a Greek origin and means monster (1). Congenital dermoid cysts are usually found in the ovaries and testicles (4) and acquired cysts can be caused by tissue manipulation and displacement during surgery and can appear in unusual places (5, 6). The symptoms of these cysts depend on the affected area and the origin of the cyst (7).

One of the most common places for dermoid cysts to occur is the face (especially the orbit), the lower back, and the ovary (4, 8). However, in some studies, the presence of dermoid cysts in the cranial cavity and temporal lobe of the brain (9, 10), spinal cord (11), eye (5), parotid gland (12), mastoid and behind the ear (4), septum and nasal sinuses (10), inside mouth (13), shoulder (4), pancreas (5) and retroperitoneum (14) have been reported. In the report of Rasekhi et al., the simultaneous presence of dermoid cyst and endometrioma in one ovary was reported (15). In another report, a ruptured dermoid cyst was reported in the ovary (16). Azami et al. reported an ovarian dermoid cyst containing *Schistosoma haematobium* infection (17).

Dermoid cysts are usually one to five centimeters in size and have a semi-solid state (5). These cysts have a growing origin and may include different elements and organs. It usually contains skin, hair, sweat glands and sebaceous glands and rarely bones, teeth, nails, cartilage, bronchial mucus, thyroid and intestines have been seen in it (1, 2, 7). The ovary is one of the most common organs in which dermoid cysts have been seen, and in general, 20-50% of ovarian masses are dermoid cysts (2, 18). The common method of treating dermoid cysts is the complete removal of symptomatic cysts by performing surgery, and satisfactory results have been found for these patients (13). However, recurrence of dermoid cysts has been observed in 2% of patients (6); the cyst must be carefully and completely removed during surgery because incomplete removal of the cyst and its rupture will lead to recurrence of the cyst (4, 9).

In this article, a rare case of ovarian dermoid cyst containing teeth, intestines and bones is reported. Because this case was rare in terms of pathology and content, this report can be useful as an experience for colleagues in similar cases.

Case Report

This case report was approved by the ethics committee of Mashhad University of Medical Sciences with the code IR.MUMS.REC.1401.268. The patient was a 36-year-old woman who referred to Mehr Hospital in Mashhad with symptoms of nausea, abdominal pain and change in menstruation since 2 months ago. The pain was not related to menstruation, and there was no sensitivity to touch (tenderness) during abdominal examination. The patient had a history of caesarean section and the scar was obvious on the abdomen. In the performed ultrasound, the uterus with dimensions of 80×25×45 mm with normal

myometrial echo was seen in the midline position. Myoma was not observed. The cervix had a normal length and appearance. The thickness of the two layers of endometrium was 5.5 mm. Endometrial echo was normal. Abnormal accumulation of fluid or abnormal finding in the uterus was not observed. A multiloculated cystic mass measuring 70×40 mm was seen in the left posterolateral part of the pelvis with several thin septa, which seems to be a left ovary measuring 16×36 mm attached to its surface. An ovarian mass measuring 56×37 mm was seen in the right lateral part of the pelvis containing a cystic part with a diameter of 20 mm. Other parts were occupied by fat-like material. Teratodermoid and hemorrhagic cyst or inclusion bodies are differential diagnoses. Ultrasound did not report any problems in other abdominal and pelvic organs (Figure 1).

In the MRI of the pelvis, the uterus is seen with a normal size and signal. The endometrial line is 4 mm with a normal signal. Endocervical canal and cervical stroma have normal signal. A fat containing multi-ring cystic mass (diameter: 45×57×60 mm) is seen in the right ovary, the signal of which is characteristic of a dermoid tumor. Another multi-walled solid cystic mass with a diameter of 52×38×34 mm is seen in the left ovary. There is a reinforcing element (12×15 mm) inside this cystic mass in favor of a solid element. Borderline ovarian tumor is suggested. The wall of the rectum and vagina looks normal. Lymphadenopathy is not seen in the pelvic cavities.

After preoperative care and diagnostic tests, the patient entered the operating room for laparoscopy. The fallopian tube and ovary on the right side were removed due to severe adhesion, and the right and left dermoid cysts were also completely removed. After initial investigations, the presence of hair, teeth, bones and nails in the right dermoid cyst was evident (Figure 2).

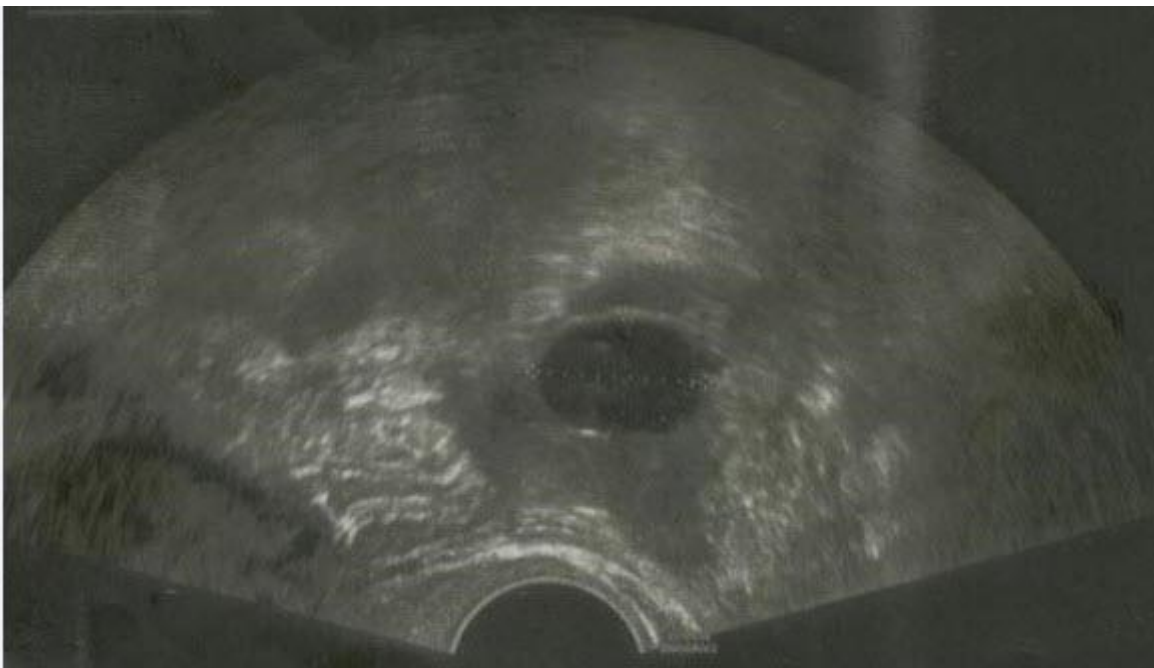


Figure 1. Ultrasound of the patient

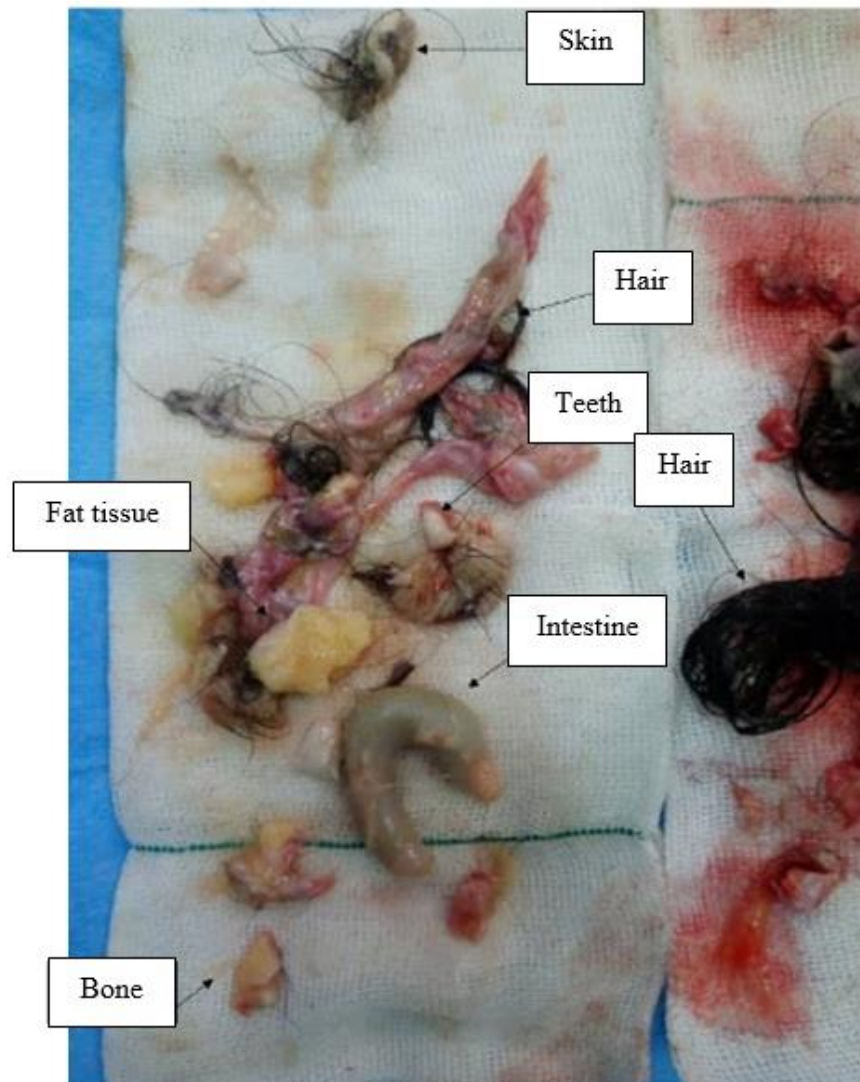


Figure 2. Presence of hair, teeth, bones and nails in removed dermoid cyst

The removed tissues were sent separately to pathology for further investigations. In the pathology results, it was reported regarding the sample sent from the right ovarian cyst that, in addition to the above cases, intestinal tissue was also present in the dermoid cyst. In hematoxylin and eosin staining, the intestinal wall is observed with a mucous coating consisting of cylindrical cells with a single layer of permeable mucin and normal mucus secretion without dysplasia and submucosa without clear inflammation (Figure 3). Mature cystic teratoma was also evident in the left side cyst sample. Finally, after passing the recovery period, the patient was discharged from the hospital one day after the operation. In the follow-up two months after the operation, no complications were reported.

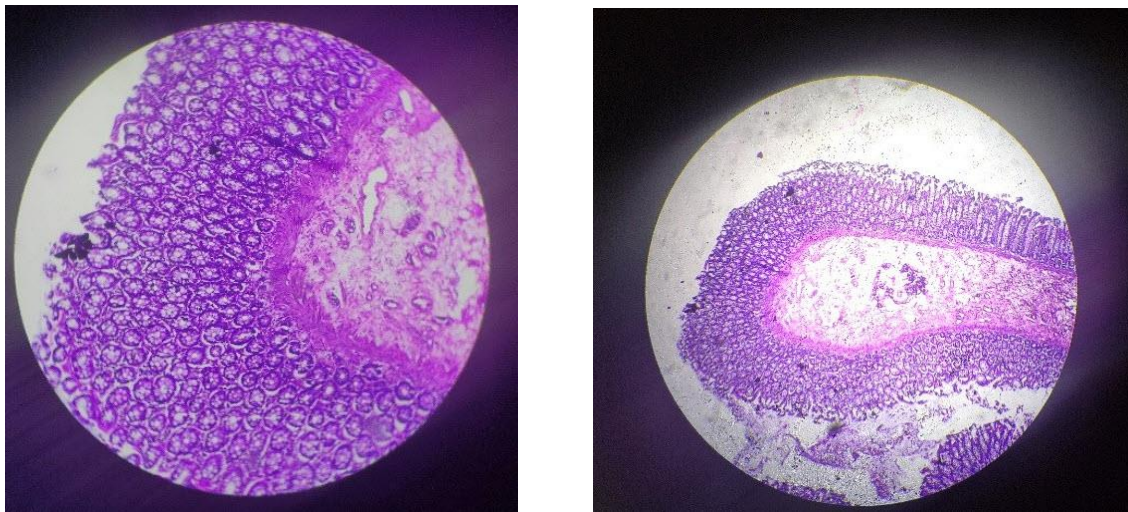


Figure 3. Staining of ovarian cystic tissue under the microscope

Discussion

The presence of intestinal tissue in a dermoid cyst is very rare. In this study, bilateral dermoid cyst of the ovaries was reported, which contained hair, nail, bone and intestinal tissue. These cysts usually grow slowly and usually do not exceed 5 cm in size (5). However, in a rare case, Pradhan et al. reported a 40 cm dermoid cyst (6). If the dermoid cyst enlarges, the possibility of pain, palpation and detection of the cyst increases (18). In this case, the volume of the cyst was not very large, but the patient referred with abdominal pain. Ovarian dermoid cysts contain various elements and tissues, and hair is common in dermoid cysts (18). In this study, in addition to a lot of hair, there were also nails, teeth, and intestinal tissue; intestinal tissue is rarely reported. Ovarian dermoid cyst is usually unilateral and mostly affects the right side (18). In this study, the dermoid cyst was bilateral, but the right cyst contained hair, nail, bone and intestinal tissue.

Azami et al. reported a case of ovarian dermoid cyst in a 45-year-old woman with symptoms of abdominal pain and fever that contained *Schistosoma haematobium* infection, which was a rare event (17). In our report, dermoid cyst did not have any infection. In another report, a 35-year-old woman complained of abdominal pain for 10 months. She was examined and a 5×10 cm mass was detected in the right ovary by ultrasound. The diagnosed dermoid cyst was removed laparoscopically (19). In the report of Salehpour et al., a dermoid cyst containing a structure similar to the lower jaw along with teeth was mentioned in a teenage girl, which was removed by laparoscopy (20). In our study, the cyst contained bone and nail. The cyst was associated with severe adhesions of the ovary and the right fallopian tube, which were removed along with the removal of the cyst, the ovary and the right fallopian tube. In another report, the presence of teeth and parts of jaw bone in ovarian dermoid cyst has been reported (21).

Dermoid cysts usually do not have specific symptoms and are detected incidentally during examinations and tests (18). However, in this study, the patient complained of abdominal pain and referred to the hospital with this symptom. One of the problems of dermoid cyst in the ovary is ovarian torsion, and it is one of the surgical emergencies of women, which manifests itself with symptoms such as pain, anorexia,

nausea, and vomiting (1, 22). Ovarian dermoid cysts may bleed and become problematic (1). There was no ovarian torsion or bleeding in this study. In some cases, ovarian dermoid cyst malignancy has been reported (4). In this study and after the pathology examinations, there was no sign of malignancy in the removed cyst.

Hair, nails and bones have been reported in dermoid cysts. However, the presence of intestinal tissue in dermoid cyst is unusual. The treatment of these patients is the complete removal of the dermoid cyst with surgery. Dissemination of cyst contents in the operation field and incomplete resection of the cyst are among the things that will cause the recurrence of the cyst. Therefore, this patient underwent complete resection of the mass. Complete resection is recommended in these patients. Considering the rarity of the contents of this dermoid cyst and raising it in similar cases, it will be a useful experience for colleagues.

Acknowledgment

Hereby, we would like to thank the Vice-Chancellor of Research and Technology of Mashhad University of Medical Sciences for supporting the research, as well as Dr. Amin Dalili and Ms. Sara Mohammadi who helped the research team in preparing and editing this article, and the patient and her respected family who provided information at all stages of the study and helped us with the implementation of this study.

References

- 1.Njoku C, Oriji PC, Afolabi S, Kuete E. Bilateral Dermoid Cyst of the Ovary: A Case Report. *Yenagoa Med J*. 2020;2(1):190-2.
- 2.Mansouri A, Kamali N, Javdan Mehr M, Sadeghi M. Retrorectal (Pre Sacral) Dermoid Cyst: a case report. *Iran J Obstet Gynecol Infertile*. 2019;22(4):97-102. [In Persian]
- 3.Sel G. Case Report of Bilateral Dermoid Cyst Containing Tooth and Bone with Unilateral Ovarian Torsion. *Med J Wes Black Sea*. 2018;2(2):182-5.
- 4.Henares Chavarino AA, Bérniz Laborda CP, Estiragués Cerdá M, Magallón AR, Vicente Ruiz M, Bazán Álvarez A. Retroauricular dermoid cyst associated with Gorlin syndrome. A case report. *J Pediatr Surg Case Rep*. 2022;84:102373.
- 5.Chang W, Ding Y, Yan Y, Wei N, Li H, Zhang Z, et al. Dermoid cyst with a congenital sinus tract over the left sternoclavicular joint: a case report and literature review. *J Int Med Res*. 2020;48(6):300060520934984.
- 6.Pradhan P, Thapa M. Dermoid Cyst and its bizarre presentation. *J Nepal Med Assoc*. 2014;52(194):837-44.
- 7.Moin T, Ramsay B, Mckeown B, Astall E, Tapuria N. Ruptured ovarian dermoid cyst - an unusual cause for peritonitis in pregnancy: a case report. *JRSM Open*. 2020;11(6):2054270417744502.
- 8.Tanwir A, Malik N, Javed G, Idrees R. Dermoid cyst with no intracranial extension: A case report and literature review. *Surg Neurol Int*. 2019;10:25.
- 9.Hatano K, Fujimoto A, Inenaga C, Otsuki Y, Enoki H, Okanishi T. Non-Ruptured Temporal Lobe Dermoid Cyst Concomitant with Focal Cortical Dysplasia Causing Temporal Lobe Epilepsy-A Case Report and Literature Review. *Brain Sci*. 2021;11(9):1136.
- 10.Lee DH, Yoon TM, Lee JK, Lim SC. Dermoid cyst of nasal septum in an adult patient: A case report. *Medicine (Baltimore)*. 2018;97(45):e13028.
- 11.Gatam L, Merthana PE. A rare case of intramedullary spinal dermoid cyst in adult: A case report. *Int J Surg Case Rep*. 2020;73:52-7.
- 12.Keane A, Warrick J, Andrews G, Choi KY. Pediatric dermoid cyst of the parotid: Case report and review of the literature. *Otolaryng Case Rep*. 2021;18:100258.
- 13.Şimşek-Kaya G, Özbudak İH, Kader D. Coexisting sublingual dermoid cyst and heterotopic gastrointestinal cyst: Case report. *J Clin Exp Dent*. 2018;10(2):e196-9.
- 14.Ebrahimi A, Pourgholam F, Rostami M, Abaszadeh F, Gholamveisi B, Sadeghi M. Retroperitoneal Dermoid Cyst Between the Rectum and Vagina: A Case Report. *J Obstet Gynecol Cancer Res*. 2019;4(4):155-9.
- 15.Rasekhi M, Zaeim Yekeh MA. Simultaneous appearance of Dermoid cyst and Endometrioma in one ovary. *Sarem J Med Res*. 2020;5(2):82-5. [In Persian]
- 16.Mazhoud I, Skhiri W, Hafsa C, Toumi D, Maatouk M, Ben Salem A. Ruptured mature ovarian teratoma: A case report. *Int J Surg Case Rep*. 2023;102:107788.
- 17.Azami MA, Elalami I, Siati A, Lamalmi N. An unusual presentation of ovarian dermoid cyst: a case report and review of literature. *Obstet Gynecol Sci*. 2018;61(4):529-32.
- 18.Hamza M, Yasmeen T, Nadeem IA, Fatima N, Fatima S, Huzaifa M. Ovarian dermoid cyst presenting with unusual complaint of hair coming out of the anal orifice - A case report. *J Pak Med Assoc*. 2020;70(3):534-6.
- 19.Mishra TS, Jena SK, Kumari S, Purkait S, Ayyanar P, Nayak P. Cecal dermoid masquerading dermoid cyst of ovary: a case report and review of the literature. *J Med Case Rep*. 2021;15(1):38.
- 20.Salehpour S, Akbari Sene A. Super infection of an ovarian dermoid cyst with actinomyces in an infertile woman. *Int J Fertil Steril*. 2013;7(2):134-7.

- 21.Kostylenko YP, Starchenko II, Prylutsky OK. [Structure of teeth in mature ovarian teratoma]. Arkh Patol. 2015;77(2):28-31. [Russian]
- 22.Malmusi S, Airoud M, Pellegrini R, Galassi MC. A Case Report of Premature Ovarian Failure by Asynchronous Bilateral Ovarian Torsion with Dermoid Cyst. Ann Obstet Gynecol. 2021;4(1):1027.