Journal of
Babol University of Medical Sciences
JBUMS
e-ISSN: 2251-7170 p-ISSN: 1561-4107

Vitamin D Levels and Risk of Retinopathy in Patients with Diabetes Mellitus

S. A. Rasoulinejad (MD)[1], A. Akbari (PhD)[*2]

1.Department of Ophthalmology, School of Medicine, Babol University of Medical Sciences, Babol, IR.Iran.

2.Department of Physiology, School of Veterinary Medicine, Shiraz University, Shiraz, I.R.Iran.

Article Type

Review Paper

Received:
May 26th 2022
Revised:
Jun 14th 2022
Accepted:
Jun 27th 2022

ABSTRACT

Background and Objective: Epidemiological data show a strong correlation between vitamin D deficiency and the incidence of diabetes mellitus. Many studies have reported hypovitaminosis D in patients with diabetic retinopathy, and it is possible that the deficiency of this vitamin plays a role in the pathogenesis of this diabetic complication. Therefore, the aim of this study is to investigate the serum levels of vitamin D in patients with diabetic retinopathy and its relationship with the prevalence of diabetic retinopathy.

Methods: In this review article, we searched Scopus, Google Scholar, and PubMed databases using the keywords vitamin D deficiency, serum vitamin D levels, vitamin D supplement, diabetes, and diabetic retinopathy. No time limit was considered for the search. Articles written in English were included in this study. Original and complete articles in English about vitamin D deficiency, diabetes and retinopathy were reviewed. Review articles and animal studies were excluded from this study. The data obtained from these findings were extracted and evaluated by two reviewers.

Findings: In this study, out of 52 studies found, 15 articles were reviewed according to the inclusion criteria. The results showed that vitamin D deficiency is very common in people with diabetes and diabetic retinopathy and there is a strong inverse relationship between vitamin D deficiency and diabetic retinopathy. In addition, the use of its supplements is also necessary to prevent the progression of diabetic retinopathy.

Conclusion: The results of this study suggest that the reduction of vitamin D serum levels is very common in patients with diabetic retinopathy and can be one of the risk factors for developing retinopathy. Its plasma level can have a high diagnostic value in order to prevent and control the onset of this complication.

Keywords: *Vitamin D Deficiency, Vitamin D Serum Level, Vitamin D Supplement, Diabetes and Diabetic Retinopathy.*

Cite this article: Rasoulinejad SA, Akbari A. Vitamin D Levels and Risk of Retinopathy in Patients with Diabetes Mellitus. *Journal of Babol University of Medical Sciences*. 2022; 24(1): 189-98.

© The Author(S).
Publisher: Babol University of Medical Sciences

[*]Corresponding Author: A. Akbari (PhD)
Address: Department of Physiology, School of Veterinary Medicine, Shiraz University, Shiraz, I.R.Iran.
Tel: +98 (71) 36138757. **E-mail:** akbariabolfazl@gmail.com

[DOR: 20.1001.1.15614107.1401.24.1.24.0]
[DOI: 10.22088/jbums.24.1.189]

Introduction

Diabetes Mellitus is a heterogeneous endocrine and metabolic disease characterized by chronic hyperglycemia and is often accompanied by glucosuria, dyslipidemia, polyuria, and other metabolic disorders. This disease is caused by low insulin levels or its function or both of these factors and usually leads to specific changes in cellular metabolism and morphology in organs such as the kidney, retina and blood vessels (1). Vascular complications of diabetes are classically known as microvascular complications (resulting from damage to small blood vessels) and macrovascular complications (resulting from damage to larger blood vessels). Microvascular damage includes retinopathy, nephropathy, cardiomyopathy, and neuropathy. An analysis of data from 35 population-based studies shows that 93 million people suffer from diabetic retinopathy worldwide, of which 17 million or 18%, have proliferative diabetic retinopathy (2). Diabetic retinopathy is one of the most common microvascular complications, which is the main cause of blindness in middle-aged and old people with diabetes, and the most common cause of vision loss in patients with diabetic retinopathy is diabetic macular edema (3). Hyperglycemia, inflammation, innate immune defect, retinal neurodegeneration, hypertension, and lack of certain nutrients, including vitamins such as vitamin D and essential metals such as zinc, are the main risk factors for diabetic retinopathy (4, 5).

Much epidemiological evidence shows the role of vitamin D deficiency in the prevalence of diabetes and diabetic retinopathy (6). According to a study, the prevalence of vitamin D deficiency was unexpectedly high in all cities of Iran; 72.1% of men and 75.1% of women suffered from various degrees of vitamin D deficiency (7). Vitamin D has a receptor on all insulin target tissues and its deficiency can affect all actions of this hormone. This vitamin directly increases insulin sensitivity by stimulating insulin receptor expression and activating peroxisome proliferators-activated receptor γ (PPARγ), the regulator of fatty acid metabolism in insulin target organs (8). These actions increase glucose uptake from the bloodstream and have a functional role in maintaining glucose tolerance (9). However, despite extensive studies in this field, the relationship between vitamin D deficiency and diabetic retinopathy is not completely clear.

Current treatment strategies for diabetic retinopathy and management of complications of vascular damage include intravitreal drug injection, laser, and retina surgery. Currently, intravitreal injection of anti-VEGF drugs (VEGF= Vascular Endothelial Growth Factor) is the main treatment for early and advanced stages of diabetic retinopathy (10), whereas laser therapy only provides stabilization of visual acuity (11). However, according to the Diabetic Retinopathy Clinical Research Network, optimal vision improvement is achieved in only 29% of patients within two years of anti-VEGF therapy (12). Inadequate response to anti-VEGF treatment indicates the involvement of other molecular pathways during the pathogenesis of diabetic retinopathy (11, 13). In addition, the use of anti-VEGF drugs is limited due to the need for frequent injections, financial burden, and poor patient compliance (11, 14). Currently, the optimization of current treatment methods regarding the number, dose and duration of injections as well as combined and auxiliary treatment strategies to improve the quality of life of these patients is of great importance (5, 16, 15). Therefore, studying the underlying mechanisms of diabetic retinopathy can provide potential targets for the development of current treatments and provide alternatives to them as new therapeutic strategies as well as using adjuvant therapy (5, 11, 17, 20). It seems that the use of adjuvant therapy based on nutritional supplements such as vitamin D can be a suitable solution for the prevention and treatment of diabetes and especially diabetic retinopathy (5). Therefore, the present study was conducted to investigate the status of vitamin D in patients with diabetes and diabetic retinopathy and its relationship with the prevalence of diabetic retinopathy.

[DOR: 20.1001.1.15614107.1401.24.1.24.0]
[DOI: 10.22088/jbums.24.1.189]

Methods

In this review article, the keywords vitamin D deficiency, serum vitamin D levels, vitamin D supplement, diabetes and diabetic retinopathy were searched in Scopus, Google Scholar and PubMed databases. There was no time limit for the search. Articles written in English were included in this study. Inclusion criteria were vitamin D deficiency, diabetes and retinopathy, English language, original articles and complete articles. Only human studies have reported serum vitamin D levels in patients with diabetes. Animal studies, reviews, letters, commentaries, clinical groups without proper control, and case studies were excluded. Regarding duplicate reports, only the article with more details was included in the study. Data were extracted and analyzed independently by two researchers and a reviewer based on a predefined protocol (including: first author and published year, country, type of study, age of participants, sample size in control group and in patients, study population and serum vitamin D levels in control group and in patients). All the obtained data were studied and evaluated by two independent researchers. Vitamin D units were converted to millimoles per liter using the unit conversion calculator (http://unitslab.com/node/84) if reported in other units.

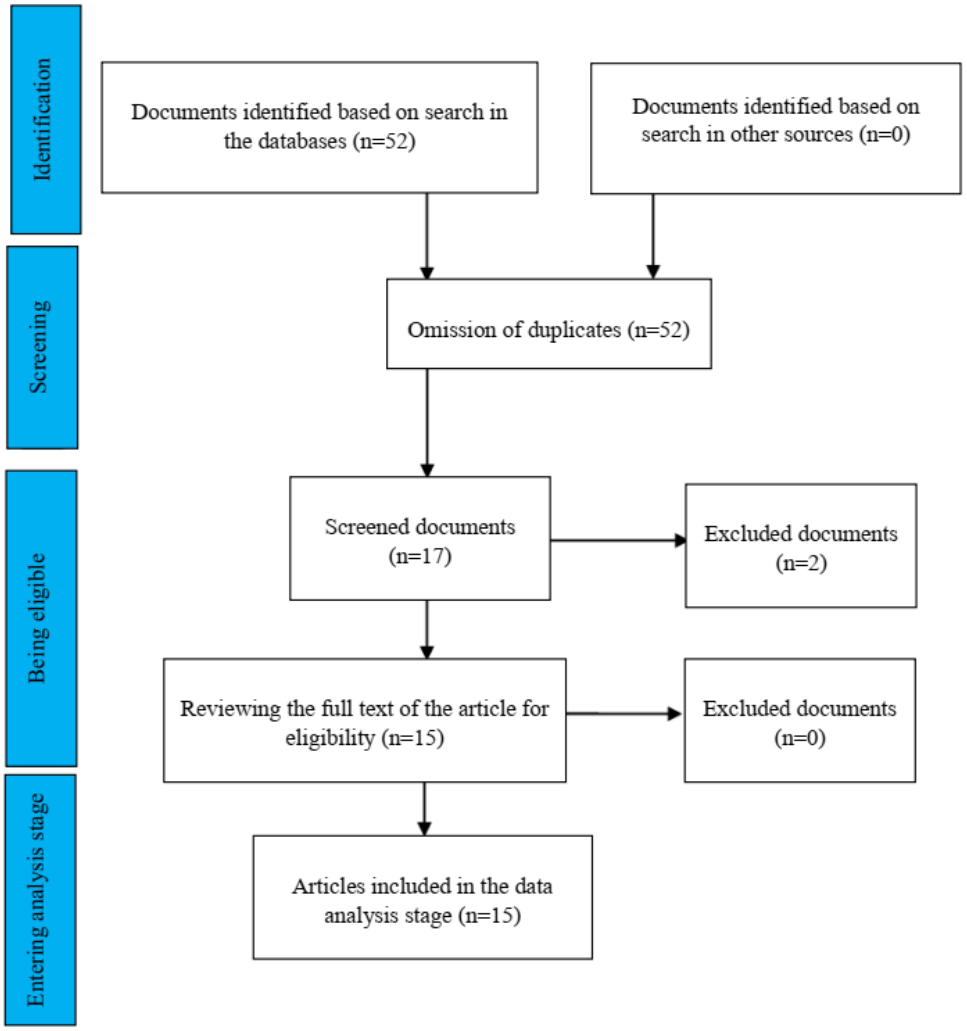

Figure 1. PRISMA flow diagram for selected studies

[DOR: 20.1001.1.15614107.1401.24.1.24.0]
[DOI: 10.22088/jbums.24.1.189]

Results

In this study, 52 articles were found by initial search based on the keywords vitamin D deficiency, serum vitamin D levels, vitamin D supplement, diabetes and diabetic retinopathy in Scopus, Google Scholar and PubMed databases. About 17 articles were selected by evaluating the title. Then, evaluation was done based on access to the full text of the article and English language, and 15 articles remained. Articles that were not fully accessible were obtained by sending email to the corresponding author (Table 1). The evaluation of the results of these studies showed that vitamin D deficiency is very common in people with diabetic retinopathy and its deficiency can be one of its risk factors. In addition, evaluation of the data of these studies (Table 1) showed that most of them confirm that the probability of developing diabetic retinopathy increases with a decrease in vitamin D concentration below 15-20 ng/ml. In addition, the use of vitamin D supplements in patients with diabetes and diabetic retinopathy seems to be necessary as a therapeutic strategy.

Table 1. Features of clinical studies conducted regarding the relationship between vitamin D deficiency and the prevalence of diabetic retinopathy (21-35)

Serum vitamin D levels (ng/ml) Mean±SD		Group		Type of study	Year	Country	Study
Control	Diabetic retinopathy	Control	Diabetic retinopathy				
11.9±2.1	12.6±2.1	20	66	cross-sectional	2000	Turkey	(21)
15.61±9.4	12.6±4.61	-	30	cross-sectional	2020	Iran	(22)
13.7±2.1	11.9±2.2	-	-	cross-sectional	2018	India	(23)
16.9±1.2	16.7±1.2	99	164	cross-sectional	2015	India	(24)
21.4±11.8	19.7±8.4	112	557	Retrospective	2015	Turkey	(25)
17.5±3.6	15.7±7.3	51	581	cross-sectional	2006	Japan	(26)
24.3±10.3	22.3±10.5	47	82	cross-sectional	2012	United states	(27)
21.8±13.7	12.3±5.5	-	136	cross-sectional	2013	Lebanon	(28)
27.1±1.86	19.0±1.46	130	28	cross-sectional	2014	India	(29)
18.9±7.1	16.6±5.8	625	895	cross-sectional	2014	China	(30)
18.7±3.4	18.3±6.6	16693	2553	cross-sectional	2014	Korea	(31)
15.2±4.5	10.0±5.9	-	150	cross-sectional	2014	Kongo	(32)
20.5±8.1	19.2±10.1	144	139	cross-sectional	2015	Spain	(33)
10.3±9.4	9.2±7.1	153	82	cross-sectional	2015	Iran	(34)
18.5±7.45	23.25±8.25	490	225	cross-sectional	2015	Italy	(35)

[DOR: 20.1001.1.15614107.1401.24.1.24.0]
[DOI: 10.22088/jbums.24.1.189]

Discussion

The results of evaluating clinical studies in this research showed that there is a strong inverse relationship between serum vitamin D levels and the prevalence of diabetes. In addition, the analysis of the clinical findings of this study demonstrated the relationship between vitamin D deficiency and the incidence of diabetes, especially diabetic retinopathy. The results of clinical studies reveal that vitamin D deficiency is associated with parameters that indicate cardiovascular damage such as endothelial dysfunction (36). Other studies show that vitamin D plays an essential role in the protection and regeneration of blood vessels (37) and the normalization of its level can significantly improve the indicators of vascular function (38).

Aksoy et al. found an inverse relationship between the severity of diabetic retinopathy and vitamin D concentration. They showed that the lowest concentration of vitamin D is in diabetic patients with diabetic retinopathy and the highest in diabetic patients without diabetic retinopathy (39). Patients with diabetes have low levels of 25-hydroxyvitamin D, which may be due to impaired hepatic and renal vitamin D metabolism. In addition, it is consistently reported that circulating levels of 25-hydroxyvitamin D are reduced in patients with diabetes. It is also assumed that the decrease in the level of 25-hydroxyvitamin D contributes to the pathophysiology of skeletal fragility in diabetic patients (40).

In a cross-sectional study on more than 500 patients, it was shown that vitamin D deficiency is associated with an increased prevalence of diabetic retinopathy (41). Likewise, in a retrospective cross-sectional study on approximately 1000 patients, it was shown that the severity of diabetic retinopathy was higher in patients with vitamin D deficiency compared to patients with sufficient vitamin D levels (42). In addition, a meta-analysis showed that type 2 diabetes patients with vitamin D deficiency have an increased risk of developing diabetic retinopathy (43). Another case was an observational study on more than 10,000 participants in fourteen studies, which showed a significant relationship between vitamin D deficiency and diabetic retinopathy (44). In addition, many cross-sectional studies in different populations such as Italians, Japanese, Chinese, and African Americans showed that vitamin D deficiency is associated with the risk of developing diabetic retinopathy (45, 46). The high reproducibility of these findings in different geographical and ethnic situations indicates a strong relationship between vitamin D deficiency and diabetes and diabetic retinopathy. The role of vitamin D supplements on the improvement of diabetes and its vascular complications may be exerted through several independent or interrelated mechanisms. These mechanisms include improving glucose homeostasis, inhibiting inflammation and oxidative damage, and preventing macro and microvascular complications through vascular protection mechanisms. Recently, a meta-analysis of randomized controlled trials showed that vitamin D supplements in type 2 diabetes patients can improve serum HbA1c levels, insulin resistance, and insulin secretion in a short-term intervention (45). In another meta-analysis of the same type of studies, the favorable effect of vitamin D consumption on fasting glucose in patients with diabetes was shown. Some studies focused mainly on biochemical, immune, and inflammatory markers of vascular damage in patients with diabetic retinopathy, showing the effect of vitamin D supplements on these parameters (47).

The two markers YKL-40 and MCP-1 play an important role in diabetes and microvascular complications. Chitinase-3-like protein 1 (CHI3L1), also known as YKL-40, is a secreted glycoprotein that is approximately 40 kDa in size. The name YKL-40 is derived from the three N-terminal amino acids present in the secreted form and its molecular mass. In a 12-week randomized controlled trial, 48 patients with type 2 diabetes were treated with vitamin D supplements and placebo. The results of this study showed that vitamin D supplements reduce serum YKL-40 and MCP-1 levels. In addition, the levels of IL-6, fasting insulin and HOMA-IR in the intervention group showed a significant decrease (48). Al Mheid et al. showed that vitamin D deficiency status is associated with RHI (Reactive Hyperemia Index), an indicator of vascular function. They showed a significant increase in RHI in patients with vitamin D deficiency after 6 months of

[DOR: 20.1001.1.15614107.1401.24.1.24.0]
[DOI: 10.22088/jbums.24.1.189]

taking oral vitamin D supplements (38). In addition, the relationship between vitamin D and blood vessel function in diabetic patients has been described (49).

Another objective that we pursued in this study was to evaluate the total amount of 25-hydroxyvitamin D in diabetic retinopathy in order to estimate the amount of supplementation required for this vitamin. Evidence shows that vitamin D deficiency is a modifiable risk factor for diabetic retinopathy. Assessment of vitamin D levels is done by measuring the level of 25-dihydroxyvitamin D. Adequate levels of this vitamin can be obtained from all sources (sunlight, diet and supplements). Studies suggest that people with higher levels of 25-hydroxyvitamin D have a lower risk of developing retinopathy (50). They have also made this connection by checking blood pressure or controlling blood sugar (18, 51). Furthermore, in a cross-sectional study, He et al. showed that vitamin D deficiency below 15.57 ng/ml doubles the prevalence of diabetes retinopathy (30). In addition, the data from the studies conducted in our country alarmingly show that the levels of vitamin D in people with diabetic retinopathy are very low, and in addition to being a warning for the lack of this vitamin in these people, this finding indicates the important role of vitamin D in the pathogenesis of this disease (22, 34). Studies agree that the risk of diabetic retinopathy increases with a decrease in vitamin D concentration below 20 ng/ml (21-35).

According to these explanations, it can be suggested that the evaluation of the total amount of 25-hydroxyvitamin D can be considered as an indicator for the possibility of developing and preventing diabetic retinopathy. However, the definition of vitamin D deficiency is an obvious subject and has been agreed upon by many researchers and experts in clinical medicine and nutrition. There is a fairly strong consensus among experts, which shows that 25-hydroxyvitamin D levels below 12 ng/ml (30 nmol/L) indicate a deficiency of this vitamin in healthy individuals, and levels above 30 ng/ml (75 nmol/L) indicate fully adequate plasma levels of this vitamin. However, the clinical meaning of the difference between 12 and 30 ng/ml with a sufficient threshold (20 ng/ml) of serum or a level higher than 30 ng/ml is not yet clear according to different guidelines. These discrepancies are at least partly due to the lack of standardization in the methods of measuring 25-hydroxyvitamin D. Considering a threshold greater than 20 ng/ml, approximately one-third of the world's population and approximately 40% of the European population suffer from vitamin D deficiency, while severe deficiency of this vitamin, defined as a serum level of less than 12 ng/ml, is visible in approximately 7% of the global population (52).

The evaluated clinical and pathophysiological aspects show that vitamin D deficiency plays a role in the onset and development of diabetic retinopathy. Since vitamin D deficiency is widespread throughout the world and strongly affects the onset and development of diabetic retinopathy, determining the plasma level of this vitamin has diagnostic and preventive value not only in diabetic retinopathy but also in other diabetic vascular diseases.

[DOR: 20.1001.1.15614107.1401.24.1.24.0]
[DOI: 10.22088/jbums.24.1.189]

Acknowledgment

We would like to thank the Vice Chancellor for Research in Shiraz University and the Vice Chancellor for Research and Technology in Babol University of Medical Sciences.

References

1.Mathers CD, Loncar D. Projections of global mortality and burden of disease from 2002 to 2030. PLoS Med. 2006;3(11):e442.

2.Zheng Y, He M, Congdon N. The worldwide epidemic of diabetic retinopathy. Indian J Ophthalmol. 2012;60(5):428-31.

3.Kasiri A, Farrahi F, Feghhi M, Sadeghi B, Hedayati H, Rasoulinejad SA. Comparison of Intravitreal Bevacizumab (Avastin) With Triamcinolone for Treatment of Diffused Diabetic Macular Edema: a Prospective Randomized Study. Indo Am J Pharm Sci. 2017;4(11):4483-91.

4.Rasoulinejad SA, Akbari A. Association between iron and zinc deficiency and retinopathy of premature: A Narrative Review. Caspian J Pediatrs. 2021;7(2):566-75.

5.Rasoulinejad SA, Akbari A, Nasiri K. Interaction of miR-146a-5p with oxidative stress and inflammation in complications of type 2 diabetes mellitus in male rats: Anti-oxidant and anti-inflammatory protection strategies in type 2 diabetic retinopathy. Iran J Basic Med Sci. 2021;24(8):1078-86.

6.Ozfirat Z, Chowdhury TA. Vitamin D deficiency and type 2 diabetes. Postgrad Med J. 2010;86(1011):18-25.

7.Zahedi Rad M, Shariatzadeh N, Neyestani TR, Kalayi A, Gharavi A, Bazhan M. Comparing vitamin D deficiency prevalence in Iranian diabetics and healthy subjects: a pilot study. Iran J Nutr Sci Food Technol. 2013;7(5):505-10. [In Persian]

8.Park S, Kim DS, Kang S. Vitamin D deficiency impairs glucose-stimulated insulin secretion and increases insulin resistance by reducing PPAR-γ expression in nonobese Type 2 diabetic rats. J Nutr Biochem. 2016;27:257-65.

9.Al-Shoumer KA, Al-Essa TM. Is there a relationship between vitamin D with insulin resistance and diabetes mellitus?. World J Diabetes. 2015;6(8):1057-64.

10.Rasoulinejad SA, Hajian-Tilaki K, Mehdipour E. Associated factors of diabetic retinopathy in patients that referred to teaching hospitals in Babol. Caspian J Intern Med. 2015;6(4):224-8.

11.Semeraro F, Morescalchi F, Cancarini A, Russo A, Rezzola S, Costagliola C. Diabetic retinopathy, a vascular and inflammatory disease: therapeutic implications. Diabetes Metab. 2019;45(6):517-27.

12.Gonzalez VH, Campbell J, Holekamp NM, Kiss S, Loewenstein A, Augustin AJ, et al. Early and Long-Term Responses to Anti-Vascular Endothelial Growth Factor Therapy in Diabetic Macular Edema: Analysis of Protocol I Data. Am J Ophthalmol. 2016;172:72-9.

13.Rasoulinejad SA. Association of Microalbuminuria and Bevacizumab Therapy Outcomes in Diabetic Retinopathy Patients. Nephro-Urol Mon. 2022;14(1):e118972.

14.Rasoulinejad SA, Karkhah A, Paniri A, Saleki K, Pirzadeh M, Nouri HR. Contribution of inflammasome complex in inflammatory-related eye disorders and its implications for anti-inflammasome therapy. Immunopharmacol Immunotoxicol. 2020;42(5):400-7.

15.Rasoulinejad SA, Maroufi F. A review of DNA and histone methylation alterations in the new era of diagnosis and treatment of retinal diseases. Curr Mol Med. 2021;21(8):607-19.

16.Rasoulinejad SA, Sarreshtehdari N, Mafi AR. The crosstalk between VEGF signaling pathway and long non-coding RNAs in neovascular retinal diseases: Implications for anti-VEGF therapy. Gene Rep. 2022;27:101541.

17.Semeraro F, Cancarini A, dell'Omo R, Rezzola S, Romano MR, Costagliola C. Diabetic retinopathy: vascular and inflammatory disease. J Diabetes Res. 2015;2015:582060.

[DOR: 20.1001.1.15614107.1401.24.1.24.0]
[DOI: 10.22088/jbums.24.1.189]

18.Wang W, Lo AC. Diabetic retinopathy: pathophysiology and treatments. Int J Mol Sci. 2018;19(6):1816.
19.Song J, VanBuskirk JA, Merbs SL. Regulation of Opsin Gene Expression by DNA Methylation and Histone Acetylation. Int J Mol Sci. 2022;23(3):1408.
20.Rasoulinejad SA, Maroufi F. CRISPR-Based Genome Editing as a New Therapeutic Tool in Retinal Diseases. Mol Biotechnol. 2021;63(9):768-79.
21.Abdel Reheem RN, Abdel Fattah MA. Serum vitamin D and parathormone (PTH) concentrations as predictors of the development and severity of diabetic retinopathy. Alexandria J Med. 2013;49(2):119-23.
22.Afarid M, Ghattavi N, Johari M. Serum Levels of Vitamin D in Diabetic Patients With and Without Retinopathy. J Ophthalmic Vis Res. 2020;15(2):172-7.
23.Ashinne B, Rajalakshmi R, Anjana RM, Narayan KM, Jayashri R, Mohan V, et al. Association of serum vitamin D levels and diabetic retinopathy in Asian Indians with type 2 diabetes. Diabetes Res Clin Pract. 2018;139:308-13.
24.Reddy GB, Sivaprasad M, Shalini T, Satyanarayana A, Seshacharyulu M, Balakrishna N, et al. Plasma vitamin D status in patients with type 2 diabetes with and without retinopathy. Nutrition. 2015;31(7-8):959-63.
25.Usluogullari CA, Balkan F, Caner S, Ucler R, Kaya C, Ersoy R, et al. The relationship between microvascular complications and vitamin D deficiency in type 2 diabetes mellitus. BMC Endocr Disord. 2015;15:33.
26.Suzuki A, Kotake M, Ono Y, Kato T, Oda N, Hayakawa N, et al. Hypovitaminosis D in type 2 diabetes mellitus: Association with microvascular complications and type of treatment. Endocr J. 2006;53(4):503-10.
27.Payne JF, Ray R, Watson DG, Delille C, Rimler E, Cleveland J, et al. Vitamin D insufficiency in diabetic retinopathy. Endocr Pract. 2012;18(2):185-93.
28.Ahmadieh H, Azar ST, Lakkis N, Arabi A. Hypovitaminosis d in patients with type 2 diabetes mellitus: a relation to disease control and complications. ISRN Endocrinol. 2013;2013:641098.
29.Bajaj S, Singh RP, Dwivedi NC, Singh K, Gupta A, Mathur M. Vitamin D levels and microvascular complications in type 2 diabetes. Indian J Endocrinol Metab. 2014 Jul-Aug; 18(4): 537-41.
30.He R, Shen J, Liu F, Zeng H, Li L, Yu H, et al. Vitamin D deficiency increases the risk of retinopathy in Chinese patients with type 2 diabetes. Diabet Med. 2014;31(12):1657-64.
31.Jee D, do Han K, Kim EC. Inverse association between high blood 25-hydroxyvitamin D levels and diabetic retinopathy in a representative Korean population. PLoS One. 2014;9(12):e115199.
32.Longo-Mbenza B, Muaka MM, Masamba W, Kini LM, Phemba IL, Ndembe DK, et al. Retinopathy in non diabetics, diabetic retinopathy and oxidative stress: a new phenotype in Central Africa?. Int J Ophthalmol. 2014;7(2):293-301.
33.Alcubierre N, Valls J, Rubinat E, Cao G, Esquerda A, Traveset A, et al. Vitamin D Deficiency Is Associated with the Presence and Severity of Diabetic Retinopathy in Type 2 Diabetes Mellitus. J Diabetes Res. 2015;2015:374178.
34.Bonakdaran S, Shoeibi N. Is there any correlation between vitamin D insufficiency and diabetic retinopathy?. Int J Ophthalmol. 2015;8(2):326-31.
35.Zoppini G, Galletti A, Targher G, Brangani C, Pichiri I, Trombetta M, et al. Lower levels of 25-hydroxyvitamin D3 are associated with a higher prevalence of microvascular complications in patients with type 2 diabetes. BMJ Open Diabetes Res Care. 2015;3(1):e000058.

[DOR: 20.1001.1.15614107.1401.24.1.24.0]
[DOI: 10.22088/jbums.24.1.189]

36.Jablonski KL, Chonchol M, Pierce GL, Walker AE, Seals DR. 25-Hydroxyvitamin D deficiency is associated with inflammation-linked vascular endothelial dysfunction in middle-aged and older adults. Hypertension. 2011;57(1):63-9.

37.Wong MS, Leisegang MS, Kruse C, Vogel J, Schürmann C, Dehne N, et al. Vitamin D promotes vascular regeneration. Circulation. 2014;130(12):976-86.

38.Al Mheid I, Patel R, Murrow J, Morris A, Rahman A, Fike L, et al. Vitamin D status is associated with arterial stiffness and vascular dysfunction in healthy humans. J Am Coll Cardiol. 2011;58(2):186-92.

39.Aksoy H, Akçay F, Kurtul N, Baykal O, Avci B. Serum 1,25 dihydroxy vitamin D (1,25(OH)2D3), 25 hydroxy vitamin D (25(OH)D) and parathormone levels in diabetic retinopathy. Clin Biochem. 2000;33(1):47-51.

40.Mazziotti G, Formenti AM, Adler RA, Bilezikian JP, Grossman A, Sbardella E, et al. Glucocorticoid-induced osteoporosis: pathophysiological role of GH/IGF-I and PTH/VITAMIN D axes, treatment options and guidelines. Endocrine. 2016;54(3):603-11.

41.Kaur H, Donaghue KC, Chan AK, Benitez-Aguirre P, Hing S, Lloyd M, et al. Vitamin D deficiency is associated with retinopathy in children and adolescents with type 1 diabetes. Diabetes Care. 2011;34(6):1400-2.

42.Long M ,Wang C, Liu D. Glycated hemoglobin A1C and vitamin D and their association with diabetic retinopathy severity. Nutr Diabetes. 2017;7(6):e281.

43.Luo BA, Gao F, Qin LL. The Association between Vitamin D Deficiency and Diabetic Retinopathy in Type 2 Diabetes: A Meta-Analysis of Observational Studies. Nutrients. 2017;9(3):307.

44.Zhang J, Upala S, Sanguankeo A. Relationship between vitamin D deficiency and diabetic retinopathy: a meta-analysis. Can J Ophthalmol. 2017;52(Suppl 1):S39-S44.

45.Lemieux P, Weisnagel SJ, Caron AZ, Julien AS, Morisset AS, Carreau AM, et al. Effects of 6-month vitamin D supplementation on insulin sensitivity and secretion: a randomised, placebo-controlled trial. Eur J Endocrinol. 2019;181(3):287-99.

46.Tecilazich F, Formenti AM, Giustina A. Role of vitamin D in diabetic retinopathy: Pathophysiological and clinical aspects. Rev Endocr Metab Disord. 2021;22(4):715-27.

47.Pérez LM, Fittipaldi M, Adrados B, Morató J, Codony F. Error estimation in environmental DNA targets quantification due to PCR efficiencies differences between real samples and standards. Folia Microbiol (Praha). 2013;58(6):657-62.

48.Omidian M, Djalali M, Javanbakht MH, Eshraghian MR, Abshirini M, Omidian P, et al. Effects of vitamin D supplementation on advanced glycation end products signaling pathway in T2DM patients: a randomized, placebo-controlled, double blind clinical trial. Diabetol Metab Syndr. 2019;11:86.

49.Sugden JA, Davies JI, Witham MD, Morris AD, Struthers AD. Vitamin D improves endothelial function in patients with Type 2 diabetes mellitus and low vitamin D levels. Diabet Med. 2008;25(3):320-5.

50.Millen AE, Sahli MW, Nie J, LaMonte MJ, Lutsey PL, Klein BE, et al. Adequate vitamin D status is associated with the reduced odds of prevalent diabetic retinopathy in African Americans and Caucasians. Cardiovasc Diabetol. 2016;15:128.

51.Al Dossari KK, Ahmad G, Aljowair A, Alqahtani N, Shibrayn MB, Alshathri M, et al. Association of vitamin d with glycemic control in Saudi patients with type 2 diabetes: A retrospective chart review study in an emerging university hospital. J Clin Lab Anal. 2020;34(2):e23048.

[DOR: 20.1001.1.15614107.1401.24.1.24.0]
[DOI: 10.22088/jbums.24.1.189]

52.Holick MF, Binkley NC, Bischoff-Ferrari HA, Gordon CM, Hanley DA, Heaney RP, et al. Evaluation, treatment, and prevention of vitamin D deficiency: an Endocrine Society clinical practice guideline. J Clin Endocrinol Metab. 2011;96(7):1911-30.

[DOR: 20.1001.1.15614107.1401.24.1.24.0]
[DOI: 10.22088/jbums.24.1.189]