Journal of
Babol University of Medical Sciences
JBUMS
e-ISSN: 2251-7170 p-ISSN: 1561-4107

A Case Report of Neuroleptic Malignant Syndrome during Methadone Therapy

M. J. Nasr [1], A. H. Zohrevand (MD)[2], D. Hosseini Talari (MD)[3], A. Alizadeh Khatir (MD)[*4]

1.Student Research Committee, Babol University of Medical Sciences, Babol, I.R.Iran.

2.Department of Neurosurgery, School of Medicine, Babol University of Medical Sciences, Babol, I.R.Iran.

3.Department of Psychiatry, School of Medicine, Babol University of Medical Sciences, Babol, I.R.Iran.

4.Mobility Impairment Research Center, Health Research Institute, Babol University of Medical Sciences, Babol, I.R.Iran.

Article Type

Case Report

Received:
Mar 4th 2022
Revised:
Apr 9th 2022
Accepted:
May 15th 2022

ABSTRACT

Background and Objective: Methadone is an opioid agonist used for the treatment of addiction to opioid drugs. Toxic leukoencephalopathy can cause serious problem and even be life-threatening. Methadone-induced leukoencephalopathy is a rare condition of this toxicity. Because of the importance of this situation and its treatment, we aim to report a case who is diagnosed as Methadone-induced leukoencephalopathy.

Case Report: A 63-year-old man referred with non-persistent fever, drowsiness, rigidity and suspected of neuroleptic malignant syndrome (NMS). He was addicted to opioid from young age. He was on maintenance therapy with 80 mg methadone syrup from 2 months ago. After the appearance of symptoms including delirium, impaired attention and consciousness, treatment was performed with half a tablet of haloperidol 0.5 mg twice a day before rigidity and fever. Multiple lesions were seen in baseline CT-Scan and MRI. Toxic laboratory examination showed methadone was positive and other toxins and opioids were negative. After two weeks, second MRI showed rapid progressive lesions in white matter. Thus, it was diagnosed as Methadone-induced leukoencephalopathy in addition to NMS. Hydration, bromocriptine tablets 2.5 mg twice a day, methadone tapering and haloperidol discontinuation were performed. After two months, the patient's consciousness was better and his CPK and LDH tests were normal.

Conclusion: Methadone-induced leukoencephalopathy is a very rare condition, but it is important for physicians to consider this diagnosis in patients using methadone, especially when they show neurological and psychiatric signs and symptoms. That's because early methadone tapering can reduce and stop toxicity on the white matter of the brain.

Keywords: *Methadone, Leukoencephalopathy, Neuroleptic Malignant Syndrome*.

Cite this article: Nasr MJ, Zohrevand AH, Hosseini Talari D, Alizadeh Khatir A. A Case Report of Neuroleptic Malignant Syndrome during Methadone Therapy. *Journal of Babol University of Medical Sciences*. 2022; 24(1): 423-7.

© The Author(S).
Publisher: Babol University of Medical Sciences

[*]Corresponding Author: A. Alizadeh Khatir (MD)
Address: Mobility Impairment Research Center, Health Research Institute, Babol University of Medical Sciences, Babol, I.R.Iran.
Tel: +98 (11) 32199592. **E-mail:** alizade.ali83@yahoo.com

[DOR: 20.1001.1.15614107.1401.24.1.50.6]
[DOI: 10.22088/jbums.24.1.423]

Introduction

Leukoencephalopathy is referred to any disease which involves part of white matter in central neuron system (CNS) (1). Many factors such as drugs, environmental toxins, therapeutic and other agents like radiation and chemotherapy are involved in toxic leukoencephalopathy (2, 3). Inattention, forgetfulness, and changes in personality and coma are symptoms of toxic leukoencephalopathy (2). Methadone, a drug used for opioid dependence treatment, can have serious effects on CNS and cause leukoencephalopathy, which is rare (4). Chasing the dragon is a method of smoking opium that is associated with heroin-induced leukoencephalopathy, and is done by heating and inhalation (5). It is an important pattern of white matter lesions in brain and has three stages: cerebellar symptoms, motor restlessness and pyramidal and pseudobulbar symptoms (5). Neuroleptic Malignant Syndrome (NMS) is a life-threatening complication of using antipsychotic drugs which is characterized by fever, severe muscle rigidity and autonomic mental status changes (6).

In a study by Hakamifard et al., a 39-year-old man was presented with a history of methadone overdose with loss of consciousness and fever. A month ago, he was diagnosed with methadone overdose, rhabdomyolysis, and acute kidney failure, and was hospitalized in the intensive care unit and discharged with a normal level of consciousness. A week later, he referred with delusion and loss of consciousness. CSF and laboratory tests were normal and axial T2-weighted MR and FLAIR MR-image showed bilateral symmetric subcortical hyperintensities. Combining patient history, laboratory tests and MR and FLAIR MR images, delayed post-hypoxic leukoencephalopathy (DPHL) was diagnosed and treatment with antioxidants revealed a favorable outcome (7).

In this case report, we present a methadone-induced toxic leukoencephalopathy with rapid increasing of white matter lesions in the brain that was similar to Chasing the Dragon pattern. This term is seen in the inhalation of opioid substances, but our patient had no history of inhaling these substances at all. DPHL is different from toxic leukoencephalopathy, which was diagnosed in our patient, because our patient had a history of addiction, not hypoxia.

Case Report

This case report was approved with the code IR.MUBABOL.HRI.REC.1401.057 by ethics committee of Babol University of Medical Sciences. A 63-year-old man referred to hospital with non-persistent fever, drowsiness, rigidity and suspected of NMS. In social habit history, he was addicted to opium from young age and had no history of addiction to other drugs. Drug history showed that he was on maintenance therapy with 80 mg methadone syrup from 2 months ago and he did not use opium in inhalation form. After the appearance of symptoms including delirium, impaired attention and consciousness, treatment was performed with half a tablet of haloperidol 0.5 mg twice a day (morning and night) before rigidity and fever. After fever and rigidity, the neurology examination showed that he had inattention and agitation and did not obey commands. He had rigid tone. Other examinations were normal. Creatine phosphokinase (CPK) and Lactate dehydrogenase (LDH) were requested and they were positive. Thus, our first diagnosis was NMS but he had some lesions in Brain Computed Tomography Scan (CT-Scan). Therefore, brain magnetic resonance imaging (MRI) was performed and it was observed that there were numerous white matter lesions that did not increase in DW1 sequences after gadolinium injection (Figure 1A). We requested laboratory test for CBC, electrolytes, liver functional test (LFT), ESR, CRP, test for vasculitis and coagulopathies, infections (HIV, other infectious (VDRL, WRIGHT, ME2…) and CSF analysis), serum and CSF lactate and ammonium, Anti TPO, and ACE, all of which were normal. Toxic laboratory examination showed

[DOR: 20.1001.1.15614107.1401.24.1.50.6]
[DOI: 10.22088/jbums.24.1.423]

methadone was positive and other toxins and opioids were negative. Brain and Cervical Magnetic Resonance Angiography (MRA) and transesophageal echocardiography (TEE) were normal, too. After two weeks, the patient's situation got worse; so, second MRI was preformed and the result showed rapid progression of lesions in brain white matter, which is similar to Chasing the Dragon pattern. This term is seen in the inhalation of opioid substances, but our patient had no history of inhaling these substances at all (Figure 1B). Considering the patient's history, examinations and paraclinical tests, the patient's diagnosis was methadone-induced leukoencephalopathy in addition to NMS. Hydration, Tab bromocriptine (2.5 mg BD), tapering methadone and haloperidol discontinuation were performed. After two months, the patient situation and his alertness got better than before and CPK and LDL were also normal.

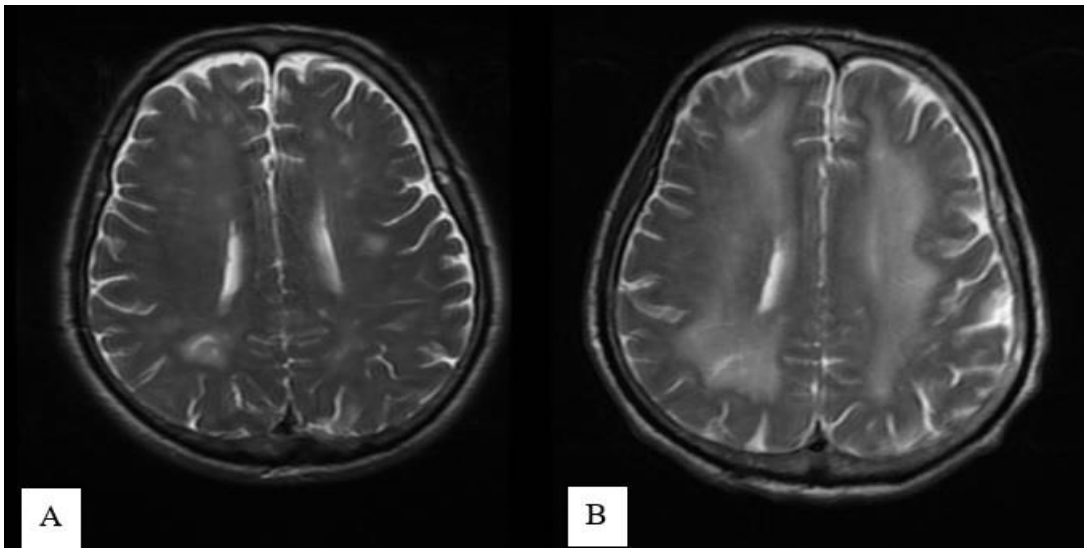

Figure 1. A: First MRI, Axial T2 and B: Second MRI (after two weeks), Axial T2

Discussion

In this study, a case of methadone-induced leukoencephalopathy was presented along with the patient's history, examinations and paraclinical tests. Because of the rigidity, fever, high CPK and LDH levels, the first diagnosis was NMS. With further research, along with history of methadone use, the diagnosis of methadone-induced leukoencephalopathy was suggested in addition to NMS. The patient was better after hydration, bromocriptine 2.5 mg twice a day, methadone tapering and haloperidol discontinuation. This is a unique report of methadone-induced leukoencephalopathy because we re-evaluated the patient with neuroimaging after two weeks and observed toxic effects of methadone on the white matter, which developed rapidly (a lot of new white matter lesions were created in this short period of time, whereas neuroimaging changes assessments have not been performed in similar studies). Therefore, hydration and use of bromocriptine along with methadone tapering as soon as possible and haloperidol discontinuation in these patients can reduce its toxic effects on the brain.

In a case reported by Panjwani et al., a 50-year-old woman was presented with methadone overdose and MRI showed small foci of restricted diffusion near the vertex in the parasagittal regions. Management and treatment were done and she was discharged with stable condition. Three weeks later, she referred for follow up with headache, confusion, and blurry vision. All blood tests were negative and repeated MRI showed the increase in diffuse and bilateral symmetric T2 signal in the frontal, parietal, and occipital white matter

[DOR: 20.1001.1.15614107.1401.24.1.50.6]
[DOI: 10.22088/jbums.24.1.423]

representing toxic leukoencephalopathy (8). In a case reported by Anbarasan et al., a 35-year-old woman was presented with thought impoverishment, disorganized behavior, and echolalia and progressed to treatment-refractory catatonia. Her brain MRI had findings of Drug-induced leukoencephalopathy. She had a history of cocaine use and was diagnosed with cocaine-induced leukoencephalopathy (9).

Salgado et al. report a 65-year-old woman with clinical neurologic examination of apathy, a catatonic state with extreme rigidity, increased reflexes in the upper limbs, and a bilaterally positive Babinski sign. Laboratory tests were normal and she had a history of hip prothesis 12 months before admission, with oral methadone treatment for chronic intractable pain (3 * 10 mg/day). Toxicology screening showed a very high amounts of an opioid identified as methadone. FLAIR and T2-weighted images showed extensive and symmetric signal-intensity abnormalities in the deep white matter of both cerebral hemispheres, along with the reduction in subcortical U-fibers. Combining MR imaging and proton MR spectroscopy findings with a history of high dose usage of methadone and the exclusion of exposure to other neurologically toxic substances, the diagnosis of methadone-induced toxic leukoencephalopathy was established (3).

Methadone-induced leukoencephalopathy is a very rare condition but it is very important for physicians to consider this diagnosis in patients who use methadone, specially when they have neurologic and psychologic signs and symptoms, because early taper of methadone can decrease and stop its toxicity on white matter of brain.

Conflict of Interest: The authors declare that there are no conflicts of interest.

Acknowledgment

We would like to thank the Mobility Impairment Research Center of Babol University of Medical Sciences.

[DOR: 20.1001.1.15614107.1401.24.1.50.6]
[DOI: 10.22088/jbums.24.1.423]

References

1.Lyon G, Fattal-Valevski A, Kolodny EH. Leukodystrophies: clinical and genetic aspects. Top Magn Reson Imaging. 2006;17(4):219-42.

2.Filley CM, Kleinschmidt-DeMasters BK. Toxic leukoencephalopathy. N Engl J Med. 2001;345(6):425-32.

3.Salgado RA, Jorens PG, Baar I, Cras P, Hans G, Parizel PM. Methadone-induced toxic leukoencephalopathy: MR imaging and MR proton spectroscopy findings. AJNR Am J Neuroradiol. 2010;31(3):565-6.

4.Anselmo M, Campos Rainho A, do Carmo Vale M, Estrada J, Valente R, Correia M, et al. Methadone intoxication in a child: toxic encephalopathy?. J Child Neurol. 2006;21(7):618-20.

5.Keogh CF, Andrews GT, Spacey SD, Forkheim KE, Graeb DA. Neuroimaging features of heroin inhalation toxicity: "chasing the dragon". AJR Am J Roentgenol. 2003;180(3):847-50.

6.Strawn JR, Keck Jr PE , Caroff SN. Neuroleptic malignant syndrome. Am J Psychiatry. 2007;164(6):870-6.

7.Hakamifard A, Hajiahmadi S, Khorvash F, Azish S. A case study of methadone-induced delayed post-hypoxic leukoencephalopathy with improvement by antioxidant therapy. North Clin Istanb. 2020;8(1):106-8.

8.Panjwani S, Karim N, Humayun M, Tietjen G. Unsual Case of Methadone Induced Toxic Leukoencephalopathy. Neurology. 2018;90(15 Suppl):P5.406. Available from: https://n.neurology.org/content/90/15_Supplement/P5.406.abstract

9.Anbarasan D, Campion P, Howard J. Drug-induced leukoencephalopathy presenting as catatonia. Gen Hosp Psychiatry. 2011;33(1):85.e1-3.

[DOR: 20.1001.1.15614107.1401.24.1.50.6]

[DOI: 10.22088/jbums.24.1.423]