







A Rare Case of Hernia of the Bladder Diverticulum in the Inguinal Region: A Case Report

M. H. Niakan (MD)¹ , M. Dehbozorgi (MD)² , M. Hasanshahi (MSc)³ , S. Gheisari (MSc)⁴ ,
F. Kalashipour (MSc)⁵ , A. Ebrahimi (MSc)^{*6} 

1.Trauma Research Center, Shahid Rajaei (Emtiaz) Trauma Hospital, Shiraz University of medical Sciences, Shiraz, I.R.Iran.

2.Department of General Surgery, School of Medicine, Shiraz University of medical Sciences, Shiraz, I.R.Iran.

3.Department of Nursing, School of Nursing and Midwifery, Shiraz University of Medical Sciences, Shiraz, I.R.Iran.

4.Student Research Committee, Shiraz University of Medical Sciences, Shiraz, I.R.Iran.

5.Department of Operating Room, School of Nursing and Midwifery, Kurdistan University of Medical Sciences, Sanandaj, I.R.Iran.

6.Department of Operating Room, School of Allied Medical Sciences, Bushehr University of Medical Sciences, Bushehr, I.R.Iran.

Article Type	ABSTRACT
Case Report	<p>Background and Objective: Bladder hernias occur in 1% to 4% of cases in the inguinal area. The hernial sac may contain any part of the bladder, such as the bladder diverticulum, all or part of the bladder and ureter. Most of these hernias are diagnosed during surgery. Delay in diagnosis can lead to serious complications and even death. The aim of this case report is to introduce a patient with a rare hernia of the bladder diverticulum in the inguinal region.</p> <p>Case Report: The patient is a 58-year-old man who referred to Namazi Hospital in Shiraz with a bulge in the right inguinal region with symptoms of incarcerated hernia. The patient complained of pain and swelling in the right inguinal region and did not show any signs or symptoms of urinary tract involvement. During laparotomy, the mass was found to be connected to the bladder and the patient underwent inguinal hernia repair. The patient was discharged from the hospital one day after the operation without any problems. No complications were reported in follow-up two months after surgery.</p> <p>Conclusion: According to our report, hernia of the urinary bladder diverticulum in the inguinal region may be asymptomatic. Therefore, accurate reporting of the patient's history and previous problems and diseases is required for careful surgical planning to prevent severe complications, including bladder injury in these people.</p> <p>Keywords: <i>Bladder Diverticula, Diverticulum, Inguinal Hernia, Hernia.</i></p>

Received:

May 17th 2021

Revised:

Jun 27th 2021

Accepted:

Jul 19th 2021

Cite this article: Niakan MH, Dehbozorgi M, Hasanshahi M, Gheisari S, Kalashipour F, Ebrahimi A. A Rare Case of Hernia of the Bladder Diverticulum in the Inguinal Region: A Case Report. *Journal of Babol University of Medical Sciences*. 2022; 24(1): 76-82.



© The Author(S).

Publisher: Babol University of Medical Sciences

***Corresponding Author: A. Ebrahimi (MSc)**

Address: Department of Operating Room, School of Allied Medical Sciences, Bushehr University of Medical Sciences, Bushehr, I.R.Iran.

Tel: +98 (77) 35425316. **E-mail:** Abed.or90@gmail.com

Introduction

Bladder diverticula are relatively rare and usually lead to a hernia of the bladder mucosa through the bladder wall due to weakening of the bladder muscle fibers and increased intracavitary pressure (1). These lesions may be congenital and cause symptoms in childhood that are usually diagnosed during this period, or they may be acquired and result from narrowing of the urinary tract (e.g., prostatic hypertrophy) (2, 3). This creates a structure with different sizes with a thin wall full of urine which is adjacent to the bladder and is connected to the bladder by a narrow opening or neck. In the diverticulum wall, muscles are smooth and scattered, inactive, and inconsistent and are unable to drain urine from the diverticulum during urination (2). The non-specificity of its symptoms can delay diagnosis and treatment and lead to serious complications or even death (4). Ultrasound, CT scan, and MRI are required to diagnose the disease, but the best diagnostic method is Voiding cystourethrography (VCUG) (2).

Inguinal hernia is a common surgical pathology that usually involves the abdominal viscera surrounded by the peritoneum and an extraperitoneal organ not normally found in the hernia sac. However, in some rare cases, the bladder diverticulum and extraperitoneal organs can be pulled by the sac itself and become part of the hernia (1). Bladder hernia in the inguinal region was first described by Levine in 1951, but is very rare despite the proximity of the bladder to the inguinal canal (5). Bladder hernias occur in 1% to 4% of cases in the inguinal region, although they occur in 10% of obese men over 50 (6). The hernia sac may contain any part of the bladder, such as the bladder diverticulum, all or part of the bladder and ureter (7). Risk factors include male gender, old age, chronic urinary obstruction, pelvic floor muscle weakness, and obesity (8). It is noteworthy that only 7% of bladder hernias are diagnosed in the inguinal region before surgery, most of these hernias are diagnosed during surgery and 16% of cases are diagnosed after surgery due to complications such as bladder injury and leakage of urine (9).

Diagnosis of hernia in the inguinal region can be challenging because most patients are asymptomatic, in which case preoperative diagnosis depends on accidental radiographic findings (10). Patients with symptoms often have nonspecific symptoms such as inguinal swelling, dysuria, hematuria, and urinary urgency. Severe urologic complications include urinary tract infection, urinary obstruction, and even bladder necrosis which require subtotal cystectomy (11). Related pathologies include benign prostatic hyperplasia, hydronephrosis, vesicoureteral reflux, and scrotal abscesses (8). Repair of this hernia is preferred to open surgery (12).

The standard treatment for this hernia is to replace the bladder or remove part of the bladder, followed by herniorrhaphy (13). If this disease is diagnosed, it is recommended to place a urinary catheter before the operation (12). Prompt diagnosis of an inguinal hernia and appropriate preoperative imaging can help plan for a modified surgical procedure and reduce postoperative complications (11). In one study, a bladder diverticulum hernia in the right femoral canal was reported (1). In another study, a bladder diverticulum hernia in the inguinal region was detected and reported in a 54-year-old man in CT scan (14). In another study, a bladder diverticulum hernia in the inguinal region was diagnosed by intravenous urography (15). Our report presents a 58-year-old man who was diagnosed with a specific symptom of a bladder diverticulum hernia in the inguinal region after surgery.

Case Report

This study was approved by the ethics committee of Shiraz University of Medical Sciences with the code IR.SUMS.NUMIMG.REC.1400.069. The patient is a 58-year-old man who referred to the Namazi Hospital in Shiraz with a bulge in the right inguinal hernia with signs of incarcerated hernia and reported

symptoms such as nausea, vomiting, pain and swelling in the right inguinal region. The patient was examined and had pain during the examination. The patient was admitted and hernia was replaced under sedation, which was unsuccessful. Therefore, the patient underwent surgery, and based on the history before the operation, the patient had no history of inguinal surgery. He did not mention any urinary tract problems. The patient received 2 g of cefazolin before surgery and underwent general anesthesia. The right inguinal region was incised, adhesions were released, and the contents of the hernia were identified (Figure 1).

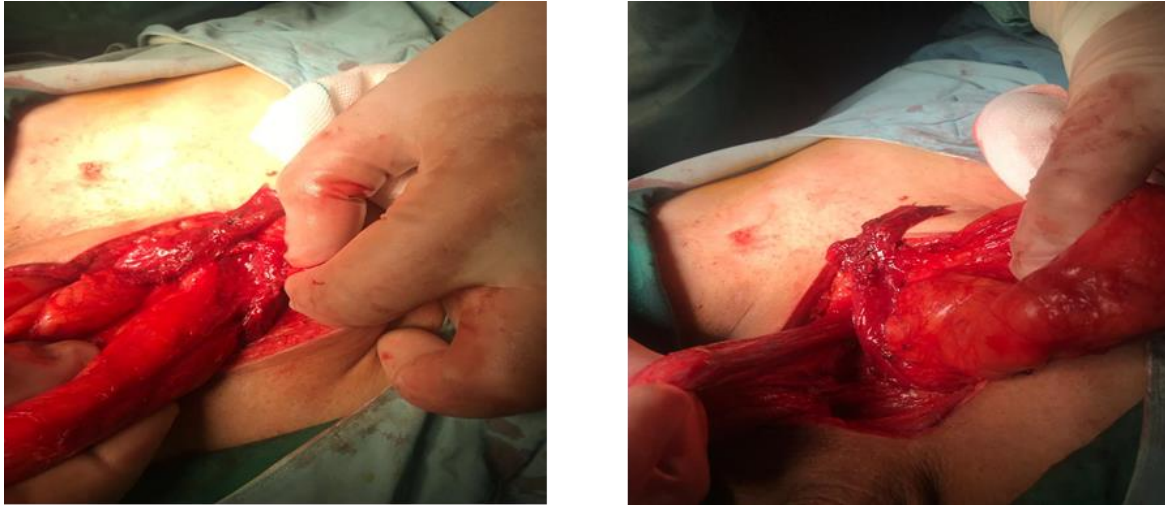

Figure 1. Image of the right inguinal region and hernia sac

Because the floor of the inguinal canal was very large, a Foley catheter was used for the patient. After the patient's urine was emptied by the Foley catheter, the floor of the inguinal canal was collapsed. With the advice of urologists during surgery, a part of the bladder was detected to be entering the inguinal region. Differential diagnoses included the presence of part of the sigmoid colon, cecum, small intestine, mesentery, omentum, and bladder. Based on the evidence, the presence of bladder at the hernia site was detected. Thus, without causing any damage, the contents of the hernia were returned to their original location and the hernia was repaired.

Due to the fact that the patient had a very large inguinal hernia, the floor of the inguinal canal needed to be reconstructed, which was strengthened by McVeigh method. Then, due to the weak abdominal wall, the polypropylene mesh was placed by the Liechtenstein method and the abdominal wall was repaired. Finally, the fascia and subcutaneous tissue were sutured with PDS II zero thread and the skin was sutured using 3-0 nonabsorbable monofilament nylon based on subcuticular method. Finally, the target area was bandaged.

After the operation and after the patient regained consciousness, a history was taken. The patient stated that he had a bladder diverticulum, and he underwent cystoscopy 1 year ago and was diagnosed with a bladder diverticulum, which he did not state before the operation. Therefore, the patient was advised to refrain from strenuous physical activity and lifting heavy objects for 2 months. The patient was discharged from the hospital one day after the operation without any problems. No complications were reported in follow-up two months after surgery.

Discussion

In this reported case, the bladder diverticulum was presented as a mass in the right inguinal region with pain and swelling in the area and was not diagnosed before surgery. On the other hand, the patient had no signs and symptoms of urinary tract involvement. Only during laparotomy, the mass associated with the bladder was detected and the patient underwent inguinal hernia repair. This has been reported in some studies (7, 11, 16, 17).

Inguinal hernia of the urinary system is a rare finding. A retrospective study on 1910 patients with inguinal hernia showed bladder hernia in 7 patients (0.37%) and bladder diverticulum in only one patient (0.05%) (18). Extraperitoneal and intraperitoneal methods can be used in surgeries of bladder diverticulum hernias in the inguinal canal (1). We chose the open surgery method. Some researchers have suggested the open method as the preferred method, although cases of laparoscopic repair have been reported (6, 19). Foley catheterization before surgery is recommended. Proper identification of the hernia and separation of hernia components are very important (19). However, during the operation and after cutting the inguinal region, we placed a Foley catheter and observed that the volume of the mass decreased after urination. The pathophysiology of a bladder hernia into the inguinal region involves stretching the bladder with the peritoneum through a weak spot in the abdominal fascia (19).

Rare cases of inguinal bladder hernia may involve entrance of part of the bladder into the scrotum. In these conditions, the patient may experience two-stage urination, in which patients feel the need to squeeze the scrotum in order to urinate (11). Other rare cases of inguinal bladder hernia have been reported, indicating that this hernia leads to acute renal failure, bilateral hydronephrosis, herniation of the urinary bladder into the inguinal canal, intestinal ischemia, and ureteral obstruction years after kidney transplantation (8, 20-22). Our patient did not have any of these symptoms. Accurate history and physical examination are important for initial diagnosis (11). However, the patient may be asymptomatic (8). Ultrasound, cystography and CT have been used to confirm the diagnosis (11). Due to the fact that the diagnosis of bladder hernia before surgery is very low, the physician should consider the probability of this type of hernia in the elderly, obese and male populations among which the prevalence of this hernia is 10% (6).

The standard treatment for repairing a bladder hernia in the inguinal region involves returning the bladder to its original position or, in rare cases, removing part of the bladder followed by repairing the area. Previously, midline laparotomy was used to repair a hernia, but recently it has been performed with open inguinal incision or laparoscopic repair (23). Bladder resection is currently recommended in cases of bladder wall necrosis, bladder diverticulum hernia, umbilical hernia, and bladder tumor with hernia (11). Bladder catheterization can also be used for conservative treatment, which reduces bladder pressure (9). In our case, an open incision was made in the inguinal region. The bladder along with the diverticulum returned to its place, and the area was repaired with polypropylene mesh, and the patient recovered without complications.

According to the results of this report, bladder hernia in the inguinal region is a rare disease that is difficult to diagnose before surgery. In this case report, we presented a case of bladder diverticulum hernia in the inguinal region where the patient had pain and swelling in the right inguinal region. According to our report, bladder hernia in the inguinal region may be asymptomatic. The patient may also refrain from giving a history of previous illnesses for a variety of reasons. Therefore, accurate reporting of the patient's history and previous problems and illnesses is required for careful surgical planning to prevent severe complications, including bladder injury.

Acknowledgment

Hereby, we would like to thank the Vice Chancellor for Research of Shiraz University of Medical Sciences and the Head of Namazi Hospital, who provided us with the necessary permits to report this case, as well as the patient and his family, who provided the necessary information at all stages of the study and the staff of Namazi Hospital in Shiraz who helped us with this research.

References

1. Biswas S, Morel EM, Petersen K, McCrae A. Incarcerated Bladder Diverticulum in a Femoral Hernia Presenting as Recurrent Hematuria. *Cureus*. 2020;12(8):e9681.
2. Jiang S, Ren Q, Wang X, Yang G, Wei S, Zhao Q, et al. A huge bladder diverticulum in an elderly: A case report. *SAGE Open Med Case Rep*. 2020;8:2050313x20943475.
3. Ibrahimi A, Kallat A, Ziani I, El Sayegh H, Benslimane L, Nouini Y. Spontaneous Intraperitoneal Rupture of Bladder Diverticulum: A Rare Cause of Peritonitis. *Case Rep Urol*. 2020;2020:8880748.
4. Qiao P, Tian D, Bao Q. Delayed diagnosis of spontaneous bladder rupture: a rare case report. *BMC Womens Health*. 2018;18(1):124.
5. Levine B. Scrotal cystocele. *J Am Med Assoc*. 1951;147(15):1439-41.
6. Hamidi Madani A, Mohammadi Nikouei H, Baghani Aval H, Enshaei A, Asadollahzade A, Esmaeili S. Scrotal herniation of bladder: a case report. *Iran J Med Sci*. 2013;38(1):62-4.
7. Oral A, Yazıcı B. Inguinoscrotal bladder hernia detected by SPECT/CT on bone scintigraphy. *Ege J Med / Ege Tıp Dergisi*. 2019;58(3):303-5.
8. Habib A. A rare case of inguinal hernia with complete bladder herniation. *Case Rep Surg*. 2017;2017:4658169.
9. Khan K, Chaudhry A, Feinman MB. Inguinoscrotal hernia containing the urinary bladder. *BMJ Case Rep*. 2016;2016:bcr2016217408.
10. Kraft KH, Sweeney S, Fink AS, Ritenour CW, Issa MM. Inguinoscrotal bladder hernias: report of a series and review of the literature. *Can Urol Assoc J*. 2008;2(6):619-23.
11. Elkbuli A, Narvel RI, McKenney M, Boneva D. Inguinal bladder hernia: A case report and literature review. *Int J Surg Case Rep*. 2019;58:208-11.
12. Taskovska M, Janež J. Inguinal hernia containing urinary bladder-A case report. *Int J Surg Case Rep*. 2017;40:36-38.
13. Ugur M, Atci N, Oruc C, Akkucuk S, Aydogan A. Left inguinal bladder hernia that causes dilatation in the ureter. *Arch Iran Med*. 2016;19(5):376-8.
14. Burdan F, Starosławska E, Mocarska A, Cendrowska-Pinkosz M, Caban M, Zelazowska-Cieślińska I, et al. Urinary bladder diverticulum as an unusual content of the inguinal canal. *Folia Morphol (Warsz)*. 2014;73(4):500-3.
15. Nabavizadeh R, Nabavizadeh B, Hampton LJ, Nabavizadeh A. Herniation of a urinary bladder diverticulum: diagnosis and management of a fluctuating inguinal mass. *BMJ Case Rep*. 2017;2017:bcr2016217947.
16. Oudou AZ, Somuah T, Anas B, Eddine AA, Tarek S, Hassan FM, et al. Inguinal bladder hernia, a rare cause of inguinal herniation: Report of two cases. *J Surg Med*. 2019;3(5):414-6.
17. McLellan J, Mir ZM, Di Lena M, Nanji S, Beiko D. Case- Recurrent incarcerated inguinal bladder hernia with small bowel obstruction. *Can Urol Assoc J*. 2019;13(11):E382-4.
18. Gurer A, Ozdogan M, Ozlem N, Yildirim A, Kulacoglu H, Aydin R. Uncommon content in groin hernia sac. *Hernia*. 2006;10(2):152-5.
19. Moufid K, Touiti D, Mohamed L. Inguinal bladder hernia: four case analyses. *Rev Urol*. 2013;15(1):32-6.
20. Çalışkan S, Türkmen M, Sungur M. Inguinal bladder hernia in female patient. *Iran J Med Sci*. 2018;43(6):671-2.
21. Wagner AA, Arcand P, Bamberger MH. Acute renal failure resulting from huge inguinal bladder hernia. *Urology*. 2004;64(1):156-7.

22. Ghelmini E, Julita L, Cerantola Y, Matter M, Zingg T. Inguinal bladder hernia with acute ureteral obstruction 14 years after kidney transplantation: a case report. *Transplant Proc.* 2017;49(7):1593-5.
23. François J, Defoort B, Muysoms F. Complicated inguino-scrotal bladder hernia: a case of two-step repair. *Acta Chir Belg.* 2017;117(2):122-4.