

Asynchronous Bilateral Testicular Cancer in A Patient with Bilateral Undescended Testicle: A Case Report

H. Shafi (MD)¹, S. H. Ghasemi Shektaei (MD)², M. M. Darzi (MD)², Gh. Rostami (MD)^{*3}

1. Infertility and Reproductive Health Research Center, Health Research Institute, Babol University of Medical Sciences, Babol, I.R.Iran

2. Student Research Committee, Babol University of Medical Sciences, Babol, I.R.Iran

3. Clinical Research Development Center, Shahid Beheshti Hospital, Babol University of Medical Sciences, Babol, I.R.Iran

J Babol Univ Med Sci; 23; 2021; PP: 375-379

Received: Mar 9th 2021, Revised: Apr 18th 2021, Accepted: Apr 28th 2021.

ABSTRACT

BACKGROUND AND OBJECTIVE: Testicular cancer is almost the only common genitourinary tract cancer at a young age. One of the risk factors for testicular tumors is undescended testicles. If testicular fixation is corrected in the normal position, the probability of testicular cancer decreases in the undescended testicle before puberty, but it does not disappear, and the patient should be examined for a long time. The purpose of this case report is to introduce a patient who, despite undergoing orchidopexy, has developed asynchronous bilateral testicular cancer, which shows the importance of long-term follow-up in people with a history of undescended testicles.

CASE REPORT: The patient was a 54-year-old man with a history of congenital bilateral undescended testicles, infertile, and orchidopexy surgery in childhood and a history of classic seminoma in the left testicle four years ago. Again, in periodic follow-ups and examination of the right testicle, a mass in the right testicle was touched, which showed malignant changes in the ultrasound. Serum levels of testicular markers were normal. According to the sonographic findings, examinations and patient records, the patient underwent radical right testicular orchidectomy. Classic seminoma was reported in the results of right testicle pathology, and in further examinations, no evidence of metastasis was seen. The patient is currently undergoing follow-up and postoperative chemotherapy.

CONCLUSION: According to the results of this case reported in patients with intangible testicles, especially bilateral, long-term follow-up is necessary for asynchronous bilateral testicular cancer.

KEY WORDS: *Mass, Bilateral Testicular Cancer, Bilateral Seminoma, Bilateral Undescended Testicles.*

Please cite this article as follows:

Shafi H, Ghasemi Shektaei SH, Darzi MM, Rostami Gh. Asynchronous Bilateral Testicular Cancer in A Patient with Bilateral Undescended Testicle: A Case Report. J Babol Univ Med Sci. 2021; 23: 375-9.

*Corresponding Author: Gh. Rostami (MD)

Address: Clinical Research Development Center, Shahid Beheshti Hospital, Babol University of Medical Sciences, Babol, I.R.Iran

Tel: +98 11 32256285

E-mail: ghasemrostami27@yahoo.com

Introduction

Testicular cancer accounts for approximately 1% of all cancers diagnosed in men, with the most common cancer occurring between the ages of 15 and 35. Histologically, the most common type of testicular cancer is the classic type of seminoma. In all types of testicular cancers, the presence of bilateral tumors is rare and its prevalence is 0.8 per 1,000,000 men between the ages of 15 and 40, one-third of which are concomitant and two-thirds of which are asynchronous (1). Bilateral testicular cancer accounts for 1-5% of testicular cancers in total (2). Undescended testicle (UDT) is common in children and occurs in 1-4% of full-term infants and in 45% of preterm infants worldwide (3, 4).

The position of the undescended testicle may vary and may be located in the abdominal cavity, inguinal canal, or subcutaneous cavity. Although a large proportion of these cases resolve spontaneously by 3 months of age, only 1% of patients require testicular fixation surgery (orchidopexy) (5). The importance of surgery for UDT is because boys with UDT are more likely to develop testicular cancer later in life (6). However, the mechanism of this pathology is unknown. Abnormal deformation of neonatal germ cells in UDT may be due to heat stress, which may increase the incidence of cancer and infertility in men (7). Previous reports indicate that the risk of malignancy is higher in patients with bilateral undescended testicle or delayed testicular fixation surgery (6). Bilateral testicular tumors are rare and 80% of bilateral tumors are asynchronous (7).

There is a general consensus that primary testicular fixation surgery improves outcomes associated with fertility markers and testicular malignancy (8). Recent international guidelines recommend that orchidopexy be performed before 12 months of age to maintain fertility potential and prevent the risk of malignancy (9). However, studies have reported that even with successful treatment, impaired spermatogenesis or malignancy can still occur (10).

The patient in this case was a 54-year-old man with a history of bilateral undescended testicle who was presented with bilateral testicular tumor twice after testicular fixation surgery. Both the patient's old age and the presence of bilateral tumors are among the rare cases.

Case Report

This study was approved by the ethics committee of Babol University of Medical Sciences with the code IR.MUBABOL.REC.1400.093. The patient is a 54-year-old man with a history of congenital undescended testicle, infertile, and history of orchidopexy surgery in childhood who referred to the urology clinic with a complaint of painless testicular mass on the right side.

The patient had a history of left testicular tumor four years ago and underwent radical left orchiectomy. During these four years, the patient did not have any particular problems and was under periodic follow-up. The patient did not report a history of trauma to his right testicle. In the examination, the left testicle could not be touched due to the orchidectomy. The testicle was atrophic and the mass was approximately one centimeter in the testicle. The mass was fixed and attached to the testicle and was painless to the touch. The patient does not mention family history of tumor or malignancy in family.

The patient had a 1.5 cm calcified mass in ultrasound examinations 4 years ago in periodic ultrasound. The testicular tumor was in the inguinal canal and a radical left orchidectomy was performed. There was a tumor with a size of 1.5 cm, the pathology of which was of the classic type of seminoma and did not invade into the surrounding tissues. The patient then underwent metastasis. In these examinations, CT scan of the abdomen and pelvis and radiographs of the lungs were completely normal and no evidence of tumor spread was found. Then, during the last 4 years, he underwent periodic ultrasound and examination of tumor markers and chest radiograph, which did not show any mass in the testis. Then, in the last ultrasound examination of the patient, the testis was located in the inguinal canal of normal size, which was observed in the hypoechoic testicular mass with dimensions of 9×11 mm (Figure 1).

In the examinations, the levels of various tumor-related factors were measured. In this study, LDH=347, BHCG<5 and Afp=2.8 were reported, which were within the normal range. The patient was examined for metastasis by CT scan of the abdomen and pelvis, but there was no evidence in favor of metastasis. According to the patient's history and ultrasound findings, the patient became a candidate for radical right

orchiectomy. Despite the patient's testicle being isolated and atrophic and infertility of the patient, the patient was offered partial orchiectomy with frozen section during surgery, but the patient refused. The patient then underwent a radical right orchiectomy and the patient's testicle was sent back to the pathology for histological examination.

The patient had a histology of the classic type seminoma, and similar to the previous tumor, testicular capsule was free of tumor tissue, and the vas deferens and seminal vesicles and tissue margins were empty of tumor tissue. Considering the surgery for the patient, postoperative follow-up measures were taken to assess tumor markers one month after surgery and were normal, and abdominal and pelvic CT scans were performed one and three months after surgery, which showed no evidence in favor of metastasis. Continuing the patient follow-up protocol with CT scan of the abdomen and pelvis and chest radiography and periodic testing of markers was recommended.

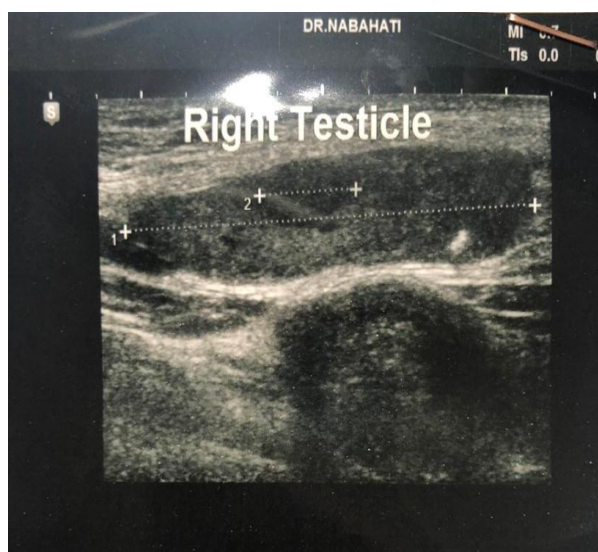


Figure 1. Ultrasound view of right testicular tumor

Discussion

The patient is a special case for several reasons. The first is the old age of the patient, which shows that people who have a known risk factor for testicular cancer, need to have long-term follow-up and follow-up should never be stopped in such cases. In a systematic study performed on bilateral tumors in 2012 (11), the mean age of patients at the time of initial tumor diagnosis was 30.4 years, which is significantly lower

than the age of our patient. The next point that is important in this patient is the bilateral nature of the patient's tumor, which has occurred asynchronously and with an interval of 4 years. In the mentioned systematic study (11), 69.2% of the bilateral tumors examined were asymptomatic and the mean time interval between asymptomatic tumors was 65.6 months, while our patient developed the second tumor in a shorter period. Another point is that the pathologies reported from both testicles after orchiectomy are the same. In a systematic study, it was observed that in asynchronous testicular tumors, if the primary tumor pathology is seminoma, in 68.9% of patients, the pathology of the second tumor is similar to the primary tumor.

The need for screening of the opposite testicular biopsy in patients who refer with a unilateral testicular tumor has been debated for decades. Given that the incidence of germ cell neoplasia in situ (GCNIS) in the opposite testicle is up to 8.7% and 70% of them progress to testicular cancer over the next 7 years, it can be claimed that a screening biopsy program for all patients who refer with a unilateral testicular tumor can be highly valuable (12).

However, previous studies have shown that bilateral tumors with asynchronous onset usually have a good prognosis (11), which may call into question the need for a patient with unilateral testicular tumor to undergo a biopsy of the opposite testicle. We did not perform such a treatment program for our patient, even with a history of bilateral undescended testicle, and we followed up the patient periodically from the time of the onset of the primary tumor, which led to the diagnosis of the second tumor in the early stages and proper treatment was provided for the patient.

As a general conclusion, we suggest that patients with a history of risk factors, especially bilateral undescended testicle, be followed up until an age above the normal age for testicular tumor. Moreover, if a unilateral tumor is diagnosed, do not leave the patient after treatment and follow the patient regularly for the occurrence of a tumor in the opposite testicle. Due to the well-reported prognosis for bilateral testicular tumors with asynchronous occurrence in previous studies, biopsy of the opposite testicle is not necessary at the time of primary tumor diagnosis and the same treatment can be achieved with proper follow-up.

Acknowledgment

We would like to thank Ms. Sakineh Kamali Ahangar, an expert in the Clinical Research

Development Unit of Shahid Beheshti Hospital in Babol.

References

1. Cuni Xh, Haxhiu I, Telegrafi Sh, Berisha M, Rexha N, Myftari M, et al. Metachronous Testicular Seminoma After Testicular Tumor. *Gulf J Oncolog.* 2018;1(27):78-81.
2. Sarıcı H, Telli O, Eroğlu M. Bilateral testicular germ cell tumors. *Turk J Urol.* 2013;39(4):249-52.
3. Goel P, Rawat JD, Wakhlu A, Kureel SN. Undescended testicle: an update on fertility in cryptorchid men. *Indian J Med Res.* 2015;141(2):163-71.
4. Schneuer FJ, Holland AJ, Pereira G, Jamieson S, Bower C, Nassar N. Age at surgery and outcomes of an undescended testis. *Pediatrics.* 2016;137(2):e20152768.
5. Boisen KA, Kaleva M, Main KM, Virtanen HE, Haavisto A-M, Schmidt IM, et al. Difference in prevalence of congenital cryptorchidism in infants between two Nordic countries. *Lancet.* 2004;363(9417):1264-9.
6. Lip SZ, Murchison LE, Cullis PS, Govan L, Carachi R. A meta-analysis of the risk of boys with isolated cryptorchidism developing testicular cancer in later life. *Arch Dis Child.* 2013;98(1):20-6.
7. Hutson JM, Balic A, Nation T, Southwell B. Cryptorchidism. *Semin Pediatr Surg.* 2010;19(3):215-24.
8. Chan E, Wayne C, Nasr A; FRCSC for Canadian Association of Pediatric Surgeon Evidence-Based Resource. Ideal timing of orchiopexy: a systematic review. *Pediatr Surg Int.* 2014;30(1):87-97.
9. Kolon TF, Anthony Herndon CD, Baker LA, Baskin LS, Baxter CG, Cheng EY, et al. Evaluation and treatment of cryptorchidism: AUA guideline. *J Urol.* 2014;192(2):337-45.
10. Wang F, Roberts SM, Butfiloski EJ, Morel L, Sobel ES. Acceleration of autoimmunity by organochlorine pesticides: a comparison of splenic B-cell effects of chlordecone and estradiol in (NZBxNZW) F1 mice. *Toxicol Sci.* 2007;99(1):141-52.
11. Zequi SD, Da Costa WH, Santana TB, Favaretto RL, Sacomani CA, Guimaraes GC. Bilateral testicular germ cell tumours: a systematic review. *BJU Int.* 2012;110(8):1102-9.
12. Hoei-Hansen CE, Holm M, Rajpert-De Meyts E, Skakkebaek NE. Histological evidence of testicular dysgenesis in contralateral biopsies from 218 patients with testicular germ cell cancer. *J Pathol* 2003;200(3): 370-4.