Journal of
Babol University of Medical Sciences
JBUMS
e-ISSN: 2251-7170 p-ISSN: 1561-4107

Cephalometric Assessment of Pharyngeal Airway Space Changes in Patients Undergoing Simultaneous Orthognathic Surgery: A Pre- and Postoperative Comparison of Mandibular Setback and Maxillary Advancement

J. Mohammadi (DDS, MS)[1], A. Gosili (DDS, MS)[2], A. Asalforoush Rezaiye (DDS, MS)[1], P. Mohammadi (DDS, MS)[*3,4]

1.Department of Oral and Maxillofacial Surgery, TeMS.c., Islamic Azad University, Tehran, I.R.Iran.
2.Department of Orthodontics, School of Dentistry, Zanjan University of Medical Sciences, Zanjan, I.R.Iran.
3.School of Dentistry, Zanjan University of Medical Sciences, Zanjan, I.R.Iran.
4.Department of Periodontology, School of Dentistry, Gilan University of Medical Sciences, Rasht, I.R.Iran.

[*]Corresponding Author: P. Mohammadi (DDS, MS)
Address: Department of Periodontology, School of Dentistry, Gilan University of Medical Sciences, Rasht, I.R.Iran.
Tel: +98 (13) 33486421. **E-mail:** parisa.mohammadii1376@gmail.com

Article Type
Research Paper

ABSTRACT

Background and Objective: The upper airway and its related muscles are directly or indirectly connected to the maxilla or mandible. The displacement and position of the jaws in orthognathic surgeries affect their position. As a result, it seems necessary to evaluate airway changes after surgical treatments. The aim of this study was to investigate the effects of orthognathic surgeries on airway dimensions in operated patients using cephalograms prepared from them.

Methods: In this cross-sectional study, cephalometric images of 24 patients with Class III malocclusion who had undergone simultaneous mandibular setback and maxillary advancement surgery were evaluated. The patients' airways were assessed using the Arnett-Gunson analysis at three levels—nasopharynx, oropharynx, and hypopharynx—to determine potential changes. Additionally, the mean and standard deviation of various distances—including Aa–Ap, S1a–S1p, and Ba–Bp—were analyzed before and after surgery. Finally, the A+B outcome was measured on the patients' cephalostats, and the correlation of A+B outcome changes with the nasopharynx, oropharynx, and hypopharynx was assessed.

Findings: The mean airway dimensions in the nasopharynx, oropharynx, and hypopharynx before surgery were 12.97±3.93, 9.16±2.85, and 14.45±4.81 mm, respectively. After surgery, these values were 15.83±4.09, 10.66±2.46, and 10.08±2.76 mm, respectively ($p<0.001$, $p<0.045$, and $p<0.001$). The results indicated an increase in the airway space at the nasopharynx and oropharynx levels and, in contrast, a decrease in the airway space at the hypopharynx level following bimaxillary surgery. The correlation results of the studied variables showed that there was a positive and significant correlation between the A+B outcome and the Ba-Bp variable, and a negative and significant correlation was also observed between the A+B outcome and the Aa-Ap and S1a-S1p variables.

Conclusion: The results of the study showed that simultaneous mandibular setback and maxillary advancement surgeries result in an increase in the airway space in the nasopharynx and oropharynx, while the airway space in the hypopharynx decreases.

Received: Mar 9th 2025
Revised: Jun 18th 2025
Accepted: Aug 5th 2025

Keywords: *Cephalometry, Orthognathic Surgery, Mandibular Setback, Maxillary Advancement, Airway Obstruction.*

Cite this article: Mohammadi J, Gosili A, Asalforoush Rezaiye A, Mohammadi P. Cephalometric Assessment of Pharyngeal Airway Space Changes in Patients Undergoing Simultaneous Orthognathic Surgery: A Pre- and Postoperative Comparison of Mandibular Setback and Maxillary Advancement. *Journal of Babol University of Medical Sciences*. 2026; 28: e55.

Copyright © 2026 Babol University of Medical Sciences. Published by Babol University of Medical Sciences. This work is licensed under a Creative Commons Attribution-NonCommercial 4.0 International license (https://creativecommons.org/licenses/by-nc/4.0/). Noncommercial uses of the work are permitted, provided the original work is properly cited.

Introduction

Recent advances in orthognathic surgery have expanded the range of corrective procedures addressing dentofacial deformities, and there is now growing interest in the effects of these surgeries on airway morphology. Numerous cephalometric studies have shown that repositioning the skeletal components of the face—particularly mandibular setback and maxillary advancement—significantly affects the pharyngeal airway space. In general, facial structure is influenced by genetic and environmental factors during growth. If facial structure grows abnormally or disproportionately, the occurrence of dentofacial anomalies becomes inevitable. These anomalies can result from trauma, infection, or other external factors (1). Moreover, dentofacial anomalies can impact mastication and speech (2, 3).

Dentofacial anomalies can be corrected using a combination of orthodontic treatment and orthognathic surgery. Orthognathic surgery is one of the common approaches for correcting these anomalies and has gained considerable popularity in the field of maxillofacial surgery over the past 30 to 40 years (4). Pre-surgical orthodontic treatment is performed with the aim of correcting dental misalignment. Therefore, orthodontics is a prerequisite for surgery, and postoperative orthodontics is also used to achieve greater harmony between the two corrected jaws, improve dental alignment, correct dental rotations, and stabilize the surgical results. If the patient's upper jaw is retruded, this condition is known as "maxillary deficiency," and the patient must undergo maxillary advancement surgery. If the upper jaw is protruded or the patient has "maxillary protrusion," the upper jaw must be set back, a procedure known as "maxillary setback." Additionally, if the lower jaw is retruded or the patient has "mandibular deficiency," the lower jaw must be advanced surgically, which is called "mandibular advancement" (5, 6). If the patient has a protruded lower jaw or "mandibular prognathism," they undergo mandibular setback surgery (7).

Although some studies have shown that changes in pharyngeal airway space (PAS) after orthognathic surgery are not significantly different (8), other studies indicate that in patients with Class II malocclusion, PAS changes are observable at all reference points examined after orthognathic surgery (9). Some studies have also reported that significant changes occur in PAS reference points after maxillary advancement and mandibular setback (10, 11). Research by Shi et al. and Kraivijitkul et al. has shown that mandibular setback surgery may lead to a reduction in oropharyngeal volume and increase the risk of obstructive sleep apnea (OSA), whereas maxillary advancement helps improve the nasopharyngeal airway (12, 13). More recent studies, including those by Hussain et al. and Honglertnapakul et al., have emphasized that changes in airway space after simultaneous mandibular setback and maxillary advancement are influenced by various anatomical factors such as hyoid bone displacement, tongue position, and soft tissue adaptation. However, the question remains whether the benefits of skeletal correction in terms of esthetics and function outweigh the potential risks to airway function, particularly in patients with Class III malocclusion (14, 15).

Findings have shown that orthognathic surgery may lead to a reduction in airway space and predispose patients to sleep apnea (16). Based on these findings, it appears that changes in the facial skeleton can cause impairment in the individual's airway function. Therefore, one of the concerns of orthognathic surgeries is the possibility of disruption in the normal function of the pharyngeal airway (17). Since orthognathic surgery may lead to anatomical changes in the facial skeletal structure, and these changes can lead to functional and incompatible disturbances in the airway and predispose the individual to sleep-related breathing disorders or exacerbate them, evaluation of airway changes after surgical treatment is necessary (18).

One of the methods for evaluating the upper airway is lateral cephalometry, which is considered one of the key tools in orthodontics (19). Morphometric evaluation of the pharyngeal airway space is usually performed using standard cephalometric films by identifying specific reference points and measuring various lengths and areas in the pharyngeal region (20, 21). Lateral cephalometry allows visualization of

hard and soft tissue structures for evaluating anomalies (22). However, the limitation of this method is its two-dimensional nature. For three-dimensional evaluation of the airway, cone beam computed tomography (CBCT) imaging can be used, but unlike cephalometric methods, this technique has a higher cost (23). Nevertheless, several studies have shown that the lateral cephalometry technique is more reliable alongside CBCT in evaluating the airway in patients undergoing orthognathic surgery (24-26). The results of one study showed that orthognathic surgery led to facial symmetry, as no difference was observed between the two groups in this regard. Additionally, in patients with limited and asymmetric airway space, the airway returned to a symmetrical state after surgery. However, a reduction in oropharyngeal space was observed after surgery in these patients (26). The aim of the present study is to quantitatively evaluate changes in the pharyngeal airway space in patients undergoing simultaneous mandibular setback and maxillary advancement using lateral cephalometric radiography before and after surgery.

Methods

This cross-sectional study was conducted after approval by the Ethics Committee of Zanjan University of Medical Sciences under code IR.ZUMS.REC.1400.040, on patients who had undergone correction of Class III skeletal malocclusion via orthognathic surgery, including maxillary advancement and mandibular setback, at Bu-Ali Hospital in Tehran. Sampling was performed by systematic random sampling from medical records, and a total of 24 eligible patients were selected. Power analysis confirmed the adequacy of this sample size for detecting significant changes in pharyngeal airway space before and after surgery, based on previous studies (27). The inclusion criteria consisted of lateral cephalometric radiography of acceptable quality, at two time points—before surgery and one week after it—in patients aged 20 to 35 years with Class III malocclusion. Image quality was assessed, including natural head position and sufficient clarity of soft and hard tissues. The exclusion criteria consisted of the presence of postoperative complications, a history of upper respiratory diseases, craniofacial syndromes, previous surgeries of the head and neck region, and a body mass index (BMI) greater than 30. Ultimately, 24 patients entered the analysis stage. The data analysis method is presented in Figure 1, and the cephalometric reference points are presented in Table 1.

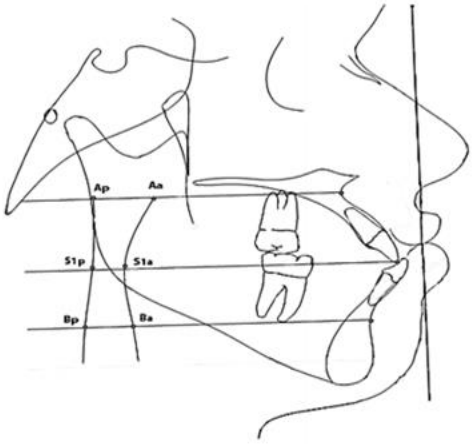

Figure 1. Arnett and Gunson airway analysis

For each lateral cephalometric radiograph, a code was assigned. Transparent tracing paper (Acetat Great Lake) measuring 10x8 cm was placed 1 cm from the left margin and taped to the radiograph with three pieces of adhesive tape. Manual tracing with a black pencil was performed by a trained individual to draw

the contours of the soft and hard tissues, and the corresponding landmarks were identified. Copies of the tracing paper were made, and the points B, S1, A, as well as the orbital and porion points were marked. Lines parallel to the Frankfurt plane (Po-Or) were drawn through the points A, B, and S1. In this setup, the nasopharynx includes the linear distance between the anterior point A and the posterior point A, the oropharynx the linear distance between the anterior point S1 and the posterior point S1, and the hypopharynx the linear distance between the anterior point B and the posterior point B. The variable sum of A+B was measured on the cephalostats of the patients. The procedure was carried out as shown in Figure 2. A line was drawn through the Nasion point perpendicular to the Frankfurt axis, and the changes in the displacement of points A and B before and after surgery were measured relative to this line. The A+B result was calculated, and the correlation between this variable and the three airway parameters was evaluated.

Table 1. Cephalometric reference points (landmarks)

Point	Description
A Anterior	The anterior wall of the nasopharynx passing through the skeletal point A.
A Posterior	The posterior wall of the nasopharynx passing through the skeletal point A.
S1Anterior	The anterior wall of the oropharynx passing through the tip of the upper incisor (S1).
S1 Posterior	The posterior wall of the oropharynx passing through the tip of the upper incisor (S1).
B Anterior	The anterior wall of the hypopharynx passing through the skeletal point B.
B Posterior	The posterior wall of the hypopharynx passing through the skeletal point B.

Skeletal Point A: The innermost point on the anterior contour of the premaxilla (upper jaw), located between the anterior nasal spine and the maxillary incisor teeth. Skeletal Point B: The innermost point on the anterior contour of the mandible, located between the mandibular incisor teeth and the chin (Menton). Orbital Point: The lowest point on the inferior margin of the orbit. Porion Point: The central point on the upper margin of the external auditory canal.

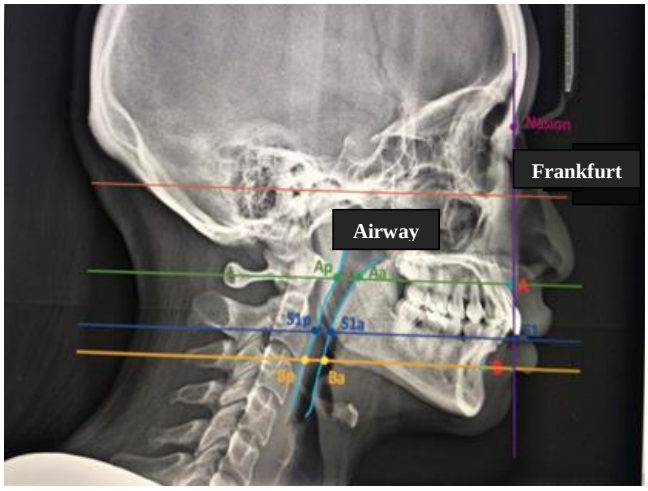

Figure 2. Method of measuring the A+B variable

Lateral cephalometric radiographs were used to collect data. A paired T-test was used to analyze changes before and after surgery, and Pearson's correlation test was used to investigate the relationship between variables. All statistical analyses were performed using R software version 4.01 and SPSS, and $p < 0.05$ was considered significant.

Results

The changes in the means, standard deviations, and p-values of the various parameters measured before and after surgery are summarized in Table 2. The mean value of the Aa-Ap distance (the distance between the anterior and posterior walls of the nasopharynx at point A) significantly increased from 12.97±3.93 mm before surgery to 15.83±4.09 mm after surgery. The S1a-S1p parameter (the distance between the anterior and posterior walls of the oropharynx at point S1) also showed a significant change, such that its mean increased from 9.16±2.85 mm before surgery to 10.66±2.46 mm after surgery. In contrast, the Ba-Bp variable (the distance between the anterior and posterior walls of the hypopharynx at point B) demonstrated a significant decrease, from 14.45±4.81 mm before surgery to 10.08±2.76 mm after surgery.

Table 2. Comparison of the mean values of the Aa-Ap, S1a-S1p, and Ba-Bp variables before and after surgery in the study subjects

Variable	n	Before surgery Mean±SD	Before surgery (minimum)	Before surgery (maximum)	After surgery Mean±SD	After surgery (minimum)	After surgery (maximum)	p-value*
Aa-Ap	24	12.97±3.93	6	20	15.83±4.09	8	22	<0.001
S1a-S1p	24	9.16±2.85	4	13	10.66±2.46	6	15	<0.045
Ba-Bp	24	14.45±4.81	7	25	10.08±2.76	6	14	<0.001

***P-values indicate statistically significant differences between values before and after surgery (p<0.05)**

Statistical analysis revealed that the p-value for the Aa-Ap (Figure 3) and Ba-Bp (Figure 4) variables was <0.001, indicating a highly significant difference between values before and after surgery. Additionally, the S1a-S1p variable also showed a statistically significant increase (p=0.045) (Figure 5). However, the magnitude of this change was smaller compared to the other variables. The extent of changes varied among the different study subjects. For example, in subject number 17, the Aa-Ap value was 14 mm before surgery and increased to 22 mm after surgery; in subject number 12, the S1a-S1p value increased by 5 mm after surgery; and in subject number 3, the Ba-Bp value was 17 mm before surgery and decreased to 14 mm after surgery. The Pearson correlation coefficient was calculated using SPSS software, and its heat map was drawn using R software (Figure 6).

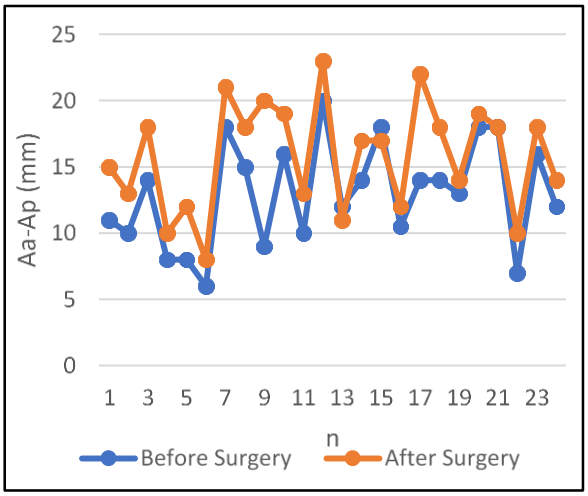

Figure 3. The rate of Aa-Ap changes in the study subjects before and after surgery

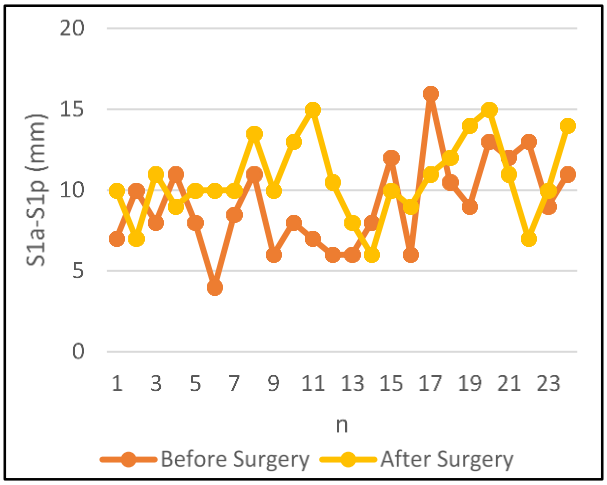

Figure 4. S1a-S1p changes in case study subjects before and after surgery

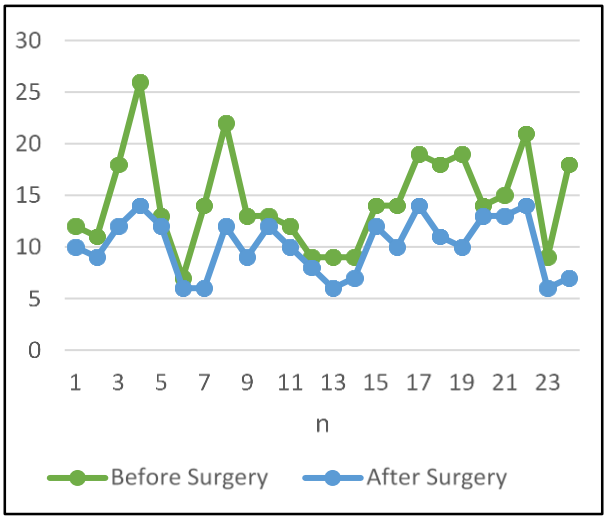

Figure 5. The rate of Ba-Bp changes in the study subjects before and after surgery

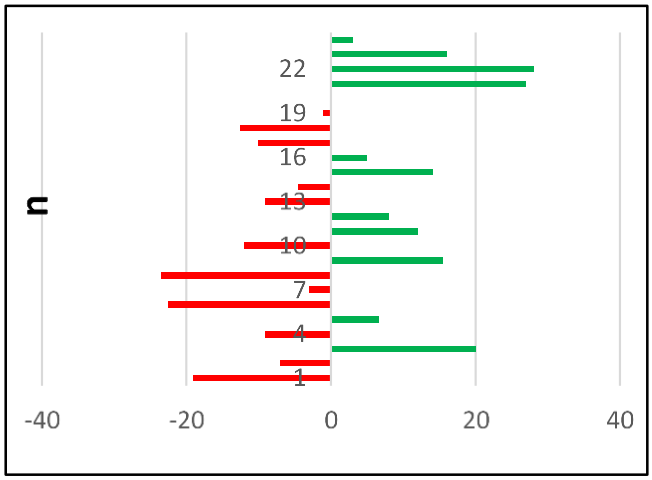

Figure 6. Outcome of points A and B for the study subjects after surgery

The correlation results of the studied variables showed that there was a positive and significant correlation between the A+B outcome and the Ba-Bp variable at the 5% probability level. That is, the more negative the A+B outcome value was, the lower the Ba-Bp value became. Additionally, a negative and significant correlation was observed between the A+B outcome and the Aa-Ap and S1a-S1p variables (Figure 7).

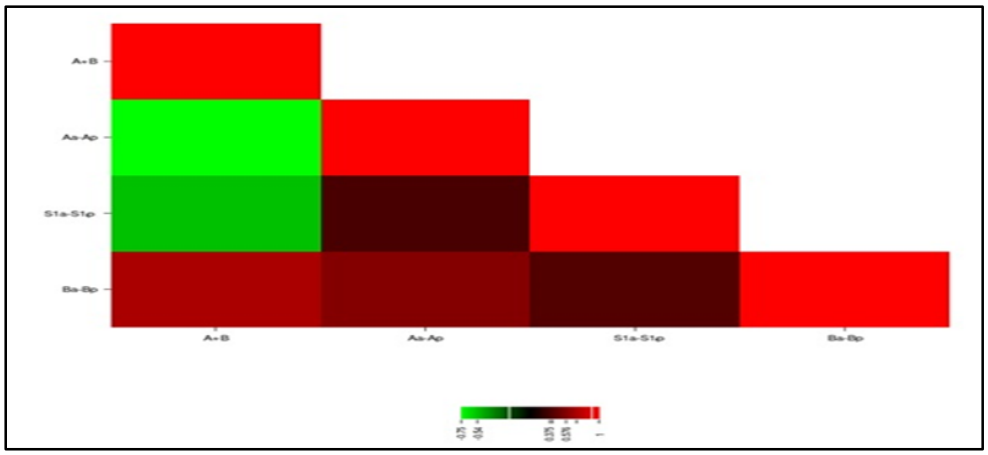

Figure 7. Correlation of the A+B outcome with the three variables Aa-Ap, S1a-S1p, and Ba-Bp in the study subjects before and after surgery

Discussion

The most important finding of this study was a statistically significant increase in the airway space in the nasopharynx and oropharynx, and in contrast, a decrease in the airway space in the hypopharynx following bimaxillary surgery, including maxillary advancement and mandibular setback. This indicates that surgical movements have differential effects on different segments of the airway. The results have shown that orthognathic surgery can have positive effects on the upper airway, and even with technical differences in surgical methods, changes in jaw position directly affect the airway space. In fact, these changes can improve the nasopharyngeal and oropharyngeal space and consequently facilitate breathing; particularly in patients suffering from respiratory disorders such as sleep apnea, it can have significant effects on their quality of life and respiratory function and reduce the risks arising from sleep-related breathing problems (28). Therefore, orthognathic surgeries are beneficial not only for correcting the aesthetic problems of the jaws and teeth but also for improving respiratory function and the quality of life of patients with respiratory disorders.

Previous studies have reported different results regarding airway changes following bimaxillary surgeries, such that the study by Turnbull et al. showed that maxillary advancement surgery and mandibular setback surgery significantly change the airway space of patients, such that the airway space in patients increases following surgery (29), which is probably because the extent of maxillary advancement during surgery is greater than mandibular setback. On the other hand, some studies have shown that bimaxillary orthognathic surgeries are not associated with any change in airway space. The studies by Panou et al. and also Aydemir et al. showed that following bimaxillary orthognathic surgeries, no change is created in the airway space in the oropharynx and hypopharynx (30, 31). Tepecik et al. also showed that following bimaxillary surgery, the airway space decreased only in the oropharynx, whereas the airway space in the nasopharynx and hypopharynx did not change significantly (32). According to the study by Chen et al.,

patients who undergo bimaxillary surgery do not show any change in airway space in the long term (33), which is probably because the displacement of the maxilla and mandible during surgery is such that they neutralize each other's effects, and maxillary advancement compensates for the effect of mandibular setback surgery.

In contrast, in this study, a significant decrease was observed in the hypopharyngeal space, which is consistent with the findings of Dain et al. and Chen et al. (16, 33) and is probably due to the posterior and inferior displacement of the hyoid bone and related laryngeal structures following mandibular setback surgery. The results of our study showed that the airway space in the nasopharynx, oropharynx, and hypopharynx changed significantly in patients undergoing simultaneous bimaxillary surgery, such that the space in the nasopharynx and oropharynx increases and, in the hypopharynx, decreases. Considering that maxillary advancement surgery probably has little effect on the hypopharynx, therefore, in the results of our study, according to the above, it was shown that following bimaxillary surgery, due to mandibular setback, the hypopharyngeal airway space will still decrease.

In this study, the outcome of the two jaws' movement (A+B) was also used as an indicator for quantifying skeletal displacement during surgery, which was one of the strengths of our study. When this outcome becomes negative, meaning that the extent of mandibular setback was greater than maxillary advancement, and consequently, a greater decrease in the hypopharyngeal space was observed. In contrast, positive A+B values indicate the predominance of maxillary forward movement, and consequently, it was associated with a lesser decrease in the hypopharyngeal space. Therefore, the greatest correlation between the two jaws' outcome was observed in the hypopharynx. These findings emphasize the importance of carefully evaluating the pattern of jaw movement before surgery and indicate that, if possible, excessive mandibular setback should be avoided to prevent its negative effects on airway patency.

One of the important limitations of this study is the use of two-dimensional lateral cephalometric radiography for airway evaluation. Considering that the upper airway is a complex, three-dimensional structure divided into the three aforementioned parts, it is recommended that future studies use three-dimensional imaging methods such as CBCT or MRI for more accurate analysis of airway space volume, which are more reliable. Additionally, conducting studies on patients with chronic respiratory problems and evaluating how bimaxillary surgery affects these patients could be useful. It is recommended that after surgery, a questionnaire also be prepared and patients' satisfaction regarding improvement or lack thereof be surveyed.

The results of this study show that bimaxillary surgery, including mandibular setback and maxillary advancement, leads to an increase in the airway space in the nasopharynx and oropharynx, while the hypopharyngeal space decreases. These findings also highlight the compensatory role of the maxilla in reducing the negative effect of mandibular setback on the airway.

Conflicts of Interest: The authors of this article declare that there are no financial, scientific, or personal conflicts of interest regarding the conduct of this research.

Acknowledgment

We hereby express our gratitude to the Vice-Chancellor for Research and Technology of Zanjan University of Medical Sciences for supporting the research, as well as to the surgical team of Bu-Ali Hospital in Tehran for their valuable support and cooperation in conducting this research.

References

1.Grippaudo C, Paolantonio EG, Antonini G, Saulle R, La Torre G, Deli R. Association between oral habits, mouth breathing and malocclusion. Acta Otorhinolaryngol Ital. 2016;36(5):386-94.

2.He J, Wang Y, Hu H, Liao Q, Zhang W, Xiang X, et al. Impact on the upper airway space of different types of orthognathic surgery for the correction of skeletal class III malocclusion: A systematic review and meta-analysis. Int J Surg. 2017;38:31-40.

3.Lee CH, Park HH, Seo BM, Lee SJ. Modern trends in Class III orthognathic treatment: A time series analysis. Angle Orthod. 2017;87(2):269-78.

4.Jandali D, Barrera JE. Recent advances in orthognathic surgery. Curr Opin Otolaryngol Head Neck Surg. 2020;28(4):246-50.

5.Abbassi S, Tajbakhsh N. Prevalence of Dental Anomalies in Adult Orthodontic Patients with Oral Radiological Point: A Systematic Review. Sudan J Med Sci. 2025;20(1):99-111.

6.Reyneke JP, Ferretti C. Diagnosis and treatment planning for orthognathic surgery. In: Andersson L, Krishnan DG, Peacock ZS, editors. Oral and maxillofacial surgery, 2nd ed. Wiley; 2025. p. 927-64.

7.Kim CS, Lee SC, Kyung HM, Park HS, Kwon TG. Stability of mandibular setback surgery with and without presurgical orthodontics. J Oral Maxillofac Surg. 2014;72(4):779-87.

8.Göymen M, Mourad D, Güleç A. Evaluation of Airway Measurements in Class II Patients Following Functional Treatment. Turk J Orthod. 2019;32(1):6-10.

9.do Vale F, Rodrigues ML, Francisco I, Roseiro A, Santos I, Caramelo F, et al. Short-term pharyngeal airway space changes after mandibular advancement surgery in Class II patients-a two-dimensional retrospective study. Orthod Craniofac Res. 2019;22(2):81-6.

10.Yamashita AL, Iwaki LCV, Pinto GNS, Gerke BA, Chicarelli M, Iwaki Filho L. Accuracy of two-dimensional pharyngeal airway space prediction for bimaxillary orthognathic surgery. Oral Maxillofac Surg. 2018;22(2):197-202.

11.Pereira-Filho VA, Castro-Silva LM, de Moraes M, Gabrielli MF, Campos JA, Juergens P. Cephalometric evaluation of pharyngeal airway space changes in class III patients undergoing orthognathic surgery. J Oral Maxillofac Surg. 2011;69(11):e409-15.

12.Shi X, Lobbezoo F, Chen H, Rosenmöller BRAM, Berkhout E, de Lange J, et al. Effects of mandibular advancement devices on upper airway dimensions in obstructive sleep apnea: responders versus non-responders. Clin Oral Investig. 2023;27(9):5649-60.

13.Kraivijitkul S, Rochanavibhata S, Changsiripun C, Sinpitaksakul P, Chirakalwasan N, Kongsong W. The effects of mandibular setback surgery on the upper airway and sleep quality in skeletal Class III patients and comparison with control subjects: a pilot study. Int J Oral Maxillofac Surg. 2025;54(7):607-16.

14.Hussain R, Chen I, Hsu JT, Huang PW, Chen YC, Yu JH, et al. Alterations in upper airway dimensions following bimaxillary and mandibular setback surgery in skeletal Class III patients: A cone-beam computed tomography study. J Dent Sci. 2025;20(3):1673-80.

15.Honglertnapakul Y, Peanchitlertkajorn S, Likitkulthanaporn A, Saengfai NN, Chaweewannakorn C, Boonpratham S. Impacts of mandibular setback with or without maxillary advancement for class III skeletal correction on sleep-related respiratory parameters: A systematic review and meta-analysis. Orthod Craniofac Res. 2024;27(6):839-52.

16.Dain CP, Thomas JP. The Bioadaptive Changes in the Pharyngeal Airway and Hyoid Position Following Mandibular Setback Surgery: A Cephalometric Study. J Sleep Disord Ther. 2020;9(6):321.

17.Yang Y, Yang K, Zhao Y. Three-Dimensional Changes in the Upper Airway of Skeletal Class III Patients After Different Orthognathic Surgical Procedures. J Oral Maxillofac Surg. 2018;76(1):155-64.

18.Sahoo NK, Agarwal SS, Datana S, Bhandari SK. Quantifying Upper Airway Changes Following Mandibular Orthognathic Surgery. J Craniofac Surg. 2021;32(2):569-73.
19.Devereux L, Moles D, Cunningham SJ, McKnight M. How important are lateral cephalometric radiographs in orthodontic treatment planning? Am J Orthod Dentofacial Orthop. 2011;139(2):e175-81.
20.Arun T, Isik F, Sayinsu K. Vertical growth changes after adenoidectomy. Angle Orthod. 2003;73(2):146-50.
21.Martin O, Muelas L, Viñas MJ. Nasopharyngeal cephalometric study of ideal occlusions. Am J Orthod Dentofacial Orthop. 2006;130(4):436.e1-9.
22.Yamashita AL, Iwaki Filho L, da Silva MC, Takeshita WM, Iwaki LC. Effect of orthognathic surgery on pharyngeal airway space: a cephalometric evaluation using Dolphin Imaging software. Acta Scientiarum Health Sci. 2015;37(2):205-9.
23.Van Sofie C, Okkerse W, Brijs G, De Beule M, Braem M, Verhegghe B. 3D cephalometry: a new approach for landmark identification and image orientation. In: Sloten J, Verdonck P, Nyssen M, Haueisen J, editors. 4th European Conference of the International Federation for Medical and Biological Engineering 23-27 November 2008, Antwerp, Belgium. Berlin, Heidelberg: Springer; 2009. p. 1442-5.
24.Marşan G, Vasfi Kuvat S, Oztaş E, Cura N, Süsal Z, Emekli U. Oropharyngeal airway changes following bimaxillary surgery in Class III female adults. J Craniomaxillofac Surg. 2009;37(2):69-73.
25.Giap HV, Shin JW, Chae HS, Kim YH, Paeng JY, Choi HW. Pharyngeal Airway Morphology in Skeletal Class III With Mandibular Asymmetry is Improved After Bimaxillary Orthognathic Surgery. J Oral Maxillofac Surg. 2021;79(5):1107-21.
26.Candido MS, Monnazzi MS, Gabrielli MA, Spin-Neto R, Gabrielli MF, Pereira-Filho VA. Pharyngeal airway space cephalometric evaluation in transverse maxillary deficient patients after SARME. Braz J Oral Sci. 2014;13(4):288-91.
27.Manni A, Pasini M, Giuca MR, Morganti R, Cozzani M. A retrospective cephalometric study on pharyngeal airway space changes after rapid palatal expansion and Herbst appliance with or without skeletal anchorage. Prog Orthod. 2016;17(1):29.
28.Giralt-Hernando M, Valls-Ontañón A, Haas Junior OL, Masià-Gridilla J, Hernández-Alfaro F. What are the Surgical Movements in Orthognathic Surgery That Most Affect the Upper Airways? A Three-Dimensional Analysis. J Oral Maxillofac Surg. 2021;79(2):450-62.
29.Turnbull NR, Battagel JM. The effects of orthognathic surgery on pharyngeal airway dimensions and quality of sleep. J Orthod. 2000;27(3):235-47.
30.Panou E, Motro M, Ateş M, Acar A, Erverdi N. Dimensional changes of maxillary sinuses and pharyngeal airway in Class III patients undergoing bimaxillary orthognathic surgery. Angle Orthod. 2013;83(5):824-31.
31.Aydemir H, Memikoğlu U, Karasu H. Pharyngeal airway space, hyoid bone position and head posture after orthognathic surgery in Class III patients. Angle Orthod. 2012;82(6):993-1000.
32.Tepecik T, Ertaş Ü, Akgün M. Effects of bimaxillary orthognathic surgery on pharyngeal airway and respiratory function at sleep in patients with class III skeletal relationship. J Craniomaxillofac Surg. 2018;46(4):645-53.
33.Chen F, Terada K, Hua Y, Saito I. Effects of bimaxillary surgery and mandibular setback surgery on pharyngeal airway measurements in patients with Class III skeletal deformities. Am J Orthod Dentofacial Orthop. 2007;131(3):372-7.