



## Pulmonary Atresia and Intact Ventricular Septum in Transcatheter Perforation of Atrietic Pulmonary Valve

M. K. Shukur Alghanimi (MD)<sup>1</sup> , H. A. Alsalkhi (MD)<sup>\*2</sup> , M. F. Alkhafaji (MD)<sup>3</sup>

1.Department of Pediatric Cardiology, College of Medicine, Babylon University, Babylon, Iraq.

2.Department of Pediatric Cardiology, College of Medicine, Kufa University, Najaf, Iraq.

3.Department of Cardiothoracic Surgery, Shaheed Almehrhab Cardiac Surgery and Catheterization, Babylon, Iraq.

---

### Article Type ABSTRACT

---

#### Research Paper

**Background and Objective:** The use of mechanical perforation as an alternative to radiofrequency wire in the treatment of pulmonary valve atresia with an intact ventricular septum, which is a duct-dependent cyanotic congenital heart disease. We share our experience with this method, which is especially relevant for centers that do not have access to radiofrequency wires.

**Methods:** This cross-sectional study was conducted between October 2011 and August 2022 on all infants referred to Shaheed Almehrhab cardiac surgery and Catheterization Center in Babylon, Iraq whose severe cyanosis and patent ductus arteriosus (PDA) dependent pulmonary valve atresia with an intact ventricular septum were confirmed by transthoracic echocardiography. A chronic total occlusion (CTO) wiring procedure was used to create perforation through the atrietic pulmonary valve with subsequent pulmonary valve balloon dilation, through an antegrade (n=18) or retrograde approach (n=10).

**Findings:** A total number of 28 infants with 14 infants younger than one month and 14 infants older than one month of age were included. 15 cases (53%) were male. The mean oxygen saturation before the intervention was 44.48±7.43% which significantly improved to 88.35±7.71% (p<0.001). Tripartite ventricles were found in 56.5% of patients. Successful perforation with subsequent balloon valvuloplasty was achieved in 23 cases (82.1%) and death as a complication of perforation was reported in 5 cases. The antegrade operation was associated with higher survival than the retrograde (p=0.041). There were 21.5% of patients who required an additional procedure including a bidirectional cavopulmonary shunt (Glenn shunt) or Blalock-Taussig (BT) shunt to augment pulmonary blood flow. Tricuspid regurgitation improvement was confirmed in 87% of patients.

**Conclusion:** In conclusion, transcatheter perforation of atrietic pulmonary valves followed by balloon valvuloplasty is a feasible and effective treatment option for pulmonary atresia and intact ventricular septum.

**Keywords:** *Pulmonary Valve Atresia, Ventricular Septum, Balloon Valvuloplasty, Transcatheter Procedures, Congenital Heart Defects.*

#### Received:

Mar 7<sup>th</sup> 2023

#### Revised:

Apr 30<sup>th</sup> 2023

#### Accepted:

May 31<sup>st</sup> 2023

---

**Cite this article:** Shukur Alghanimi MK, Alsalkhi HA, Alkhafaji MF. Pulmonary Atresia and Intact Ventricular Septum in Transcatheter Perforation of Atrietic Pulmonary Valve. *Journal of Babol University of Medical Sciences*. 2023; 25(1): 356-64.



© The Author(S).

Publisher: Babol University of Medical Sciences

---

**\*Corresponding Author: H. A. Alsalkhi (MD)**

**Address:** Department of Pediatric Cardiology, College of Medicine, Kufa University, Najaf, Iraq.

**Tel:** +964 (773) 9201662. **E-mail:** hus.dam@yahoo.com

## Introduction

Pulmonary atresia with intact ventricular septum (PAIVS) is a complex congenital malformation of the heart that is reported for 2-3 % of all congenital heart diseases. It is slightly common in males and usually presents as neonatal cyanosis, which is always fatal if untreated (1, 2). PAIVS is a heterogeneous disease featured by the complete absence of right ventricular outflow with ductal-dependent pulmonary circulation and intact ventricular septum beside varying degrees of the right ventricle and tricuspid valve hypoplasia and anomalies of the coronary circulation. PAIVS can be classified according to the type of pulmonary valve atresia (membranous 75% and muscular 25%), degree of right ventricle hypoplasia (tripartite, bipartite, and unipartite), tricuspid valve Z-score (more than -2 usually associated with the favorable outcome) and presence and complexity of coronary circulation abnormalities (3, 4). A careful analysis of these anatomical variations is crucial to determining whether to perform single or biventricular repairs and whether to use a surgical or transcatheter approach (5-7). A study by El Shedoudy et al. suggests that mechanical perforation may be a viable alternative in centers without access to radiofrequency wire (8). In a study, valve opening was successfully performed using a special guidewire and balloon dilatation (9). In another study, the retrograde approach was found to be faster and provided similar outcomes compared to the antegrade approach (10). Another study reported percutaneous treatment of pulmonary atresia and intact ventricular septum in 15 patients. The technique was highly successful and can lead to good outcomes in patients with this condition (11). In previous years, there has been a noticeable development in the transcatheter management of anatomically favorable PAIVS cases through perforation of the atretic pulmonary valve using different techniques like laser, radiofrequency, and percutaneous coronary (PCI) guide wires (12-21). Thus, the rationale for this study is to explore the use of mechanical perforation as an alternative method to radiofrequency wire for the treatment of pulmonary valve atresia with an intact ventricular septum, a condition that is duct-dependent and leads to cyanosis. The study aims to share the experience of using this method, which can be particularly relevant for centers that do not have access to radiofrequency wires. In this article, we describe our experience of transcatheter perforation of the atretic pulmonary valve utilizing different types of PCI guide wires.

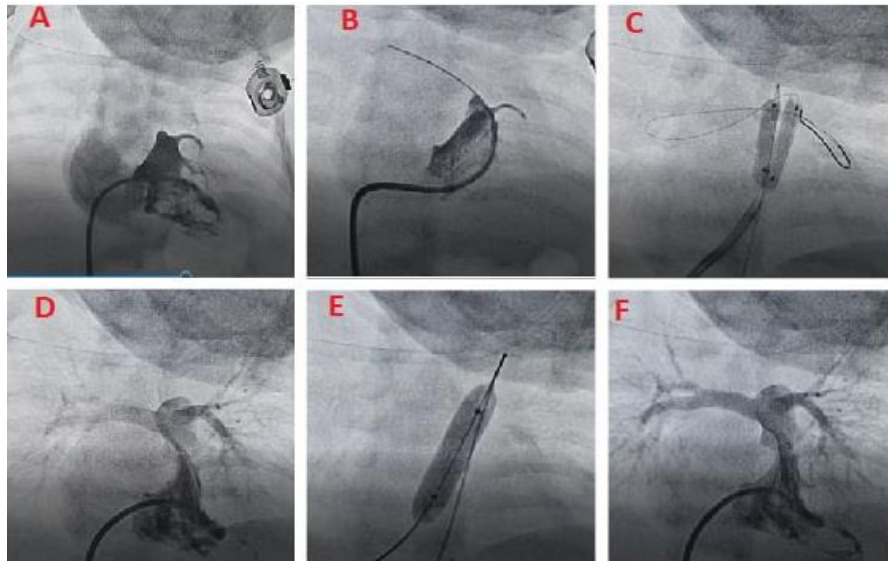
## Methods

The ethical committee for the clinical studies at Faculty of Medicine, University of Kufa has approved the study with the code BU144:03-11-2022 .

This was a case series study, conducted at a single center, Shaheed Almehrab cardiac surgery and Catheterization Center in Babylon, Iraq, from October 2011 to August 2022, on the records of patients with PAIVS. All personal information of patients remained confidential. All methods were carried out in accordance with relevant guidelines and regulations.

Patients with PAIVS were selected based on census sampling. Inclusion criteria were diagnosis of PAIVS based on transthoracic echocardiography, undergoing cardiac catheterization for atretic pulmonary valve perforation using different percutaneous coronary intervention (PCI) wires, and availability of medical record data. Patients without such criteria were not eligible for inclusion.

**Procedures:** Cardiac catheterization for atretic pulmonary valve perforation using different percutaneous coronary intervention (PCI) wires either through antegrade, Figure 1 or retrograde, Figure 2 approaches.



**Figure 1. PCI wires through antegrade.** A. RV angiogram shows tripartite RV cavity with severe TR and atretic PV, B. Perforation of atretic PV, C. Double PCI balloon dilation of atretic PV, D. PA angiogram shows forward flow, E. More dilation of the valve with a larger balloon depending on the measured annulus, F. Good flow through the dilated pulmonary valve with changing of TR severity to mild.

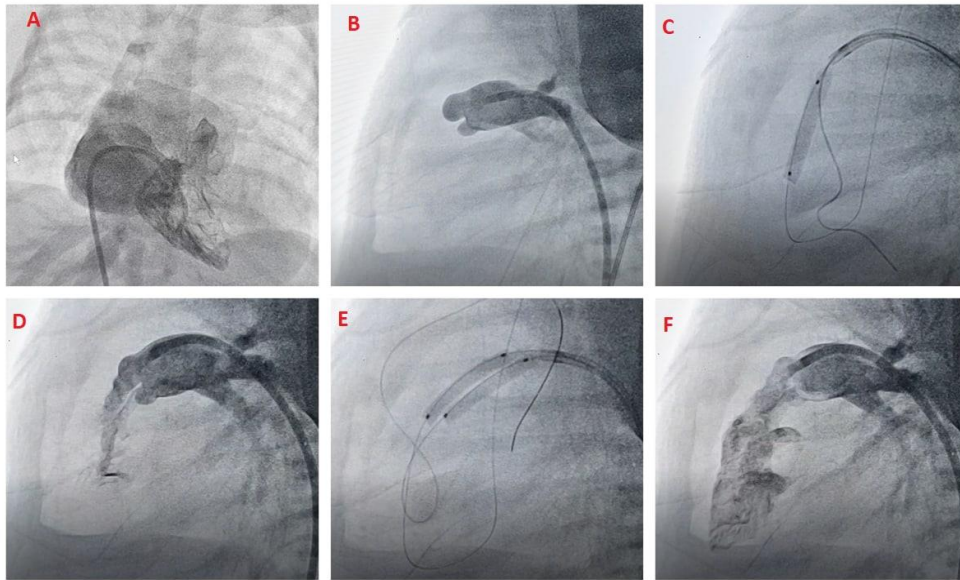
Informed consent was obtained from the patient's family for a high-risk procedure under general anesthesia and all approaches were done based on the standard guidelines and regulations of the ethical committee for the clinical studies at the Faculty of Medicine, University of Kufa. A right femoral venous line (6F or 5F) and an arterial line (5F) were introduced.

A JR (4, 5, or 6F) catheter was passed from the femoral vein to the right atrium and then across the tricuspid valve to reach the right ventricle. Due to severe tricuspid valve regurgitation, small TV, large RA, and severe RV hypertrophy or hypoplasia, it is sometimes difficult to pass along that route. Some technical tricks are necessary to enter the RV and stabilize the catheter position. Sometimes we make multiple loops of the catheter in the RA and rotate it in clockwise and anti-clockwise directions to get entry to the RV chamber, change the catheter to a larger or smaller size to get a better chance of crossing the TV, and get a suitable location in the RV or obtain an angiogram of the RA in AP view to detect the inflow into the RV chamber. The right ventricular angiogram in anterior-posterior and lateral views was performed to determine the RV size and anatomy, the coronary artery sinusoidal connection, the tricuspid valve regurgitation degree, and the level of the pulmonary valve (Figures 1A and 2A). The catheter was then moved in the clockwise direction to pass to the level of the pulmonary valve and fix it in the dimple of the atretic valve (Figure 1B).

In lateral view, an angiogram in descending aorta was performed to assess the anatomy of the PDA and the pulmonary arteries. With an antegrade approach, the JR catheter is maneuvered to the infundibulum and positioned against the atretic pulmonary valve with frequent angiograms from a side arm back bleed device to find the appropriate position that is close to the PV; then the PCI wire (Cross-it 200 or 300 ATM) is advanced to the PV multiple times using torque and gently pushed to cause the perforation of the valve (Figure 1B). The operator should be well-oriented for the course of the wire to pulmonary artery branches (and not to the pericardium).

Occasionally, the wire passes to the PA, then to the PDA and descending aorta. Snaring is done from the descending aorta, providing more stability for the wire and allowing for easier balloon manipulation. As

soon as perforation was achieved, a 1.5mm\*20mm PCI balloon was passed over the wire and inflated in the pulmonary valve area. Serial balloons were inflated with PCI balloons (2.5mm\*2cm, 3mm\*2cm or 3.5mm\*2cm) and TYSHAK balloons (5mm, 6mm, 7mm and 8mm\*2cm) until a full dilation was obtained, as indicated by a measured annulus (Figure 1E). The final balloon size was 20% larger than the measured annulus. Finally, an RV angiogram was performed to estimate the result of PV dilation and the degree of TV regurgitation (Figure 2).



**Figure 2. PCI wires through the retrograde. A. RV angiogram with severe TR, B. Retrograde angiogram through PDA to PA near atretic PV, C. Retrograde perforation of PV with double wires and balloon dilation, D. Retrograde PA angiogram with flow through the valve to infundibulum, E. Double PCI balloon dilation of the valve, F. Good flow retrogradely from dilated atretic valve to RV.**

Demographic information, right ventricle (RV) anatomy (bipartite or tripartite), approach (antegrade or retrograde), death rate, total oxygen saturation (%) pre-operation and post-operation, type of wire, and level of tricuspid regurgitation were recorded according to the documents.

The statistical analysis was conducted based on the SPSS version 27. While this was a description of a small-sized sample of patients, we used analytical evaluations for a better understanding. The categorical parameters were considered as frequencies and percentages, and continuous ones were reported as mean and SD. Paired t-test was used to evaluate the means of two paired readings. Cross-tabulation was performed using the Chi-square test. A p-value  $\leq 0.05$  was regarded as statistically significant.

## Results

A total of 28 neonates and infants with membranous pulmonary valve atresia, bipartite or tripartite right ventricle, and the intact ventricular septum, of whom 14 were below one month and 14 were above one month, with a small difference in gender (15 males and 13 females) were evaluated. In most cases (64.3%), the procedure was performed antegrade, and in the remaining cases (35.7%), it was performed retrogradely. There was a tripartite right ventricle in 57% of patients and a bipartite right ventricle in the remaining patients (Table 1). Twenty-three patients underwent a successful procedure and 5 patients died due to

procedure complications. Valve was successfully perforated in 23 cases (82.1%), and patient death occurred in 5 cases (17.9%), mostly with the retrograde procedure (4 cases vs. one case with the antegrade procedure) (Table 2). The mean oxygen saturation level at presentation was  $44.48 \pm 7.43\%$ , which improved following the procedure to  $88.35 \pm 7.71\%$  (Table 3).

**Table 1. Patients characteristics (n=28)**

Patients characteristics	Distribution Mean±SD or Number(%)
Weight (gram) (2300-6800)	4010.7±1162.5
<b>Age</b>	
<1 month	14(50)
≥1 month	14(50)
Total	28(100)
<b>Gender</b>	
Male	15(53.6)
Female	13(46.4)
Total	28(100)
<b>Right Ventricle (RV) Anatomy</b>	
Bipartite	12(43)
Tripartite	16(57)
Total	28(100)
<b>Approach</b>	
Antegrade	18(64.3)
Retrograde	10(35.7)
Total	28(100)

**Table 2. Association between outcome and route of operation (n=28)**

Outcome of operation	Route of operation		Total Number(%)	p-value
	Antegrade Number(%)	Retrograde Number(%)		
Death	1(5.6)	4(40.0)	5(17.9)	0.041*
Successful operation	17(94.4)	6(60.0)	23(82.1)	
Total	18(100.0)	10(100.0)	28(100)	

\*p-value≤0.05 was significant.

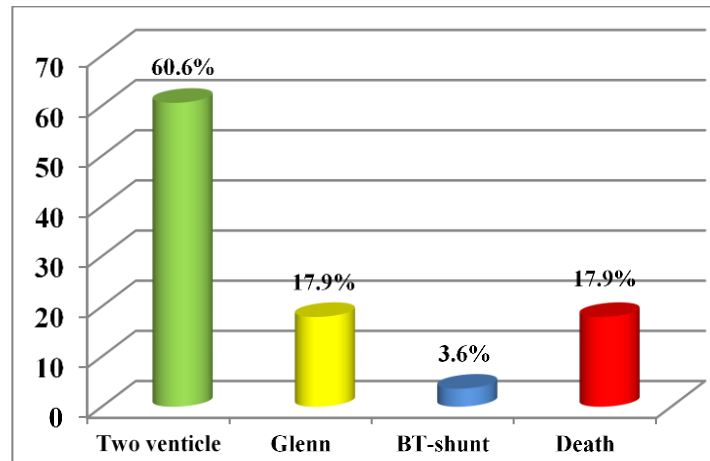
**Table 3. The mean differences in oxygen saturation (%) pre and post-operation (n=23)**

Study variable	Mean±SD	Paired t-test	p-value
<b>Oxygen saturation (%)</b>			
Pre-operation	44.48±7.43	-22.264	<0.001*
Post-operation	88.35±7.71		

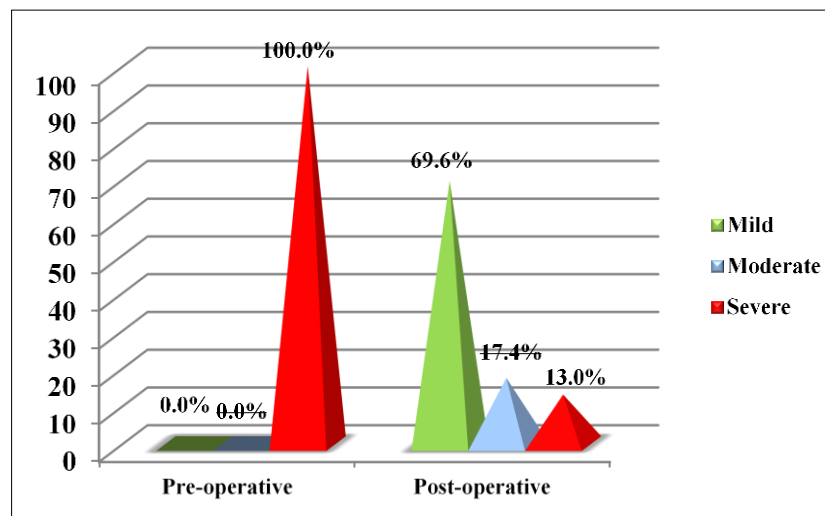
\*p-value≤0.05 was significant.

60% of cases didn't need further catheter or surgical intervention and live with two functioning ventricles while 21.5% of patients needed either BT-shunt or Glenn surgery by age 8 to 9 months due to progressive

desaturation post-procedure on the follow-up period of patients (7-34 months) (Figure 1). All patients had severe tricuspid valve regurgitation, and there was a significant reduction in the degree of TR (69.6%), but it changed to moderate in 17.4% and remained severe in 13% of cases (Figure 2).



**Figure 1. Distribution of patients according to outcome (n=28)**



**Figure 2. Distribution of patients according to tricuspid regurgitation before and after the operation (n=23)**

**Complications:** While wires with other specified applications were used in our study, no thrombosis or rupture of the artery or any procedure-related complication was reported.

## Discussion

Our study demonstrated that transcatheter perforation of atretic pulmonary valves followed by balloon valvuloplasty is a feasible and effective treatment option for pulmonary atresia and intact ventricular septum. In another study, they achieved successful pulmonary valve perforation in 16 of 20 patients and in 6 of them, there was a need for another immediate intervention, such as a patent ductus arteriosus or right

ventricular outflow tract stenting (22), but in our study the successful perforation was achieved in 23 patients (82.1%), using Cross-it PCI (200 and 300) ATM wires.

The study by Çelebi et al. reported success with the antegrade and retrograde approaches in 2 and 1, respectively (23), while in our study the majority of cases [18(64.3%)] were perforated anterogradely, while retrograde perforation was performed in only 10 cases (35.7%). As the right ventricle was either tripartite or bipartite, there was adequate right ventricle chamber space for the catheter to be positioned and faced against the atretic PV. The wire was positioned in the dimple of the valve, making it more stable than if the catheter and wire were retrograde. According to El Shedoudy et al., the procedure was successful in 13 patients (84.6%) and 2 of the patients had died (15.4%), while some patients needed other procedures such as PDA stenting in one case (7.7%), Glenn surgery in another case, and single ventricle surgery in two patients (15.4%), with two patients requiring further balloon dilation sessions (8). Benson et al. used radiofrequency perforations of the PV and reported success in about 87% of cases and complications in 15% with a death rate of about 8%. In addition, 33% of patients required additional pulmonary blood flow (20). In our study, 21.5% of patients needed either BT-shunt (3.6%) or Glenn surgery (17.9%) due to progressive desaturation post-procedure. Despite using tiny wires, five patients died from accidental perforation, which was mostly based on a retrograde approach. Improper catheter advancement in some patients and massive bleeding in others caused a fatal rapid tamponade effusion in severely cyanotic neonates and infants. Bakhru et al. reported successful procedure in 16 of 20 patients; however pericardial tamponade that required aspiration was reported in one patient (22). Therefore, we believe that using the soft end of the PCI wire and placing the catheter gently against the dimple of the atretic PV through the antegrade approach significantly reduces the risk of accidental perforation and subsequent serious cardiac tamponade.

A study by Latson utilized a rigid end of a PCI wire for creating a perforation that was complicated by perforation of the leaflets, RVOT, or PA due to the instability of the catheter and rigid end, thus the success rate was nearly 68% and the mortality was 4%, and an additional procedure to increase pulmonary blood flow was required for 48% of the patients (24). Alwi et al. used the Conquest Pro coronary guidewire for perforation of the atretic PV with success in 7 of 8 cases (25). In our research, we used the soft end of the PCI CTO wire (Cross-it PCI wire 200 and 300 ATM) rather than the hard end in an attempt to minimize the chance of accidental perforation of RVOT or PA. In another study, the survival rate was 72% with no significant decrease in the degree of tricuspid valve regurgitation and the retrograde approach was used when the antegrade one was difficult (9).

We have conducted some statistical analyses on the data from our case series study involving 28 patients. However, due to the small sample size, these analyses may not be reliable enough to guide clinical decisions. Surgery duration times were not documented in the records of patients.

We found that pulmonary valve perforation, although carrying significant complications for some patients, is actually effective in increasing oxygen saturation and blood flow through the TV, RV, and PA, contributing to the growth of these structures and increasing the possibility of two ventricles development. Mechanical perforation is an excellent first choice compared to radiofrequency and laser methods, which are not widely available in most cardiac centers.

**Conflicts of interests:** None.

**Funding/Supports:** None.

## Acknowledgment

We would like to thank the participating patients who helped us in this study.

## References

1. Nykanen DG. Pulmonary Atresia and Intact Ventricular Septum. In: Allen HD, Shaddy RE, Penny DJ, Feltes TF, Cetta F, editors. *Moss & Adams' Heart Disease in Infants, Children, and Adolescents, Including the Fetus and Young Adult*, 9<sup>th</sup> ed. Philadelphia: Wolters Kluwer; 2016. p. 16.
2. Kotani Y, Kasahara S, Fujii Y, Eitoku T, Baba K, Otsuki S, et al. A staged decompression of right ventricle allows growth of right ventricle and subsequent biventricular repair in patients with pulmonary atresia and intact ventricular septum. *Eur J Cardiothorac Surg*. 2016;50(2):298-303.
3. Ahmadi Z, Moradi M, Abedi B. Effect of Breathing Exercises on Lung Volumes and Fatigue in Chemical Victims. *Iran J War Public Health*. 2016;8(3):127-33. [In Persian]
4. Nikounezhad M, Ghazanfari T, Askari N, Zarnani A, Gohari Moghaddam K, Mirafsharieh A. CXCL10 Gene Expression in the Lung Tissue of Sulfur Mustard-Exposed Patients with Long-Term Pulmonary Complications. *Iran J War Public Health*. 2015;7(1):35-42. [In Persian]
5. Sivakumar K, Mumtaz ZA, Sagar P. Application of Vessel Navigator™ fusion imaging software in a complex transcatheter palliation of Tetralogy of Fallot with pulmonary atresia. *Ann Pediatr Cardiol*. 2022;15(2):187-91.
6. Muneuchi J, Watanabe M, Sugitani Y, Doi H, Furuta T, Kobayashi M, et al. Long-Term Outcomes After an Individualized Strategy in Patients with Pulmonary Atresia and Intact Ventricular Septum. *Pediatr Cardiol*. 2022;43(2):435-42.
7. Salehi Omran M, Vafaei H, Salehi Omran H. Evaluation of Echocardiography Results after Severe Mitral Valve Regurgitation Repair Surgery. *J Babol Univ Med Sci*. 2018;20(3):59-63. [In Persian]
8. El Shedoudy S, El-Doklah E. Transcatheter perforation of atretic pulmonary valve by the stiff end of a coronary wire in neonates with pulmonary atresia with intact ventricular septum: A solution in developing countries. *J Saudi Heart Assoc*. 2018;30(3):222-32.
9. Alcibar-Villa J, Rubio A, Peña N, Galdeano JM, Luis M, Arriola J, et al. Atresia pulmonar con septo íntegro. Perforación y valvuloplastia pulmonar mediante técnica mecánica modificada. Seguimiento a medio plazo [Pulmonary atresia with intact ventricular septum. Perforation and pulmonary valvuloplasty using a modified mechanical technique. Medium-term follow-up]. *Rev Esp Cardiol*. 2007;60(8):833-40.
10. Prakoso R, Putra BE, Kurniawati Y, Siagian SN, Lelya O, Sembiring AA, et al. A retrograde approach for transcatheter valvotomy procedure in infants with pulmonary atresia intact ventricular septum (PA-IVS): retrograde versus antegrade approach. *Cardiol Young*. 2023;33(4):608-12.
11. AL-Ammouri I, Nimer A, Naser S, Yousef R, Abu Hani M, Abu Fadaleh M, et al. Outcome of Membranous Pulmonary Valve Atresia with Intact Ventricular Septum Treated by Cardiac Catheterization in a Developing Country. *Cardiol Vasc Res*. 2023;7(1):1-6.
12. Awori MN, Mehta NP, Mitema FO, Kebba N. Optimal Z-Score Use in Surgical Decision-Making in Pulmonary Atresia With Intact Ventricular Septum. *World J Pediatr Congenit Heart Surg*. 2017;8(3):385-8.
13. Chikkabyrappa SM, Loomba RS, Tretter JT. Pulmonary Atresia with an Intact Ventricular Septum: Preoperative Physiology, Imaging, and Management. *Semin Cardiothorac Vasc Anesth*. 2018;22(3):245-55.
14. Pakravan A, Bamdadian T, Akbari P, Alimirzaei A, Samiei A, Babaei Hatkehlouei M, et al. Evaluation of the effects of anticoagulant drugs on the rate of bleeding of oral surgeries and warfarin alternatives. *Int J Med Invest*. 2017;7(1):1-6.
15. Zheng J, Gao B, Zhu Z, Shi G, Xu Z, Liu J, et al. Surgical results for pulmonary atresia with intact ventricular septum: a single-centre 15-year experience and medium-term follow-up. *Eur J Cardiothorac Surg*. 2016;50(6):1083-8.



16. Schneider AW, Blom NA, Bruggemans EF, Hazekamp MG. More than 25 years of experience in managing pulmonary atresia with intact ventricular septum. *Ann Thorac Surg.* 2014;98(5):1680-6.
17. Rathgeber S, Auld B, Duncombe S, Hosking MC, Harris KC. Outcomes of Radiofrequency Perforation for Pulmonary Atresia and Intact Ventricular Septum: A Single-Centre Experience. *Pediatr Cardiol.* 2017;38(1):170-5.
18. El Saiedi SA, Attia WA, Abd El-Aziz OM, Lotfy WN, Abd El-Rahim AM, Hassanein H, et al. A perforation procedure for pulmonary atresia with intact ventricular septum : Egyptian experience and adaptations. *Herz.* 2018;43(7):633-41.
19. Lefort B, Saint-Etienne C, Soulé N, Ma I, Dion F, Chantepie A. Perforation of the atretic pulmonary valve using chronic total occlusion (CTO) wire and coronary microcatheter. *Congenit Heart Dis.* 2019;14(5):814-8.
20. Benson LN, Nykanen D, Collison A. Radiofrequency perforation in the treatment of congenital heart disease. *Catheter Cardiovasc Interv.* 2002;56(1):72-82.
21. Redington AN, Cullen S, Rigby ML. Laser or radiofrequency pulmonary valvotomy in neonates with pulmonary atresia and intact ventricular septum—description of a new method avoiding arterial catheterization. *Cardiol Young.* 1992;2(4):387-90.
22. Bakhru S, Marathe S, Saxena M, Verma S, Saileela R, Dash TK, et al. Transcatheter pulmonary valve perforation using chronic total occlusion wire in pulmonary atresia with intact ventricular septum. *Ann Pediatr Cardiol.* 2017;10(1):5-10.
23. Çelebi A, Yalçın Y, Erdem A, Zeybek C, Polat TB, Akdeniz C. Transcatheter treatment of three patients with pulmonary atresia and intact ventricular septum using different techniques. *Turk Kardiyol Dern Ars.* 2006;34(7):432-8. Available from: <https://archivestsc.com/jvi.aspx?un=TKDA-46320&volume=34&issue=7>
24. Latson LA. Nonsurgical treatment of a neonate with pulmonary atresia and intact ventricular septum by transcatheter puncture and balloon dilation of the atretic valve membrane. *Am J Cardiol.* 1991;68(2):277-9.
25. Alwi M, Budi RR, Mood MC, Leong MC, Samion H. Pulmonary atresia with intact septum: the use of Conquest Pro coronary guidewire for perforation of atretic valve and subsequent interventions. *Cardiol Young.* 2013;23(2):197-202.