









## A Case Report of Coexistence of Cryptococcal Meningitis and COVID-19 in a Patient with Human Immunodeficiency Virus

A. Firouzjahi (MD)<sup>1</sup> , M. Ranaee (MD)<sup>1</sup> , H. Naghshineh (MD)<sup>1</sup> , Z. Ahmadnia (MSc)<sup>1</sup> ,  
S. Rouhi (PhD)<sup>1</sup> , M. Baziboron (MD)<sup>2</sup> , M. J. Nasr (MD)<sup>3</sup> , A. Alizadeh Khatir (MD)<sup>\*4</sup> 

1. Clinical Research Development Unit of Rouhani Hospital, Babol University of Medical Sciences, Babol, I.R.Iran.

2. Infectious Diseases and Tropical Medicine Research Center, Health Research Institute, Babol University of Medical Sciences, Babol, I.R.Iran.

3. Student Research Committee, Babol University of Medical Sciences, Babol, I.R.Iran.

4. Mobility Impairment Research Center, Health Research Institute, Babol University of Medical Sciences, Babol, I.R.Iran.

Article Type	ABSTRACT
Case Report	<p><b>Background and Objective:</b> People who are infected with Human Immunodeficiency Viruses (HIV) are more prone to opportunistic fungal infections than other patients. The immune system of these patients becomes weaker when they are also infected with Coronavirus disease (COVID-19). Involvement of the central nervous system caused by fungal infections in these patients is of concern and fatal if diagnosed late. The aim of this research is to investigate a woman with COVID-19 and HIV who was diagnosed with cryptococcal meningitis.</p> <p><b>Case Report:</b> The patient is a 53-year-old woman who complained of severe headache and nausea after infection with COVID-19. White blood cells, erythrocyte sedimentation rate, lymphocyte, creatinine, aspartate aminotransferase, alanine aminotransferase and blood urea nitrogen were increased compared to the standard level. Cerebrospinal fluid testing showed that glucose was lower and protein was higher than normal. Microscopic examination, staining and culture of cerebrospinal fluid deposits showed the presence of double wall yeasts similar to Cryptococcus. The patient was positive for COVID-19 and HIV. The level of CD4 (cluster of differentiation 4) was lower than the standard. The patient was treated with amphotericin B at a dose of 100 mg for two weeks and was discharged from the hospital after the conditions were stabilized.</p> <p><b>Conclusion:</b> Cryptococcal meningitis can often occur in immunosuppressive conditions such as HIV. Therefore, quick follow-up, diagnosis and treatment should be considered in these patients.</p> <p><b>Keywords:</b> <i>Cryptococcal Meningitis, Cryptococcus, COVID-19, Human Immunodeficiency Virus.</i></p>

Received:

Jul 3<sup>rd</sup> 2022

Revised:

Sep 24<sup>th</sup> 2022

Accepted:

Oct 30<sup>th</sup> 2022

**Cite this article:** Firouzjahi A, Ranaee M, Naghshineh H, Ahmadnia Z, Rouhi S, Baziboron M, et al. A Case Report of Coexistence of Cryptococcal Meningitis and COVID-19 in a Patient with Human Immunodeficiency Virus. *Journal of Babol University of Medical Sciences*. 2023; 25(1): 264-71.



© The Author(S).

Publisher: Babol University of Medical Sciences

\*Corresponding Author: A. Alizadeh Khatir (MD)

Address: Mobility Impairment Research Center, Health Research Institute, Babol University of Medical Sciences, Babol, I.R.Iran.

Tel: +98 (11) 32238301. E-mail: alizade.ali83@yahoo.com

## Introduction

Patients with Coronavirus disease (COVID-19) are susceptible to opportunistic fungal infections (1, 2). The prevalence of co-infection with COVID-19 and fungal infections has been reported in different studies as 5-5.8% and in some others up to 26.3% (3-5). *Cryptococcus* enters the lung through inhalation and its most common clinical form is meningitis (6,7). The results of a study by Ramezanzadeh et al. showed that in the analysis of the cerebrospinal fluid of a patient recovered from COVID-19, *Cryptococcus neoformans* infection was observed (8). In a study by da Rocha et al., cryptococcal meningitis was introduced in a patient recovered from COVID-19 (9). Choi reported a case of pulmonary cryptococcosis in a patient recovered from COVID-19 (10). In a study conducted by Sierpień et al., the coexistence of COVID-19 and infection with *Cryptococcus neoformans* was reported in a patient with Human Immunodeficiency Virus (HIV) (11).

Patients with HIV disease face life-threatening conditions due to difficult access to hospitals during the epidemic, as well as delay in identifying HIV disease or other co-morbidities. The difficult management of this disease, during the time of limited access to the hospital, is a serious challenge for the treatment of patients with HIV who refer late. Therefore, early and timely diagnosis of HIV is necessary to start early treatment and prevent further progression of the disease. Protection and follow-up of patients with HIV due to weak immune system is important, especially during the COVID-19 epidemic (12, 13). The aim of this research is to present the history of an HIV positive patient who was simultaneously infected with COVID-19 and cryptococcal meningitis.

## Case Report

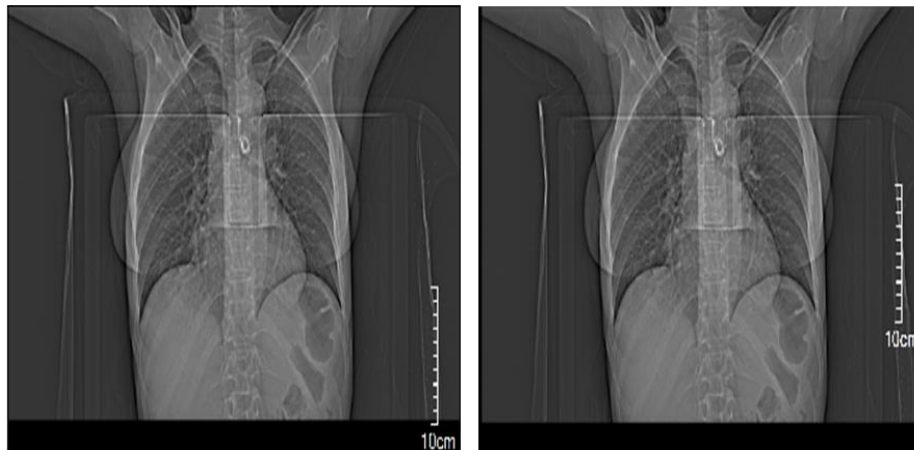This case was approved by the Ethics Committee of Babol University of Medical Sciences with code IR.MUBABOL.HRI.REC.1401.079. The patient is a 53-year-old married woman living in Babol, northern Iran. Clinical symptoms and the reason for the patient to visit the family physician were complaining of severe tension headache (the headache was not throbbing and the severe tension caused by the headache was felt all around the patient's head), the pain was generalized (headache occurred in both cerebral hemispheres) and it was continuous and was accompanied with nausea. After the examination, the family physician referred the patient to a neurologist in the hospital. In addition to headache and nausea, the clinical and visual symptoms seen by the emergency specialist were photophobia with blurred vision. Drug and food poisoning were not diagnosed in the patient. Therefore, the patient was hospitalized and treated for 21 days after the diagnosis of an emergency department doctor. The mentioned patient had been admitted to another medical center six months before coming to this hospital due to fever, chills, mild headache and shortness of breath. During the hospitalization period in the neurology department, the patient had completely lost the ability to speak and see. Severe headache, confusion, drowsiness and decreased consciousness without going into coma, unwanted and aimless movements and self-harm were observed in the patient. During the course of the disease, white blood cells decreased from 30,000 cells/ $\mu$ l (6 months before referral) to 8,200 cells/ $\mu$ l and finally increased to 14,700 cells/ $\mu$ l which was above the standard level. Erythrocyte sedimentation rate, lymphocyte level, creatinine, aspartate aminotransferase, alanine aminotransferase and blood urea nitrogen increased compared to the standard level. A decrease in hemoglobin, neutrophils, mean level of red blood cells and platelets was visible compared to the standard level (Table 1).

**Table 1. The results of the patient's tests six months before the visit and during the visit and diagnosis**

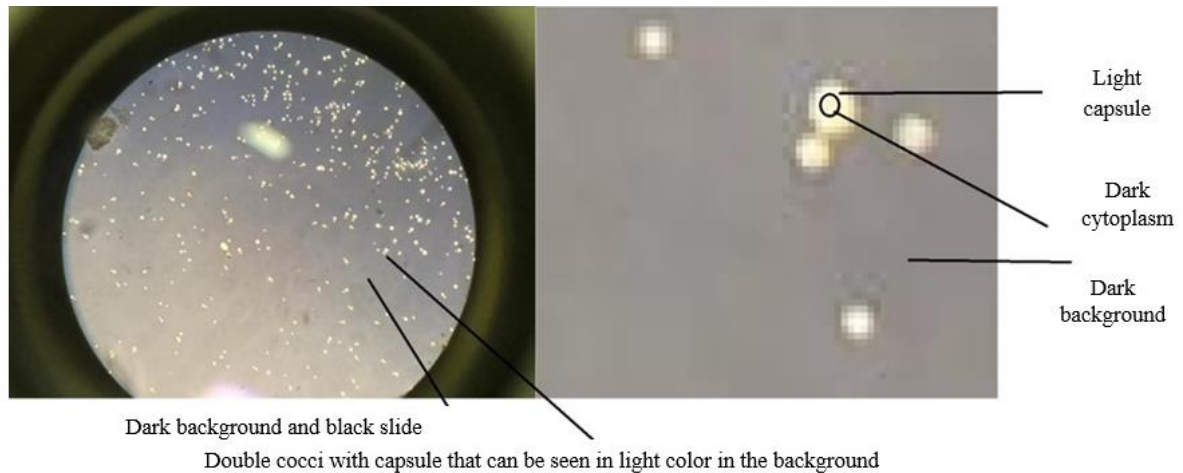
Test	Six months before referral	2 months after referral	4 months after referral	Standard
White blood cells (cells/ $\mu$ L)*	30000	8200	14700	4000-10500
Hemoglobin (g/dL)*	9.6	3.62	9.4	11.6-15
Erythrocyte Sedimentation Rate (mm/hr)*	80	85	-	0-20
Lymphocyte (cells/ $\mu$ L)*	60%	60%	-	20-40%
Neutrophils (cells/ $\mu$ L)*	40%	40%	-	50-70%
Platelets (cells/ $\mu$ L)*	-	349000	160000	150000-450000
Activated protein C (mg/dL)*	-	15	15	<6 negative, >6 positive
Creatinine (mg/dL)*	-	1.1	2.9	0.1-6.3
Mean red blood cell volume (g/dL)*	-	78.5	2.3	79-98
Aspartate aminotransferase (U/L)*	-	23	47	<31
Alanine Aminotransferase (U/L)*	-	21	59	<31
Sodium (mEq/L)*	-	129	134	131-146
Potassium (mEq/L)*	-	4.5	4.2	3.6-5.1
Blood urea nitrogen (mg/dL)*	-	76	71	8-23

\*Cells per microliter (cells/ $\mu$ L), Grams per deciliter (g/dL), Millimeters per hour (mm/hr), Cluster of Differentiation 4 (CD4), Milligrams per deciliter (mg/dL), Units per liter (U/L), Milliequivalents per liter (mEq/L)


In the electrocardiogram of the patient's heart, axis deviation to the right and complete left bundle branch block flow were observed. The results of computed tomography of the chest showed ground-glass opacity in both sides of the lung (Figure 1). In computed tomography of the brain, a calcified pilar cyst was seen in the subcutaneous tissue in the left posterior occipital. According to neurological clinical symptoms, examination of cerebrospinal fluid was done for the possibility of microbial and neurological diseases. The results of the cerebrospinal fluid test showed that the glucose level was 15 mg/dL (lower than the standard limit of 50-80 mg/dL) and the protein level was 240 g/dL (higher than the standard limit of >50 g/dL). This in turn indicated infections or inflammatory processes in the cerebrospinal fluid. Microscopic examination of cerebrospinal fluid sediment showed the presence of double wall yeasts similar to Cryptococcus. In order to confirm the presence of this yeast, staining was done using India ink stain (Kimia Teb Gostar, Iran). Cryptococcus was seen in the form of single, double or multiple cocci with the appearance of bright particles in the dark background. Between the dark cytoplasm of the yeast and the dark background of India ink stain, there was a light capsule of the yeast (14-16) (Figure 2). Cerebrospinal fluid sample was cultured based on fungal culture on a slide containing Sabouraud Chloramphenicol Dextrose Agar culture medium (CONDA, Spain) and placed at a temperature of 37 °C (8, 14). Colonies growing within 2 days were creamy, clear, phlegmatic and with consistency (Figure 3). Urea test of yeast sample was positive and germ tube test was negative (15-17). The performed tests diagnosed cryptococcal meningitis in the patient.



**Figure 1. Chest computed tomography results and ground glass opacity view in the lung**



**Figure 2. Microscopic view of Cryptococcus yeast by Indian ink staining method and light capsule on a dark slide background (microscope lens power: 40X).**



**Figure 3. Fungal culture on slide, containing Sabouraud Chloramphenicol Dextrose Agar culture medium and Cryptococcus growth (swab was placed instead of U-shaped tube. The wet cotton was placed in the plate to provide moisture).**

The diagnosis of COVID-19 was performed using a nasopharyngeal swab sample (B gene ribonucleic acid extraction kit, Iran) and by real-time polymerase chain reaction (real-time PCR) method (COVITECH PCR kit, Iran) and it was diagnosed as positive. Color Doppler sonography of the temporal artery showed a standard condition in the artery. Hepatitis C (Pishtazteb Antibody Diagnostic Kit, Iran) and HIV (Pishtazteb Antigen/Antibody Diagnostic Kit, Iran) test were performed by enzyme-linked immunosorbent assay method. Hepatitis C was negative and HIV was positive in the patient. The patient did not know that she was infected with HIV, and she was tested for HIV and was referred to measure the level of CD4 (cluster of differentiation 4) for the first time. At the time of HIV infection, the CD4 level was 138 cells/ $\mu$ L (lower than the standard  $>200$  cells/ $\mu$ L). Medications prescribed to the patient include amphotericin B (100 mg, every 24 hours for 14 days), flucytosine (500 mg, every 6 hours for 14 days), fluconazole (800 mg, every 24 hours for 14 days), vancomycin (1000 mg, every 6-8 hours for 10 days) with acyclovir (800 mg, every 6 hours for 5 days), cotrimoxazole (400 mg sulfamethoxazole/80 mg trimethoprim, two tablets every 12 hours for 10 day), Apotel (1 g Apotel in 100 ml of normal saline solution, every 6 hours for the period considered by the doctor during hospitalization), dexamethasone (0.75 to 9 mg, every 6 hours or 12 hours for the period considered by the doctor during hospitalization), pethidine (50 mg/ml, every 3 to 4 hours depending on the intensity of pain), Depakene (200 mg, every 24 hours for the period considered by the doctor during hospitalization and after that), ondansetron (8 mg, every 8 hours for 1 to 2 days), aspirin (80 mg, every 4 hours or 6 hours for the period considered by the doctor during hospitalization and thereafter), atorvastatin (20 mg, every 24 hours for the period considered by the doctor during hospitalization and after that), pantoprazole (40 mg, every 24 hours for 28 days) and lorazepam (2 mg, every 24 hours for the period considered by the doctor during hospitalization and after that). Finally, the patient was discharged from the hospital after her conditions became stable.

## Discussion

In this study, the cerebrospinal fluid was positive for the presence of *Cryptococcus*. The patient was treated with the diagnosis of cryptococcal meningitis and then with COVID-19. After that, the patient was diagnosed as HIV positive. Invasive fungi are widely distributed in nature and cause allergies, surface contamination and invasive infections (18-20). Soares et al. showed that infection with COVID-19 is associated with severe headache, fatigue, and pain in the head/neck region (21). Keyhanian et al. also reported that COVID-19 infection is associated with neuromuscular-skeletal manifestations and photophobia. Neuro-immunological mechanisms underlie the involvement of the nervous system and skeletal muscles (22). There are different evidences of fungal and COVID-19 co-infection based on anatomical localization such as rhinocerebral, pulmonary, skin, digestive, diffuse and miscellaneous (23, 24).

Zhang et al. reported that 7.69% of patients with COVID-19 simultaneously developed a secondary fungal infection. Patients with critical conditions, underlying diseases and weakened immune system who receive invasive mechanical ventilation and endovascular devices are at higher risk and mortality (25). White et al. also showed that of 135 patients with COVID-19, 14.1% of patients had *Aspergillus* and 12.6% had other yeast infections. The mortality rate after using antifungal treatment was 38.5%, compared to 90% of patients who did not receive antifungal treatment. Concomitant fungal infection with respiratory viral infections can be easily treated if accurate and early diagnostic criteria are implemented. In our study, the patient recovered and was discharged from the hospital in a stable condition due to prompt diagnosis and appropriate treatment (26).



Immunosuppressive drugs as part of treatment for COVID-19 (such as tocilizumab or corticosteroids) increase the risk of developing opportunistic infections. Alegre-González et al. presented a case of a patient with concurrent cryptococcal pneumonia with COVID-19. But unlike our study, the patient did not have immunosuppressive disease and their patient died. Cryptococcus can colonize the respiratory tract in immunocompromised individuals without causing disease. Unlike the patient examined in our study, this patient did not have any neurological symptoms. This phenomenon was probably due to the high degree of immunosuppression in the HIV positive patient in our study (27). Karnik et al. also reported a case of a patient with disseminated *Cryptococcus neoformans* infection with meningoencephalitis in a patient with severe COVID-19 under long-term glucocorticoid administration (28). It is common to prescribe amphotericin and fluconazole to treat these patients. In our study, the patient was treated with amphotericin and fluconazole. Nevertheless, the treatment management protocol also depends on the immune status of the host, the severity of the infection, and the presence of extrapulmonary involvement and is different in different patients (7).

Mehta et al. reported 11 cases of COVID-19 among 291 HIV positive patients. In infected people, the mean number of lymphocytes was  $10^3 \times 0.3$  cells/ $\mu\text{L}$ . The mean CD4 before COVID-19 was 298 cells/ $\mu\text{L}$ , but at admission, it decreased to less than 200 cells/ $\mu\text{L}$  (29). In the present study, CD4 was 138 c/ $\mu\text{l}$  and the level of lymphocytes was 60% c/ $\mu\text{l}$ . Therefore, the delay in definitive diagnosis, lack of appropriate and timely treatment, and the presence of various underlying diseases can be the cause of a weak immune system and mortality in these patients (29). In the present study, a patient with HIV who was suffering from cryptococcal meningitis and COVID-19 was treated and was discharged from the hospital after her condition stabilized and improved. Fighting with cryptococcal meningitis can be possible in its early stages. Prompt diagnosis and regular monitoring of immunocompromised patients can prevent fungal infection.

Cryptococcal meningitis often occurs in immunosuppressive conditions such as HIV infection. Since this patient had no complaints of clinical symptoms that could help diagnose HIV infection before the onset of COVID-19, more studies are needed to investigate the relationship between COVID-19, cryptococcal meningitis, and immunosuppressive conditions in HIV positive patients.

**Conflict of interest:** The authors declare that there is no conflict of interest.

## Acknowledgment

We would like to express our gratitude to the Vice-Chancellor of Research and Technology of Babol University of Medical Sciences, as well as to Mrs. Maryam Porteqi, Nafiseh Noorallahpoor, and Roya Azizinejad, for their sincere cooperation in the advancement of this research.

## References

- 1.Mirzaei R, Mahdavi F, Badrzadeh F, Hosseini-Fard SR, Heidary M, Jeda AS, et al. The emerging role of microRNAs in the severe acute respiratory syndrome coronavirus 2 (SARS-CoV-2) infections. *Int Immunopharmacol.* 2021;90:107204.
- 2.Tarhini H, Recoing A, Bridier-Nahmias A, Rahi M, Lambert C, Martres P, et al. Long-term severe acute respiratory syndrome coronavirus 2 (SARS-CoV-2) infectiousness among three immunocompromised patients: from prolonged viral shedding to SARS-CoV-2 superinfection. *J Infect Dis.* 2021;223(9):1522-7.
- 3.Chen N, Zhou M, Dong X, Qu J, Gong F, Han Y, et al. Epidemiological and clinical characteristics of 99 cases of 2019 novel coronavirus pneumonia in Wuhan, China: a descriptive study. *Lancet.* 2020;395(10223):507-13.
- 4.Yang X, Yu Y, Xu J, Shu H, Xia J, Liu H, et al. Clinical course and outcomes of critically ill patients with SARS-CoV-2 pneumonia in Wuhan, China: a single-centered, retrospective, observational study. *Lancet Respir Med.* 2020;8(5):475-81.
- 5.Koehler P, Cornely OA, Bottiger BW, Dusse F, Eichenauer DA, Fuchs F, et al. COVID-19 associated pulmonary aspergillosis. *Mycoses.* 2020;63(6):528-34.
- 6.Song G, Liang G, Liu W. Fungal co-infections associated with global COVID-19 pandemic: a clinical and diagnostic perspective from China. *Mycopathologia.* 2020;185(4):599-606.
- 7.Sharma S, Agrawal G, Das S. COVID-19-associated pulmonary Cryptococcosis: a rare case presentation. *Indian J Crit Care Med.* 2022;26(1):129-32.
- 8.Ramezanzadeh E, Nikfarjam S. A case report of *Cryptococcus neoformans* meningitis after recovery from COVID-19 infection in a kidney transplant recipient patient. *Yafte.* 2022; 23(5):80-6. [In Persian]
- 9.da Rocha e Silva TG, dos Santos TS, de Souza EC, do Espírito Santo EF. Cryptococcal meningitis in post-covid 19 patient in the city of Manaus: case report. *S Fl J Dev.* 2022;3(1):47-54.
- 10.Choi HS. Pulmonary cryptococcosis after recovery from COVID-19 in an immunocompetent patient: a rare case report. *Medicine (Baltimore).* 2022;101(32):e30143.
- 11.Sierpień M, Sobstyl A, Sergiel N, Górska D, Stempkowska-Rejek J, Tomaszewicz K. Delayed HIV diagnosis of patients due to COVID-19 pandemic. *J Pre-Clin Clin Res.* 2022;16(2):42-4.
- 12.Brugnarò P, Morelli E, Cattelan F, Petrucci A, Colombo F, Caputo S, et al. The serious threat of late presenters HIV-infected patients in the context of the COVID-19 pandemic. *Infez Med.* 2022;30(1):119-23.
- 13.Collins LF. Persons with human immunodeficiency virus and the coronavirus disease 2019 pandemic: a viral synergy of biology and sociology. *Clin Infect Dis.* 2021;73(7):e2106-8.
- 14.Bava J, Solari R, Isla G, Troncoso A. Atypical forms of *Cryptococcus neoformans* in CSF of an AIDS patient. *J Infect Dev Ctries.* 2008;2(5):403-5.
- 15.McHugh KE, Gersey M, Rhoads DD, Procop GW, Zhang Y, Booth CN, et al. Sensitivity of cerebrospinal fluid cytology for the diagnosis of Cryptococcal infections: a 21-year single-institution retrospective review. *Am J Clin Pathol.* 2019;151(2):198-204.
- 16.Carroll KC, Butel JS, Morse SA, Mietzner T. Jawetz, Melnick, and Adelberg's Medical Microbiology, 27<sup>th</sup> ed. McGraw Hill; 2015. p. 687-9.

- 17.Zono B, Moutschen M, Situakibanza H, Sacheli R, Muendele G, Kabututu P, et al. Comparison of clinical and biological characteristics of HIV-infected patients presenting *Cryptococcus neoformans* versus *C. curvatus*/*C. laurentii* meningitis. *BMC Infect Dis.* 2021;21(1):1157.
- 18.Zeng Z, Ma Y, Zeng H, Huang P, Liu W, Jiang M, et al. Simple nomogram based on initial laboratory data for predicting the probability of ICU transfer of COVID-19 patients: multicenter retrospective study. *J Med Virol.* 2021;93(1):434-40.
- 19.Bandalizadeh Z, Seyedmousavi M, Melchers WJ, Fami Zaghrami M, Mostaed Rostami AA, Shokohi T. *Cryptococcus* and *Cryptococcosis*: updates on pathogenesis, diagnosis and treatment strategies for HIV infected patients. *J Mazandaran Univ Med Sci.* 2018;28(163):144-72. [In Persian]
- 20.Hedayati MT, Khodavaisy S, Aliali M. A review on invasive aspergillosis in patients admitted to intensive care unit with emphasis on diagnostic methods. *J Mazandaran Univ Med Sci.* 2010;19(74):99-112. [In Persian]
- 21.Soaes FH, Kubota GT, Fernandes AM, Hojo B, Couras C, Costa BV, et al. Prevalence and characteristics of new-onset pain in COVID-19 survivors, a controlled study. *Eur J Pain.* 2021;25(6):1342-54.
- 22.Keyhanian K, Umerton RP, Mohit B, Davoudi V, Hajighasemi F, Ghasemi M. SARS-CoV-2 and nervous system: from pathogenesis to clinical manifestation. *J Neuroimmunol.* 2020;350:577436.
- 23.Ezeokoli OT, Gcilitshana O, Pohl CH. Risk factors for fungal co-infections in critically ill COVID-19 patients, with a focus on immunosuppressants. *J Fungi (Basel).* 2021;7(7):545.
- 24.Park H, Bhagat H, Messer W, Maier M. Case report: non-human immunodeficiency virus nontransplant disseminated *Cryptococcosis* in severe COVID-19. *Infect Dis Clin Pract.* 2022;30(2):e1119.
- 25.Zhang H, Zhang Y, Wu J, Li Y, Zhou X, Li X, et al. Risks and features of secondary infections in severe and critical ill COVID-19 patients. *Emerg Microbes Infect.* 2020;9(1):1958-64.
- 26.White PL, Dhillon R, Cordey A, Hughes H, Faggian F, Soni S, et al. A national strategy to diagnose coronavirus disease 2019-associated invasive fungal disease in the intensive care unit. *Clin Infect Dis.* 2021;73(7):e1634-44.
- 27.Alegre-González D, Herrera S, Bernal J, Soriano A, Bodro M. Disseminated *Cryptococcus neoformans* infection associated to COVID-19. *Med Mycol Case Rep.* 2021;34:35-7.
- 28.Karnik K, Wu Y, Ruddy S, Quijano-Rondan B, Urban C, Turett G, et al. Fatal case of disseminated cryptococcal infection and meningoencephalitis in the setting of prolonged glucocorticoid use in a COVID-19 positive patient. *IDCases.* 2022;27:e01380.
- 29.Mehta SA, Rana MM, Motter JD, Small CB, Pereira MR, Stosor V, et al. Incidence and outcomes of COVID-19 in kidney and liver transplant recipients with HIV: report from the national HOPE in action consortium. *Transplantation.* 2021;105(1): 216-24.