










Effect of Aqueous Extract of *Pleurotus Tuber-Regium* on Ethanol Induced Peptic Ulcer in Male Wistar Rats

A. C. Onuegbu (MSc)¹ , C. C. Nworgu (MSc)^{*1} , D. C. Ikwuka (PhD)² , D. B. Adeniyi (MSc)¹ ,
O. K. Okafor (MBBS)¹ , J. U. Uzoigwe (MSc)¹ , M. Nweke (PhD)¹ , Z. N. Uzoigwe (MBBS)³ ,
D. Nwachukwu (PhD)¹ 

1. Department of Physiology, College of Medicine, University of Nigeria Enugu Campus, Enugu, Nigeria.

2. Department of Physiology, School of Medicine & Pharmacy, College of Medicine & Health Sciences, University of Rwanda, Kigali, Rwanda.

3. Department of Internal Medicine, University of Nigeria Teaching Hospital, Ituku-Ozalla, Enugu, Nigeria.

Article Type	ABSTRACT
Research Paper	<p>Background and Objective: There is increasing desire for pleiotropic plant-based remedies for the treatment of peptic ulcer disease due to its prevalence and the challenges associated with existing therapies. This research was conducted to investigate the effect of aqueous extract of <i>Pleurotus tuber-regium</i> (PT) on ethanol induced peptic ulcer in male Wistar rats.</p> <p>Methods: This animal experiment used 30 male Wistar rats. They were divided into five groups (6 rats each) namely: Normal control (Group A), Ulcer control (Group B), Ulcer+omeprazole treatment (Group C), PT pre-treatment ulcer (Group D), and Ulcer+PT treatment (Group E). Peptic ulcer was induced by administration of 1 ml of 80% ethanol orally to each animal from group B to E. Four hours after the induction of gastric ulcer, the rats were sacrificed, the abdomen was opened to remove the stomach for histological study and gastric content to determine the gastric juice volume (ml/4 h). Data were analyzed using IBM SPSS Version 25.</p> <p>Findings: Treatment of ulcer with PT in group E and omeprazole (group C) significantly decreased the free acidity (E=0.83±0.20, C=1.20±0.11, p<0.05), total acidity (E=3.10±0.60, C=9.10±0.32, p<0.05) and ulcer index (E=5.00±2.02, 7.83±4.04, p<0.05) in comparison with group B (free acidity=3.06±1.09, total acidity=22.86±2.51 and ulcer index=32.83±1.74) and group D (free acidity=4.16±0.69, total acidity=17.06±1.91 and ulcer index=35.66±1.96). Group E showed higher percentage of ulcer inhibition (84.77%) than group C (76.15%), while group D showed no inhibition. Also, there were improvements in the macroscopic and microscopic structure of the stomach tissue.</p> <p>Conclusion: The results of this study showed that <i>P. tuber-regium</i> extract could serve as a better alternative to standard anti-ulcer drugs and considering that it is nutraceutical, it is a safe and more affordable alternative for the treatment of peptic ulcer.</p> <p>Keywords: <i>Peptic Ulcer, Pleurotus Tuber-Regium, Ethanol, Total Acidity, Ulcer Index.</i></p>
Received: Jun 19 th 2022	
Revised: Sep 3 rd 2022	
Accepted: Oct 16 th 2022	

Cite this article: Onuegbu AC, Nworgu CC, Ikwuka DC, Adeniyi DB, Okafor OK, Uzoigwe JU, et al. Effect of Aqueous Extract of *Pleurotus Tuber-Regium* on Ethanol Induced Peptic Ulcer in Male Wistar Rats. *Journal of Babol University of Medical Sciences*. 2023; 25(1): 36-45.



© The Author(S).

Publisher: Babol University of Medical Sciences

*Corresponding Author: C. C. Nworgu (MSc)

Address: Department of Physiology, College of Medicine, University of Nigeria Enugu Campus, Enugu, Nigeria.

Tel: +234 (907) 3501053. E-mail: nworgucc@gmail.com

Introduction

Peptic ulcer disease (PUD) is a prevalent disease of the gastrointestinal tract (GIT), and globally affects about 4 million people annually and accounts for about 5-10% mortality worldwide (1-3). Clinically, PUD is averred as the damage to the mucosal lining of the GIT appearing as sores of at least 0.5cm diameter in endoscopic evaluation (4). Numerous factors/damaging agents such as acid, pepsin, bile acids, food ingredients, alcohol addiction, long-term use of non-steroidal anti-inflammatory drugs (NSAIDs), substance abuse, smoking, radiation therapy and Helicobacter pylori (H. pylori) infection have been associated with the pathogenesis and exacerbation of peptic ulcer (5-7). Ulcerations or sores occur when stomach acids damage the lining of the GIT stirred by the instability between causative agents (i.e. H. pylori, free radicals, pepsin and acid) and the protective lining of the mucosa (i.e. mucus, bicarbonate and prostaglandins) factors in stomach (5, 8).

The treatment and management of PUD is centered on repression of acid secretion via proton-pump inhibitors (PPIs), H₂-receptor antagonists, and anti-muscarinic agents, along with acid independent therapy which is brought about by antibiotics against H. pylori. Although effective in reducing PUD mortality, these drugs are expensive and could trigger some adverse effects such as hematopoietic changes, arrhythmia and hypersensitivity, consequently affecting their usefulness and dependence. Hence, the need to find new drugs having pleiotropic effects cannot be overemphasized and plant-based remedies have been ascribed to provide us with diverse means of healing (9).

Edible mushroom have been identified to be rich in essential nutrients such as carbohydrates, protein, vitamins, minerals, fats, fibers and contain pharmacologically active agents (10, 11). Edible mushrooms have been identified and used as important feed additives for healthy living and certain diseases prevention and treatment (12). Many Pleurotus species are identified to have therapeutic properties and have been used for such purposes (12), and it has also been reported that herbs with potent antiapoptotic, antioxidant, anti-inflammatory properties may provide alimentary tract protection (13). Pleurotus tuber-regium (PT) also known as 'tiger milk mushrooms or sclerotia producing mushroom' is a tropical edible mushroom found in Nigeria that produces the underground tuber or edible sclerotium and also mushroom above ground (14). Importantly, they have been shown to have antitumor properties attributable to their polysaccharides, antioxidant, antigenotoxic, bio-antimutagenic activities, anti-inflammatory activity, antilipidemic, antihypertensive, antihyperglycemic activities, antibacterial and antifungal activities (14, 15). Information on the ethnomedicinal use of P. tuber-regium shows it has been used locally in treatment of children malnutrition, stomachache, stomach ulcer, constipation, fever, cold and headache (16, 17).

In spite of advances made in therapeutic management of Peptic ulcer disease (PUD), its prevalence, morbidity and mortality are still high and taking into consideration the reported antioxidant, anti-inflammatory and antiapoptotic properties of PT plus the desire to have natural and less toxic alternative anti-ulcer therapy, necessitated this study to screen the anti-ulcer activities of PT in peptic ulcer induced male Wistar rats. Hence, the present study was conducted with the aim of evaluating the anti-ulcer activities of aqueous extract of Pleurotus tuber-regium (PT) on ethanol induced peptic ulcer in male Wistar rats.

Methods

Study Design: This study adopted an animal experiment design.

Extraction procedure: Fresh wild Pleurotus tuber-regium (PT) was collected from a forest behind the University of Nigeria Nsukka by a taxonomist with the Department of Plant Science and Biotechnology of the University. The extraction was done according to the method of Ojo et al. Samples of PT were cut and ground into powder using a blender (18). 100 g of the powdered sample was boiled in 1 L of distilled water for 30 minutes and filtered using Whatman filter paper. The filtrate was evaporated to complete dryness, forming a chocolate color solid residue of PT which was preserved in air and water proof vessel and kept in a refrigerator, from which fresh preparations were made whenever required. Stock concentration; 1g of prepared PT dissolved in 10ml of water to get aqueous solution of PT. 1 g=1000 mg; 1000 mg/10 ml. Stock solution=100 mg/ml.

Experimental Animals and Grouping: Thirty male Wistar rats weighting 150-180 g were bought from the animal house of University of Nigeria, Nsukka. The animals were housed in standard polypropylene cages, had access to food and water *ad libitum* and kept to acclimatize for 14 days under standard laboratory conditions before the commencement of the study. The Wistar rats were pseudo-randomly distributed into five groups of six rats per group. Group A) normal control, Group B) negative control (ulcer was induced without treatment), Group C) ulcer was induced and standard ulcer treatment drug omeprazole was given, Group D) received a pretreatment (Preventive) dose of 500 mg/kg of P. tuber-regium extract for 14 days before the induction of ulcer, Group E) ulcer was induced and then extract of P. tuber-regium was administered for 21 days (Curative) at a dose of 500 mg/kg.

Ethical Approval: The experimental protocol was performed according to the guidelines of the Committee for Animal Care and Use of University of Nigeria and the study protocol was approved by the Research and Ethics Committee, College of Medicine, University of Nigeria Enugu Campus (Protocol Code Number: 070/010/2020).

Experimental Procedure: Gastric ulcer was induced using the method of Okewumi and Oyeyemi (19). Briefly, the rats were fasted for 48 hours with access to water; 1 ml of 80% ethanol was given via oral gavage to each animal from group 2-5. Four hours following the induction of gastric ulcer, they were euthanized; the abdomen of each animal was dissected to isolate the stomach and gastric content for determination of the gastric juice volume (ml/4h) using a measuring cylinder.

The outcome measures such as acidity, severity index, gastric content and ulcer inhibition were evaluated for ulcer judgment and antiulcer action of PT. 5 ml of distilled water was added to the gastric juice and the issuing solution was centrifuged at 3,000 rpm for 10 min. Determination of gastric acidity in meq/l was done in the supernatant volume using 0.0025 N of sodium hydroxide (NaOH) to titrate it to pH 7 (19). Ulceration severity was graded in consonance with the scale by Kunchandy et al., which is a modification of score: 0: Gray colored stomach-Normal, 0.5: Pink to red stomach coloration, 1: Spot ulcer, 1.5: Hemorrhagic streak, 2: Ulcers number less than 5, 3: Ulcers numbers more than or equal to 5, 4: Ulcer with bleeding, 5: Gastric/duodenal wall Perforation (20). Ulcer Index was calculated by addition of the total number of ulcers and ulcer severity.

Ulcer inhibition percentage was calculated as follows:

$$\text{Ulcer inhibition (\%)} = \frac{(\text{Mean ulcer index of control} - \text{Mean ulcer index of test}) \times 100}{\text{Mean ulcer index of control}}$$

The stomach was harvested and fixed in 10% saline for histological examination. The tissue was processed in the histology laboratory and the slides were viewed with the aid of light microscope. The LD₅₀ was found to be greater than 5000 mg/kg (10).

Histological Analysis: The harvested stomachs were fixed in 10% formaldehyde, were dehydrated and cleared using paraffin and xylene. The tissues were then cut into slices of 4-5 mm and stained using hematoxylin and eosin (H & E) stains and examined with a light microscope (21).

Statistical Analysis: Data were expressed as Mean±Standard error of mean (Mean±SEM) and statistically evaluated using analysis of variance (ANOVA) followed by a post-hoc test using IBM SPSS software version 25. A value of $p < 0.05$ was considered statistically significant.

Results

A significant increase in free acidity, total acidity and ulcer index were detected in untreated rats with ethanol-induced ulcer in contrast to the normal rats (1.83 ± 0.44 , 5.16 ± 0.72 and 0.00 ± 0.00 , respectively). However, treatment with *P. tuber-regium* (Curative Group E) and omeprazole (Group C) significantly decreased the free acidity ($E = 0.83 \pm 0.20$, $C = 1.20 \pm 0.11$ at $p < 0.05$ respectively), total acidity ($E = 3.10 \pm 0.60$, $C = 9.10 \pm 0.32$ at $p < 0.05$, respectively) and ulcer index ($E = 5.00 \pm 2.02$, 7.83 ± 4.04 at $p < 0.05$, respectively) in comparison with non-treatment ethanol-induced ulcer group B (free acidity= 3.06 ± 1.09 , total acidity= 22.86 ± 2.51 and ulcer index= 32.83 ± 1.74 , respectively) and preventive PT group D pretreatment (free acidity= 4.16 ± 0.69 , total acidity= 17.06 ± 1.91 and ulcer index= 35.66 ± 1.96 respectively). It was also observed (Table 1) that post-treatment with PT for 21 days (Group E= 84.77%) showed a higher inhibition percentage of ulcer/ulcer healing index than omeprazole post-treatment (Group C= 76.15%). There were however no significant differences in gastric volume across the groups.

Table 1. Effect of Aqueous Extract of Pleurotus tuber-regium on Ethanol-Induced Peptic Ulcer in Male Wistar Rats

Groups	Gastric volume (ml)	Free Acidity (mEq/L)	Total Acidity (mEq/L)	Ulcer Index (mm)	% Inhibition (Healing Index)
A	4.8 ± 0.20	1.83 ± 0.44	5.16 ± 0.72^{bd}	0.00 ± 0.00^{bd}	100
B	4.0 ± 0.00	3.06 ± 1.09^{ace}	22.86 ± 2.51^{ace}	32.83 ± 1.74^{ace}	-
C	4.93 ± 0.66	1.20 ± 0.11^{bd}	9.10 ± 0.32^{bd}	7.83 ± 4.04^{bd}	76.15
D	4.86 ± 1.33	4.16 ± 0.69^{ace}	17.06 ± 1.91^{ace}	35.66 ± 1.96^{ace}	-
E	4.86 ± 1.33	0.83 ± 0.20^{bd}	3.10 ± 0.60^{bd}	5.00 ± 2.02^{bd}	84.77

Values are expressed as mean±standard error of mean $p < 0.05$. ^a $p < 0.05$ when compared with group A, ^b $p < 0.05$ when compared with group B, ^c $p < 0.05$ when compared with group C, ^d $p < 0.05$ when compared with D, ^e $p < 0.05$ when compared with group E.

A= control group, B= Ulcer group (Ethanol), C= Ulcer+Omeprazole group, D= Extract+Ulcer 500 mg/kg group (pretreatment: Preventive), E= Ulcer+Extract 500mg/kg group (post-treatment: Curative).

Macroscopic Findings: The macroscopic examination of the stomach of the control group rats (Group A) showed a robust pink color gastric mucosa with no gastric lesion (Fig 1A). The ethanol induced gastric ulcer group without treatment (Group B) showed tissue reactions manifested as submucosa hemorrhage (Fig 1B).

The omeprazole treated group (Group C) showed a healthy pink color gastric mucosa with no gastric lesion (Fig 1C). The 500mg/kg *P. tuber-regium* extract pretreatment group (Group D) exhibited submucosa thickening and hemorrhage (Fig 1D). The 500 mg/kg *P. tuber-regium* extract posttreatment group (Group E) showed no gastric lesion, the mucosa color was normal and no thickening and hemorrhage of gastric mucosa was observed (Fig 1E).

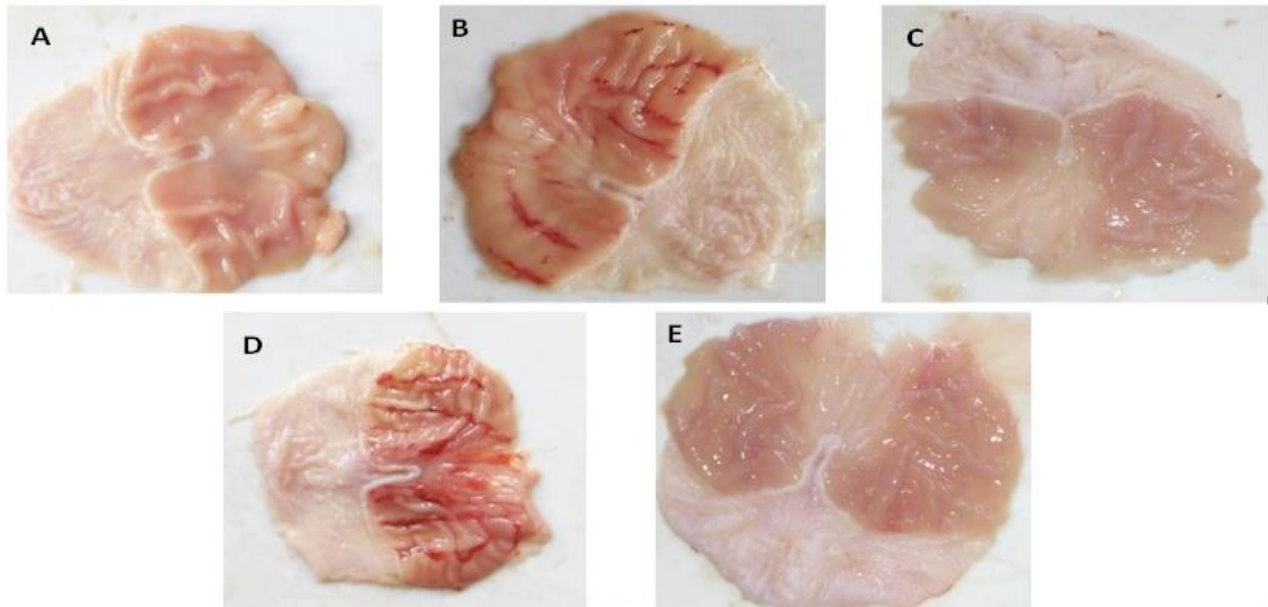


Figure 1. Photograph of Wistar rats stomach showing protective effect of *P. tuber-regium* extract on the ethanol induced gastric ulceration in rats (groups A to E). A is normal control-showing no gastric lesion, B is ulcer was induced without treatment-showing gastric lesion, C: ulcer was induced and omeprazole treatment-showing no gastric lesion, D: given pretreatment dose of 500 mg/kg of *P. tuber-regium* extract for 14 days before the induction of ulcer-gastric lesion present, E: ulcer was induced and 500 mg/kg *P. tuber-regium* extract treatment for 21 days-shows no gastric lesion.

Microscopic/Histopathological Findings: The control group rats did not show any signs of pathological changes or deterioration and there were no signs of hemorrhage and congestion (Fig 2A). The ethanol induced gastric ulcer rats without treatment (Group B) exhibited moderate to severe ulcerated area within the epithelium and submucosa, inter villus hemorrhage and severe inflammatory exudate (SIE) within the submucosa (Fig 2B). The omeprazole treated rats (Group C) showed mild healing with moderate focal ulcerated area (MFUA) within the epithelium and submucosa (Fig 2C). The 500 mg/kg *P. tuber-regium* extract pretreatment rats (Group D) exhibited MFUA within the epithelium & SIE within the submucosa (Fig 2D). The 500 mg/kg *P. tuber-regium* extract post-treatment rats (Group E) showed moderate healing with mild inflammatory exudate (MIE) within the submucosa (Fig 2E).

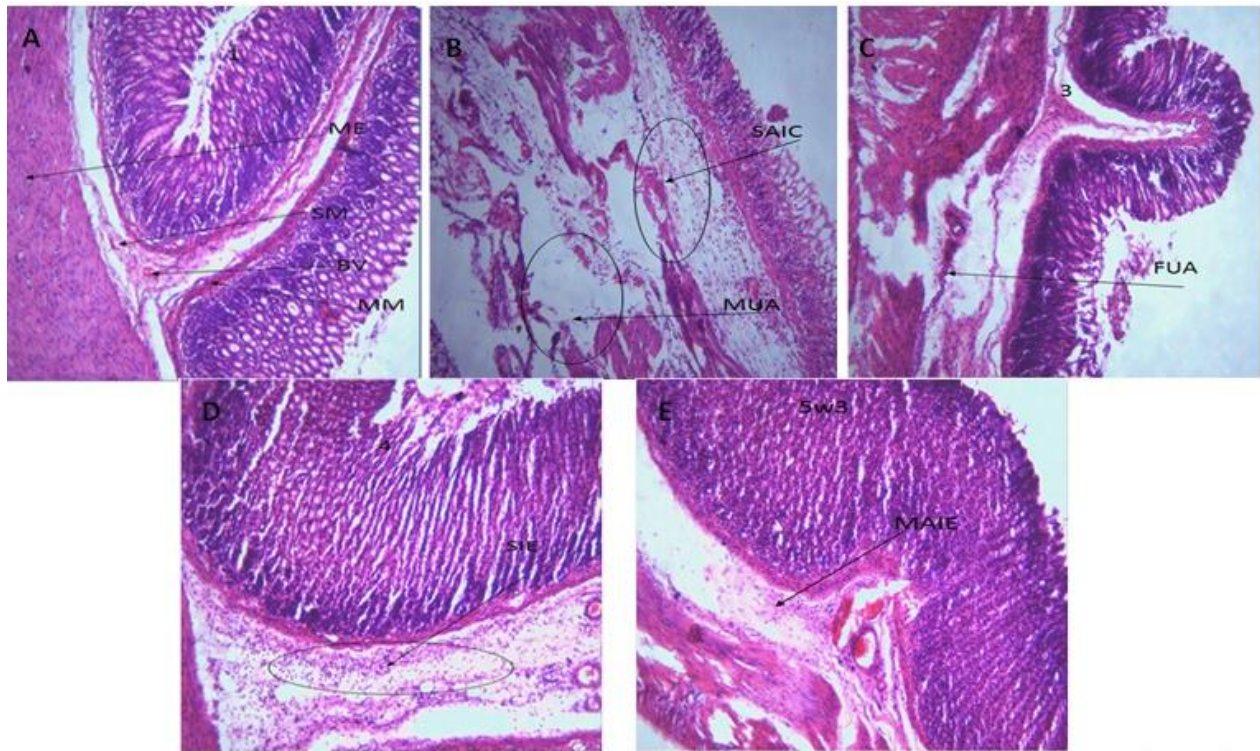


Figure 2. Photomicrograph of Wistar rats stomach tissues showing protective effect of *P. tuber-regium* extract against the ethanol induced gastric ulceration in rats. Histological tissue sections were stained with H&E stains ($\times 150$) (Groups A to E). Groups A- Showing normal muscularis externa (ME), Mucosa (M), gastric pit (GP), muscularis mucosa (MM), Submucosa (SM) and blood vessel (BV); Groups B- Showing moderate to severe ulcerated area within the epithelium and SM & severe inflammatory exudate (SIE) within the SM; Groups C- Showing mild healing with moderate focal ulcerated area (MFUA) within the epithelium and SM; Groups D- Showing MFUA within the epithelium and SIE within the SM; Groups E- Showing moderate healing with mild inflammatory exudate (MIE) within the SM.

Discussion

This study has for the first time demonstrated the therapeutic effect of *Pleurotus tuber-regium* in attenuating ethanol-induced peptic ulcer in male Wistar rats. In this study, 80% ethanol-induced gastric ulcer was confirmed as there was significant increase in total acidity of group B when compared with control group A. Ethanol-induced stomach ulcer has been a popular animal model and one of the most widely used experimental models in testing the efficacy of novel anti-ulcer drugs (22, 23), and it has advantage over other ulcer models as its features resemble many features seen in acute human peptic ulcer prognosis (24, 25). The risk of ulcer in humans is often heightened by alcohol consumption as alcohol increases lipid peroxidation and oxidative stress by the generation of reactive oxygen species (ROS) and oxidative stress perform a vital role in peptic ulcer disease (7, 26). Ethanol administration induces gastric wounds or injuries through dehydration which disrupts stomach mucosal barrier and cytotoxicity by altering the mucosal defense system and eliciting inflammatory response that may cause necrosis and also apoptosis of gastric

mucosal cells with significant generation of ROS (7, 13, 27). It has been reported that ROS are involved in the development of acute and chronic ulceration and scavenging these ROS could be vital in healing these ulcers (28).

The findings of the study recorded a significant decrease in total acidity and ulcer index for the standard drug treatment group and *P. tuber-regium* curative effect group in comparison with the ethanol-induced ulcer untreated group. The *P. tuber-regium* curative group even showed a higher percentage of healing index in comparison with that of the standard drug treatment. The photomicrograph of the stomach section for standard drug treatment group showed mild healing with moderate focal ulcerated area and moderate healing with mild inflammatory exudates within the mucosa was observed in *P. tuber-regium* curative group. This significant effect and remarkable reduction in total acidity and ulcer index may be attributed to the potent properties of *P. tuber-regium* especially its phenolic compounds as it has been reported to reduce lipid profile levels, attenuate lipid peroxidation and revive antioxidant activity (29). Lin et al. noted that the antioxidant and antiangiogenic activities of *P. tuber-regium* extract is attributed to natural phenolic constituents such as syringic, chlorogenic, protocatechuic, ferulic and folic acid (30). Studies had also reported that phenolic compounds contained in *P. tuber-regium* are amongst cytoprotective ingredients involved in healing ulcer (22, 31-33). Also, the high polysaccharides derived from *P. tuber-regium* have been implicated to have anti-hyperglycemic, anti-hyperlipidemic and antioxidant properties which may also contribute to its therapeutic effect in decreasing oxidative stress and lipid profile (12, 29).

Phytonutrients have been found to positively affect/promote several health conditions. Phytonutrients found in the sclerotium of *P. tuber-regium* promote the function of the immune system, act directly against bacteria and viruses reduce inflammation and it is associated with the treatment and prevention of ulcer (28, 29). Notably, flavonoids are active water soluble antioxidants and free radical scavengers which inhibit oxidative stress to cells and have antiulcer activity (33, 34). They also have anti-inflammatory properties that could inhibit gastric mucosal lesion; and it has also been posited to be very important plant constituent with significant antiulcer activity. Saponins and tannins have also been ascribed to having antiulcer activities (34).

Despite the curative activity of *P. tuber-regium* extract when used after ulcer induction, the preventive treatment group which was treated with 500 mg/kg body weight of the extract for two weeks prior to induction of ulcer recorded a negative ulcer inhibition percentage and had significantly high acidity and ulcer index. This implies that the mushroom did not offer significant protective effect against ulcer after two weeks of the administration; this may be due to instant sacrifice following ulcer induction and that not enough time for ulcer healing was allowed.

In summary, our findings identify that the use of *P. tuber-regium* extract following ulcer induction in rats decreases total acidity, ulcer index and showed a higher percentage healing index than the standard drug. The macroscopic and microscopic photograph of tissues extracted from rats treated with *P. tuber-regium* extract following ulcer induction also showed better improvement. This implies that *P. tuber-regium* extract used as treatment after ulcer induction showed better promise in ameliorating ulcer than antiulcer standard drug omeprazole.

In conclusion, the results of this study indicated that *P. tuber-regium* extract decreased total acidity, decreased ulcer index, showed a higher percentage of healing than omeprazole and showed better macroscopic and microscopic improvement of tissue following ethanol-induced ulcer in rats. Therefore, this study stands as an important contribution in discovering that *P. tuber-regium* extract could serve as a better

alternative to standard anti-ulcer drugs. In addition, considering that it is a natural occurring alternative, it is evident that it may not pose significant toxic effects to the human body. In addition, due to its availability and ease of cultivation, it is also a more affordable alternative to the conventional synthetic antiulcer drugs. Therefore, *P. tuber-regium* can be useful as a nutraceutical for the treatment of peptic ulcer and a useful nutritional addition to human or animal diet.

Recommendations: The mushroom *P. tuber-regium* holds nutritional, phytochemical and antimicrobial potentials that should be further investigated. The present research investigated the mushrooms anti-ulcer activity in ethanol induced rats, further investigation can be made as to the anti-helicobacter activity of the mushroom, as the organism is also a causative agent of peptic ulcer. Also, the duration and dose of the preventive treatment could be increased or decreased and investigated to see if the extract has no preventive effect.

Conflicts of interest: The authors declare that no commercial or financial conflict of interest whatsoever exist in the conduct of the research.

Funding Sources Statements: The authors affirm that this study had received no form of financial support.

Acknowledgment

The authors appreciate Mr. Chiamobi Nnabuchi and technical staff of Department of Physiology Laboratory, University of Nigeria Enugu campus for their assistance in conducting experimental sessions.

References

- 1.Sung JJ, Tsoi KK, Ma TK, Yung MY, Lau JY, Chiu PW. Causes of mortality in patients with peptic ulcer bleeding: a prospective cohort study of 10,428 cases. *Am J Gastroenterol.* 2010;105(1):84-9.
- 2.Meena LN, Jain S, Bajjiya P. Gastrointestinal perforation peritonitis in India: A study of 442 cases. *Saudi Surg J.* 2017;5(3):116-21.
- 3.Habeeb A, Tiwari SK, Bardia A, Khan S, Vishwakarma SK, Habeeb S, et al. Peptic Ulcer Disease: Descriptive Epidemiology, Risk Factors, Management and Prevention. In: Khan AA, editor. *Peptic Ulcer Disease*, 1st ed. India: SMGroup; 2016. p. 1-13.
- 4.Zibima SB, Oniso JI, Wasini KB, Ogu JC. Prevalence trends and associated modifiable risk factors of peptic ulcer disease among students in a university community south-south Nigeria. *Int J Health Sci Res.* 2020;10(6):97-105.
- 5.Gadekar R, Singour PK, Chaurasiya PK, Pawar RS, Patil UK. A potential of some medicinal plants as an antiulcer agent. *Pharmacogn Rev.* 2010;4(8):136-46.
- 6.Erin N, Türker S, Elpek Ö, Yildirim B. ADAM proteases involved in inflammation are differentially altered in patients with gastritis or ulcer. *Exp Ther Med.* 2018;15(2):1999-2005.
- 7.Gugliandolo E, Cordaro M, Fusco R, Peritore AF, Siracusa R, Genovese T, et al. Protective effect of snail secretion filtrate against ethanol-induced gastric ulcer in mice. *Sci Rep.* 2021;11(1):3638.
- 8.Pallavi AB, Balaraman R. Effect of activit, a herbomineral formulation, on Experimentally- induced gastric lesions in rats. *J Appl Pharm Sci.* 2011;01(10):134-9.
- 9.Igbokwe GE, Ikwuka DC, Nworgu CC, Uzoigwe JU, Ezeokafor EN, Chilaka UJ, et al. Effect of *vernoniaamygdalina* on haematological indices and kidney function in rats exposed to stress. *Teikyo Med J.* 2021;44(4):1135-42.
- 10.Odunlade AK, Akindele S, Arojojoye OA. The Antioxidant Effects of Mushroom Extracts in Boosting Immune System in Mammals using Albino Rats as a Model. *Adv Life Sci Technol.* 2015;36:57-72.
- 11.Okolo KO, Siminialayi IM, Orisakwe OE. Protective Effects of *Pleurotus tuber-regium* on Carbon-Tetrachloride Induced Testicular Injury in Sprague Dawley Rats. *Front Pharmacol.* 2016;7:480.
- 12.Adeyi AO, Adams FA, Adenipekun CO. *Pleurotus tuber-regium* inclusion in diet ameliorates dyslipidaemia in obese-type 2 diabetic rats. *Clin Phytosci.* 2021;7:84.
- 13.Raish M, Shahid M, Bin Jordan YA, Ansari MA, Alkharfy KM, Ahad A, et al. Gastroprotective Effect of Sinapic Acid on Ethanol- Induced Gastric Ulcers in Rats: Involvement of Nrf2/HO-1 and NF-κB Signaling and Antiapoptotic Role. *Front Pharmacol.* 2021;12:622815.
- 14.Ijeh II, Okwujiako IA, Nwosu PC, Nnodim HI. Phytochemical composition of *Pleurotus tuber regium* and effect of its dietary incorporation on body /organ weights and serum triacylglycerols in albino mice. *J Med Plants Res.* 2009;3(11):939-43.
- 15.Helena SA, Martins A, Queiroz MJ, Ferreira IC. Bioactivity of phenolic acids: metabolites versus parent compounds: a review. *Food Chem.* 2015;173:501-13.
- 16.Oyetayo OV. Medicinal Uses of Mushrooms in Nigeria: Towards Full and Sustainable Exploitation. *Afr J Tradit Complement Altern Med.* 2011;8(3):267-74.
- 17.Chen AW, Huang NL. Production of Tuber-Like Sclerotia of Medicinal Value by *Pleurotus tuberregium* (Fr.) Singer (Agaricomycetidae). *Int J Med Mushrooms.* 2004;6(2):181-8.

- 18.Ojo RJ, Seriki SA, Wang DE, Mhya HJ. Biochemical effect of Aqueous Carica papaya Seed and Leaf Extracts on Serum Biochemistry of Alloxan Induced Diabetic Rats. IOSR J Pharm Biol Sci. 2015;10(1):18-22.
- 19.Okewumi TA, Oyeyemi AW. Gastro-protective activity of aqueous *Carica papaya* seed extract on ethanol induced gastric ulcer in male rats. Afr J Biotechnol. 2012;11(34):8612-5.
- 20.Kunchandy J, Khanna S, Kulkarni SK. Effect of alpha2 agonists clonidine, guanfacine and B-HT 920 on gastric acid secretion and ulcers in rats. Arch Int Pharmacodyn Ther. 1985;275(1):123-38.
- 21.Akhtar MS, Malik A, Arshad H, Batool S, Raza AR, Tabassum T, et al. Protective effect of newly synthesized indole imines against ethanol-induced gastric ulcer in rats. Biotechnol Biotechnol Equip. 2021;35(1):231-7.
- 22.Sistani Karampour N, Arzi A, Rezaie A, Pashmforoosh M, Kordi F. Gastroprotective effect of zingerone on ethanol-induced gastric ulcers in rats. Medicina (Kaunas). 2019;55(3):64.
- 23.Arab HH, Salama SA, Omar HA, Arafa el-SA, Maghrabi IA. Diosmin Protects against Ethanol-Induced Gastric Injury in Rats: Novel Anti-Ulcer Actions. PLoS One. 2015;10(3):e0122417.
- 24.Adinortey MB, Ansah C, Galyuon I, Nyarko A. In Vivo Models Used for Evaluation of Potential Antigastrroduodenal Ulcer Agents. Ulcers. 2013;2013:796405.
- 25.Rahman Z, Dwivedi DK, Jena GB. Ethanol-induced gastric ulcer in rats and intervention of tert-butylhydroquinone: Involvement of Nrf2/HO-1 signalling pathway. Hum Exp Toxicol. 2020;39(4):547-62.
- 26.Yoo JH, Lee JS, Lee YS, Ku S, Lee HJ. Protective effect of bovine milk against HCl and ethanol-induced gastric ulcer in mice. J Dairy Sci. 2018;101(5):3758-70.
- 27.Richard DK, Jauro A, Nvau JB, Dabun LJ. Ethanol-induced gastric ulceration in rats: Protective roles of methanol and water extracts of *Cyathula prostrata* Linn Blume. J Pharmacogn Phytochem. 2017;6(5):1515-7.
- 28.Aziz RS, Siddiqua A, Shahzad M, Shabbir A, Naseem N. Oxyresveratrol ameliorates ethanol-induced gastric ulcer via downregulation of IL-6, TNF- α , NF- κ B, and COX-2 levels, and upregulation of TFF-2 levels. Biomed Pharmacother. 2019;110:554-60.
- 29.Huang HY, Korivi M, Chaing YY, Chien TY, Tsai YC. Pleurotus tuber-regium Polysaccharides Attenuate Hyperglycaemic and Oxidative Stress in Experimental Diabetic Rats. Evid Based Complement Alternat Med. 2012;2012:856381.
- 30.Lin S, Lai TC, Chen L, Kwok HF, Lau CB, Cheung PC. Antioxidant and antiangiogenic properties of phenolic extract from pleurotus tuber-regium. J Agric Food Chem. 2014;62(39):9488-98.
- 31.Sumbul S, Ahmad MA, Mohd A, Mohd A. Role of Phenolic Compounds in Peptic Ulcer: An Overview. J Pharm Bioallied Sci. 2011;3(3):361-7.
- 32.Yahia M, Yahia M, Benhouda A, Benbia S, Khadraoui H. New gastroprotective activity of methanolic extracts of *Hyoscyamus albus* (Solanaceae) and *Umbilicus rupestris* leaves (Crassulaceae) against gastric mucosal injury induced by ethanol in rats. Biotechnol Ind J. 2017;13(1):125.
- 33.Mousa AM, El-Sammad NM, Hassan SK, Madboli AE, Hashim AN, Moustafa ES, et al. Antiulcerogenic effect of *Cuphea ignea* extract against ethanol-induced gastric ulcer in rats. BMC Complement Altern Med. 2019;19(1):345.
- 34.Nwachukwu DC, Okwuosa CN. Investigation of the anti-ulcer activity of chloroform leaf extract of *Aspilia Africana* in rats. Indian J Nov Drug Deliv. 2012;4(1):52-6.