



## Comparison of the Position and View of the Inferior Alveolar Canal and Mental Foramen in Panoramic Radiography and CBCT Images

N. Anbiaee (DDS, MS)<sup>1</sup> , B. Yazdani (DDS, MS)<sup>\*2</sup>

1.Oral and Maxillofacial Diseases Research Center, Mashhad University of Medical Sciences, Mashhad, I.R.Iran.

2.Department of Restorative Dentistry, School of Dentistry, Mashhad University of Medical Sciences, Mashhad, I.R.Iran.

### Article Type

### ABSTRACT

#### Research Paper

**Background and Objective:** Knowing the position of the inferior alveolar canal and mental foramen is very important in periapical surgeries, administration of local anesthesia and implantation. The aim of this study is to compare the position and view of the inferior alveolar canal and mental foramen in panoramic radiography and CBCT images.

**Methods:** In this cross-sectional study, concurrent panoramic radiography and CBCT images of patients who visited a private radiology clinic for one year were examined. In panoramic radiographs, the indices of canal visibility, mental foramen visibility, proximity of mental foramen to mandibular premolar teeth, canal diameter, mental foramen diameter and distance from mental foramen to alveolar crest were examined. Then all these cases were evaluated and compared in CBCT radiographs (as gold standard).

**Findings:** In this study, concurrent CBCT and panoramic radiographs of 41 patients including 23 men (56.1%) and 18 women (43.9%) with a mean age of 51±13 years were analyzed. The mean values of variables of inferior alveolar canal diameter and distance from mental foramen to alveolar crest in panoramic images were significantly higher than CBCT images (p<0.001). The average diameter of mental foramen in panoramic images (3.9±1.3) was lower than CBCT images (4.2±1.3), but the difference was not significant (p=0.074).

**Conclusion:** Based on the results of this study, although panoramic radiography can be used in routine treatments and general examination of the mandible, it is necessary to use the CBCT technique in dental practices that require higher accuracy in terms of measurement.

**Keywords:** *Panoramic Radiography, Cone Beam Computed Tomography, Mental Foramen, Inferior Alveolar Canal.*

#### Received:

Apr 23<sup>rd</sup> 2021

#### Revised:

Nov 16<sup>th</sup> 2021

#### Accepted:

Nov 23<sup>rd</sup> 2021

**Cite this article:** Anbiaee N, Yazdani B. Comparison of the Position and View of the Inferior Alveolar Canal and Mental Foramen in Panoramic Radiography and CBCT Images. *Journal of Babol University of Medical Sciences*. 2022; 24(1): 413-22.



© The Author(S).

Publisher: Babol University of Medical Sciences

\*Corresponding Author: B. Yazdani (DDS, MS)

Address: Department of Restorative Dentistry, School of Dentistry, Mashhad University of Medical Sciences, Mashhad, I.R.Iran.

Tel: +98 (51) 35511852. E-mail: babak.yazdani90@gmail.com

## Introduction

One of the most common side effects of maxillofacial surgery, especially implant surgery, is damage to the lower alveolar canal and nerve as well as mental foramen. Any damage to these anatomical structures during surgery can lead to neuro-sensory disorders in the lower lip area (1-3). To prevent these complications, it is recommended that surgeons be aware of the morphology and topography of the canal and its anatomical changes (2, 4, 5).

Several imaging methods have been introduced to determine the location of the mandibular canal, the most famous of which are panoramic radiography and cone beam computed tomography (CBCT). According to studies, panoramic imaging is used more than CBCT due to its availability and cheapness. However, the reliability of this radiograph is low due to vertical and horizontal magnification as well as overlapping of some anatomical structures of the jaw. On the other hand, CBCT has replaced panoramic radiography because it enables the three-dimensional study of X-ray images. According to these studies, CBCT can be accepted as a standard for examination of the hard tissue of the mouth and jaw (2, 3, 6-8).

In a study aimed at determining the vertical height of the posterior bone in panoramic and CBCT images, Bertram et al. presented evidence of a mistake in calculating the dimensions of the vertical bone available for implants in the posterior regions of the mandible during the evaluation of panoramic radiographs (9). The study of Sakdajeyont et al. also states that it is more difficult to identify anatomical elements in panoramic radiographs and more errors occur in it (10).

Knowing the exact position of the foramen is widely used in the clinic. The location of the foramen clearly shows its importance in administering local anesthesia to the patient for dental surgeries and treatments and implantation by the dentist (3) This study was conducted with the aim of comparing the position and appearance of the inferior alveolar canal and the mental foramen in panoramic and CBCT images to reach a guideline for the prescription of selective radiography in the field of oral surgeries.

## Methods

This cross-sectional study was conducted after being approved by the Ethics Committee of Mashhad University of Medical Sciences with code IR.MUMS.SD.REC.1394.233. In this research, 41 panoramic radiographs and CBCT images were prepared during one day from patients who visited a private radiology clinic within a year. The right and left sides of the patients were examined separately as a sample. Patients who had both panoramic radiographs and CBCT images and had clear images of all areas of the lower jaw were included in the study, and patients who underwent extensive surgery in the mandible area, as well as patients who had extensive skeletal-maxillofacial disorders or their panoramic or CBCT images had low quality were excluded from the study. CBCT technique was considered as standard. According to the American Dental Association (ADA) Council on Scientific Affairs, CBCT should be used as a supplement to standard oral imaging methods (3).

In the panoramic radiographs, the visibility of the canal, the visibility of the mental foramen, the proximity of the mental foramen to the second premolar teeth of the mandible, the diameter of the canal (Figure 1), the diameter of the mental foramen, and the distance from the mental foramen to the alveolar crest were examined. All measurements were performed by an oral and maxillofacial radiologist. After two weeks, all these items were measured in CBCT radiographs. Measurements were performed by Gwyddion software for panoramic radiographs and Romexis software 3.0.3 for CBCT images. For the calibration of the panoramic images, the actual size of the images was entered into the Gwyddion software.

CR Panoramic radiographs were prepared by EC panoramic device manufactured by Planmeca (Finland, 2003) and processed by Agfa CR30 device (2007) with a resolution of 100 pixels. CBCT images were prepared by mid type CBCT device of Planmeca (Finland, 2013) with fov=10×10 and normal resolution. The exposure parameters were adjusted according to the patient's features and the indications for image preparation.

In a room with low to medium light, panoramic images were taken and evaluated with the help of Microsoft Photos 15 software (Microsoft Corporation, Windows 10) on a high-quality 15-inch LED monitor (resolution 1366×768 pixels) by a student and supervised by a relevant expert. The observer was allowed to use the magnification tool and change the brightness of the images. CBCT images were analyzed by Planmeca Romexis Viewer 3/3.0.R software using the same monitor with the same resolution.

In the CBCT images, the coronal section and also the quasi-panoramic view in the Pan tab were used to examine the variables of canal visibility and mental foramen visibility. The variable of mental foramen proximity with the mandibular premolar teeth was investigated in the coronal section with a slice thickness of 0.5 mm. The variables of canal diameter, mental foramen diameter and distance from mental foramen to alveolar crest were also measured in the coronal section with a slice thickness of 0.5 mm and using the Measure length tool.

The visibility of the canal was classified into the following 4 categories:

- A- Visibility of the upper and lower wall as cortical.
- B- Visibility of the lower wall as cortical.
- C- Canal boundary can be seen, but is not cortical.
- D- The canal is not visible.

In addition, the visibility of the mental foramen was classified into 3 categories:

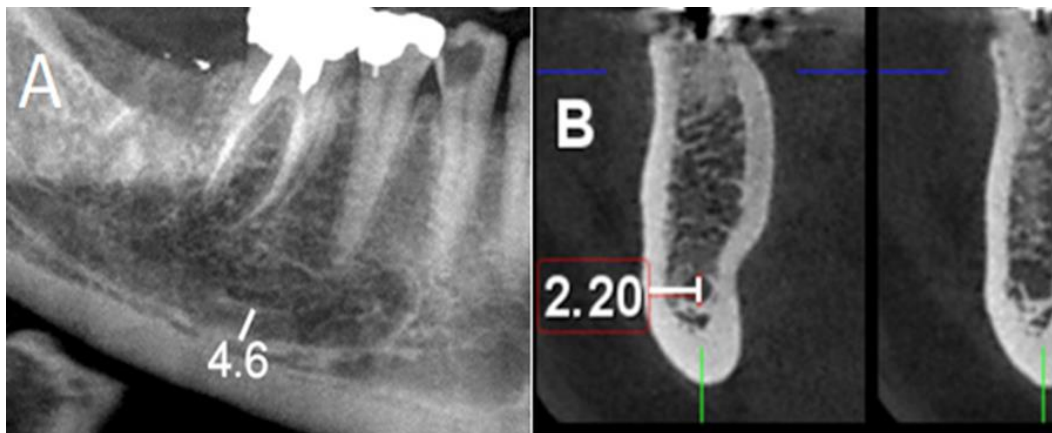
- A- The foramen is seen with cortical borders.
- B- Can be seen, but is not cortical.
- C- Is not visible (Figure 2).

In order to classify the vicinity of the mental foramen to the mandibular premolar teeth, the apex of the teeth was considered relative to foramen boundaries. In terms of the vicinity of the mental foramen to the mandibular premolar teeth, the samples were classified into 4 categories:

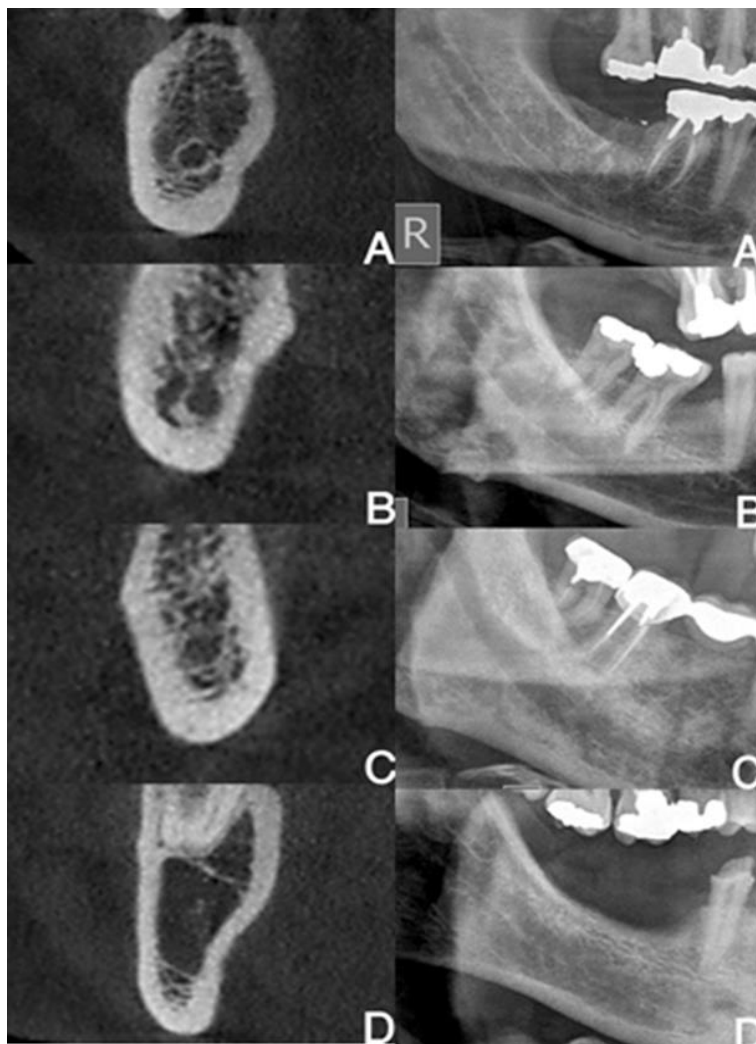
- A- In the vicinity of the first premolar.
- B- Between the first and second premolar.
- C- In the vicinity of the second premolar.
- D- More distal than the second premolar.

In cases where the patient was edentulous in the premolars area, this variable was not investigated. Also, the horizontal distance from the apex of the second premolar to the center of the mental foramen was measured in the coronal section with a slice thickness of 0.2 mm and by counting the number of slices between the apex of the second premolar to the center of the mental foramen and multiplying by 0.2. Positive values were considered more mesial than the apex of the second premolar for the foramen and negative values were considered more distal than the apex of the second premolar for the foramen.

In order to more accurately evaluate the effect of bone density on the visibility of the canal and foramen, the patients were divided into 2 groups based on age: younger than and equal to 50 years and older than 50 years, and the variables were analyzed separately in the 2 groups. In addition, the patients were examined for the presence or absence of teeth in the premolars area. Qualitative and quantitative data were measured using SPSS software version 21 and analyzed by independent t, Wilcoxon and Mann-Whitney tests, and  $p < 0.05$  was considered significant.



**Figure 1.** Examination of the diameter of the inferior alveolar canal. A: panoramic image, B: CBCT image.



**Figure 2.** Comparison of grading of canal visibility in panoramic (right) and CBCT (left) images. A: Visibility of the upper and lower wall as cortical, B: Visibility of the lower wall of the canal as cortical, C: The boundary of the canal is visible but is not cortical, D: The canal is not visible.

## Results

Of the 41 samples examined, 23 were men (56.1%) and 18 were women (43.9%) with a mean age of  $51 \pm 13$  years and an age range of 20 to 85 years. The mean age in men and women was about 50 years, which did not differ significantly from each other. The mean value of variables of canal diameter and distance from mental foramen to alveolar crest in panoramic images were significantly higher than CBCT images ( $p < 0.001$ ). The mean diameter of mental foramen in panoramic images was lower than CBCT images, but the difference was not significant (Table 1).

The panoramic image seems to overstate the diameter of the canal and the distance from the foramen to the crest. In CBCT and panoramic images, the mean value of all quantitative variables (canal diameter ( $p = 0.042$ ), mental foramen diameter ( $p < 0.001$ ), mental foramen to alveolar crest distance ( $p < 0.001$ ), mental canal length ( $p = 0.010$ )) were significantly higher in men compared to women (Table 2).

In comparing age between CBCT and panoramic images, the distance from mental foramen to alveolar crest was significantly higher in people under 50 compared to people over 50 ( $p < 0.001$ ). However, the difference in other variables was not significant (Table 3).

**Table 1. A comparison between quantitative variables of the two imaging techniques**

Variable	Radiography	Number	Mean $\pm$ SD	p-value*
Vertical diameter of the canal	CBCT	53	3.0 $\pm$ 0.7	<0.001
	Panoramic image	53	3.7 $\pm$ 0.8	
Mental foramen diameter	CBCT	68	4.2 $\pm$ 1.3	0.074
	Panoramic image	68	3.9 $\pm$ 1.3	
Distance from mental foramen to alveolar crest	CBCT	69	16.9 $\pm$ 3.5	<0.001
	Panoramic image	69	22.4 $\pm$ 5.5	

\*Wilcoxon test

**Table 2. Comparison of quantitative variables in men and women based on the imaging technique**

Radiography	Variable	Gender	Number	Mean $\pm$ SD	Variation range	p-value*
CBCT	Canal diameter	Man	43	0.7 $\pm$ 3.2	2-5	0.042
		Woman	33	0.6 $\pm$ 2.8	1-4	
	Mental foramen diameter	Man	46	1.4 $\pm$ 4.6	2-8	<0.001
		Woman	36	0.9 $\pm$ 3.4	2-6	
	Distance from mental foramen to alveolar crest	Man	46	3.4 $\pm$ 17.8	12-24	<0.001
		Woman	36	3.7 $\pm$ 15.0	6-20	
The length of the mental canal	Man	46	1.6 $\pm$ 6.7	3-10	0.010	
	Woman	34	1.5 $\pm$ 5.8	2-9		
Panoramic image	Canal diameter	Man	38	0.9 $\pm$ 3.9	2-6	0.121
		Woman	17	0.7 $\pm$ 3.5	3-5	
	Mental foramen diameter	Man	40	1.4 $\pm$ 4.1	2-9	0.094
		Woman	28	1.0 $\pm$ 3.6	2-6	
	Distance from mental foramen to alveolar crest	Man	44	5.4 $\pm$ 23.7	13-35	0.009
		Woman	25	5.0 $\pm$ 20.2	8-29	
The length of the mental canal	Man	33	2.5 $\pm$ 7.5	4-15	0.430	
	Woman	15	3.7 $\pm$ 7.2	3-18		

\*Independent T-test

**Table 3. Comparison of quantitative variables in age classification by type of radiography**

Radiography	Variable	Age	Number	Mean±SD	Variation range	p-value*
CBCT	Canal diameter	50≤	33	0.5±2.9	2-4	0.151
		50>	43	0.8±3.2	1-5	
	Mental foramen diameter	50≤	38	0.9±3.8	2-6	0.106
		50>	44	1.5±4.4	2-8	
	Distance from mental foramen to alveolar crest	50≤	38	2.6±18.0	11-24	0.001
		50>	44	4.2±15.3	6-24	
The length of the mental canal	50≤	36	1.3±6.3	4-9	0.739	
	50>	44	1.8±6.4	2-10		
Panoramic image	Canal diameter	50≤	24	0.8±3.8	3-6	0.419
		50>	31	0.9±3.7	2-6	
	Mental foramen diameter	50≤	32	1.3±3.9	2-9	0.609
		50>	36	1.3±3.8	2-7	
	Distance from mental foramen to alveolar crest	50≤	30	3.9±24.2	18-34	<0.001
		50>	39	6.2±21.0	8-35	
	The length of the mental canal	50≤	22	3.2±7.1	4-18	0.282
		50>	26	2.7±7.7	3-15	

\*Independent T-test

In terms of canal visibility, the degree of agreement between two types of imaging techniques in men and women is in the poor agreement category ( $\kappa=0.96$ ). Regardless of gender, the agreement value of the two imaging types is poor ( $\kappa=0.131$ ). In people under 50 years of age, the amount of agreement is very low ( $\kappa=0.063$ ) and in people over 50 years of age, the amount of agreement is relatively low ( $\kappa=191$ ). That is, in general, the agreement between the two types of imaging is low in terms of canal visibility. In CBCT images, the highest frequency was observed in type B canals and the lowest in type D canals. In panoramic images, the highest frequency was related to type B and the lowest frequency to type C. Also, no accessory mental foramen or bifurcation was found in any of the panoramic and CBCT images.

In terms of visibility of the mental foramen in the CBCT images, the boundaries of the mental foramen were observed in all samples in a clear and cortical manner. In the panoramic images, 8 cases of distinct and cortical boundaries, 62 cases of distinct and non-cortical boundaries, and 12 cases with no visibility were recorded. Therefore, because all CBCT samples were of the same type (type A), the degree of agreement between the two imaging techniques was statistically unmeasurable.

Out of the total of 82 examined samples, in 49 samples, either the mental foramen was not visible in the panoramic view or the sample had no teeth in the premolars area. Therefore, in 33 samples, the proximity of the mental foramen to the apex of the premolar teeth in CBCT and panoramic images was comparable. No accessory mental foramen or bifurcation was found in any of the panoramic and CBCT images.

In CBCT images, the highest frequency of proximity of mental foramen with mandibular premolar teeth is type B and the lowest is type A. In panoramic images, type B is the most frequent and type A and D are the least frequent. Also, the average distance between the apex of the second premolar tooth and the center of the mental foramen was respectively 2.2 and 1.3 mm on the right and left sides in the CBCT images, and 3.7 and 2.6 mm in the panoramic images ( $p=0.002$  and  $p<0.001$ ). It seems that the panoramic image shows the location of the mental foramen more mesially than the CBCT.

## Discussion

In this study, the mean variables of inferior alveolar canal diameter and distance from mental foramen to alveolar crest in panoramic images were significantly higher than CBCT images. The mean diameter of mental foramen in panoramic images was lower than CBCT images, but the difference was not significant. In terms of visibility of the inferior alveolar canal, the overall agreement between the two types of imaging is low.

In the comparison of quantitative variables between CBCT and panoramic, it was concluded that all quantitative variables are lower in women than in men, which is due to the smaller and delicate facial features of women compared to men. However, in panoramic images, no statistically significant difference was observed between the two genders in many cases, which indicates that panoramic images have inherent distortion, which makes quantitative measurements unreliable in this technique. In the study of Muinelo-Lorenzo et al., the diameter of the mental foramen and the distance from the mental foramen to the crest were greater in men than in women in CBCT images (11). Neves et al. concluded in a study that CBCT radiographs are better than panoramic radiographs for detecting anatomical points, but panoramic radiographs can also be used for routine dental practices (6).

In many cases, the lower alveolar canal is not seen in panoramic images, and in this sense, the agreement between the two imaging techniques is very low (12). In general, panoramic images show the cortical boundaries of the canal with less clarity (13). Although in panoramic images, the thickness of the imaging layer is greater than CBCT and it is expected that the cortical boundaries of the canal will be shown more clearly due to the increase in the thickness of the imaging layer and the increase in resolution contrast, but contrary to expectations, the cortical boundaries of the foramen mental and lower alveolar canal are less visible (14). This can be caused by the negative angle of panoramic imaging, which cannot superimpose the cortical bone of the canal walls in this condition, and on the contrary, it causes them to be unclear, and for this reason, the cortical boundaries of the canal are less visible (15). On the other hand, in this research, the highest frequency was related to the cortical nature of the lower wall of the canal in both techniques. This finding means that in terms of anatomical shape, the lower alveolar canal is more in the lower cortical wall, and its other walls do not have cortical boundaries, and for this reason, the lower wall of the canal is depicted more in the panoramic images. In a study by Kamrun et al., visibility of the upper wall of the canal in panoramic radiographs was weak, but in CBCT, this weakness was significantly resolved (7). Angelopoulos et al. also found that CBCT images have better quality in showing mandibular canal structures (16).

In this study, the degree of agreement of mental foramen visibility and its cortical boundaries between panoramic images and CBCT was not statistically comparable, and mental foramen was seen in 100% of CBCT images and in 85.4% of panoramic radiographs. This result was similar to the study of Muinelo-Lorenzo, who observed mental foramen in about 83% of panoramic radiographs (11).

The degree of agreement between the two techniques in showing the proximity of the mental foramen to the premolar teeth was not favorable. In both types of imaging, the most common type was related to the position of the foramen between the first and second premolar teeth, and in none of the CBCT images, the position of the foramen was more mesial than the first premolar tooth and near its apex. In this research, it was concluded that in the panoramic images, the mental foramen is depicted more anterior than the real status. No similar study was found on this topic. However, this could be due to the fact that in the panoramic images, the elements that are located on the buccal-maxillary wall, especially in the anterior part, are more overlapped and come closer to the midline. This situation is caused by the fact that the spherical shape of the face should be depicted linearly and widely in panoramic images. Therefore, a distortion occurs in the buccal and lingual surfaces and the outer shell (buccal surface) approaches the midline.

One of the weaknesses of this study is the small number of samples, so studies with a larger statistical population are recommended. Furthermore, one of the strengths of this study was the comprehensive and detailed examination of the samples and the measurement of the maximum indexes and variables.

The present study shows that panoramic imaging shows the diameter of the inferior alveolar canal and the distance from the mental foramen to the alveolar crest.

On the other hand, it shows the cortical boundaries of the mental foramen and the lower alveolar canal with less clarity and shows the mental foramen more medially than the actual position. Therefore, although panoramic radiography can be used in routine treatments and general examination of the mandible, it is necessary to use the CBCT technique in dental practices that require higher accuracy in terms of measurement.

### **Acknowledgment**

We hereby express our appreciation to the research and technology department of Mashhad University of Medical Sciences as well as the student research committee of the Faculty of Dentistry of that university for their cooperation in conducting this research.



## References

- 1.Von Arx T, Bornstein MM. The bifid mandibular canal in three-dimensional radiography: morphologic and quantitative characteristics. *Swiss Dent J.* 2021;131(1):10-28.
- 2.Shokry SM, Alshaib SA, Al Mohaimeed ZZ, Ghanimah F, Altyebe MM, Alenezi MA, et al. Assessment of the Inferior Alveolar Nerve Canal Course Among Saudis by Cone Beam Computed Tomography (Pilot Study). *J Maxillofac Oral Surg.* 2019;18(3):452-8.
- 3.Pelé A, Berry PA, Evanno C, Jordana F. Evaluation of Mental Foramen with Cone Beam Computed Tomography: A Systematic Review of Literature. *Radiol Res Pract.* 2021;2021:8897275.
- 4.Aljarbou FA, Aldosimani M, Althumairy RI, Alhezam AA, Aldawsari AI. An analysis of the first and second mandibular molar roots proximity to the inferior alveolar canal and cortical plates using cone beam computed tomography among the Saudi population. *Saudi Med J.* 2019;40(2):189-94.
- 5.Safae A, Mirbeigi S, Ezoddini F, Khojastepour L, Navab-Azam A. Buccolingual course of the inferior alveolar canal in different mental foramen locations: A cone beam computed tomography study of an Iranian population. *Int J Appl Basic Med Res.* 2016;6(4):262-6.
- 6.Neves FS, Nascimento MC, Oliveira ML, Almeida SM, Bóscolo FN. Comparative analysis of mandibular anatomical variations between panoramic radiography and cone beam computed tomography. *Oral Maxillofac Surg.* 2014;18(4):419-24.
- 7.Kamrun N, Tetsumura A, Nomura Y, Yamaguchi S, Baba O, Nakamura S, et al. Visualization of the superior and inferior borders of the mandibular canal: a comparative study using digital panoramic radiographs and cross-sectional computed tomography images. *Oral Surg Oral Med Oral Pathol Oral Radiol.* 2013;115(4):550-7.
- 8.Naitoh M, Yoshida K, Nakahara K, Gotoh K, Ariji E. Demonstration of the accessory mental foramen using rotational panoramic radiography compared with cone-beam computed tomography. *Clin Oral Implants Res.* 2011;22(12):1415-9.
- 9.Bertram F, Bertram S, Rudisch A, Emshoff R. Assessment of Location of the Mandibular Canal: Correlation Between Panoramic and Cone Beam Computed Tomography Measurements. *Int J Prosthodont.* 2018;31(2):129-34.
- 10.Sakdajeyont W, Chaiyasamut T, Arayasontiparb R, Wongsirichat N. The mental foramen in panoramic versus cone beam computed tomogram. *Mahidol Dent J.* 2018;38(2):159-67.
- 11.Muinelo-Lorenzo J, Suárez-Quintanilla JA, Fernández-Alonso A, Varela-Mallou J, Suárez-Cunqueiro MM. Anatomical characteristics and visibility of mental foramen and accessory mental foramen: Panoramic radiography vs. cone beam CT. *Med Oral Patol Oral Cir Bucal.* 2015;20(6):e707-e14.
- 12.Imada TS, Fernandes LM, Centurion BS, de Oliveira-Santos C, Honório HM, Rubira-Bullen IR. Accessory mental foramina: prevalence, position and diameter assessed by cone-beam computed tomography and digital panoramic radiographs. *Clin Oral Implants Res.* 2014;25(2):e94-9.
- 13.Kuribayashi A, Watanabe H, Imaizumi A, Tantanapornkul W, Katakami K, Kurabayashi T. Bifid mandibular canals: cone beam computed tomography evaluation. *Dentomaxillofac Radiol.* 2010;39(4):235-9.
- 14.Guo JL, Su L, Zhao JL, Yang L, Lv DL, Li YQ, et al. Location of mental foramen based on soft- and hard-tissue landmarks in a chinese population. *J Craniofac Surg.* 2009;20(6):2235-7.
- 15.Haghanifar S, Rokouei M. Radiographic evaluation of the mental foramen in a selected Iranian population. *Indian J Dent Res.* 2009;20(2):150-2.

16. Angelopoulos C, Thomas SL, Hechler S, Parisis N, Hlavacek M. Comparison between digital panoramic radiography and cone-beam computed tomography for the identification of the mandibular canal as part of presurgical dental implant assessment. *J Oral Maxillofac Surg.* 2008;66(10):2130-5.

[ DOR: 20.1001.1.15614107.1401.24.1.49.5 ]

[ DOI: 10.22088/jbums.24.1.413 ]